

Original Article

Flow cytometric analysis of immunoglobulin heavy chain expression in B-cell lymphoma and reactive lymphoid hyperplasia

David D Grier^{1*}, Samer Z Al-Quran^{*}, Diana M Cardona², Ying Li, Raul C Braylan³

*Department of Pathology, University of Florida, College of Medicine, Gainesville, FL, USA; ¹Current address: Department of Pathology, Wake Forest University School of Medicine, Winston-Salem, NC; ²Current address: Department of Pathology, Duke University Medical Center, Durham, NC; ³Current address: The Hematology Laboratory, NIH/Clinical Center, Bethesda, MD, USA; *Drs. Al-Quran and Grier contributed equally to this work and share first authorship.*

Received December 27, 2011; accepted January 12, 2012; Epub February 12, 2012; Published February 28, 2012

Abstract: The diagnosis of B-cell lymphoma (BCL) is often dependent on the detection of clonal immunoglobulin (Ig) light chain expression. In some BCLs, the determination of clonality based on Ig light chain restriction may be difficult. The aim of our study was to assess the utility of flow cytometric analysis of surface Ig heavy chain (HC) expression in lymphoid tissues in distinguishing lymphoid hyperplasias from BCLs, and also differentiating various BCL subtypes. HC expression on B-cells varied among different types of hyperplasias. In follicular hyperplasia, IgM and IgD expression was high in mantle cells while germinal center cells showed poor HC expression. In other hyperplasias, B cell compartments were blurred but generally showed high IgD and IgM expression. Compared to hyperplasias, BCLs varied in IgM expression. Small lymphocytic lymphomas had lower IgM expression than mantle cell lymphomas. Of importance, IgD expression was significantly lower in BCLs than in hyperplasias, a finding that can be useful in differentiating lymphoma from reactive processes.

Keywords: Flow cytometry, lymphoid tissue, immunoglobulin heavy chains, lymphoma, reactive hyperplasia

Introduction

The assessment of immunoglobulin (Ig) light chains (LC) expression by flow cytometry (FCM) or immunohistochemistry has been used extensively in the study of lymphoid hyperplasias and lymphomas and light chain expression restriction is a critical diagnostic element in the recognition of B-cell lymphoma [1-7]. Assessment of Ig heavy chains (HC) expression has also been utilized in the diagnosis of B-cell non-Hodgkin lymphomas (BCL) [8-13]. However, most studies have been based on immunohistochemistry and molecular techniques involving gene rearrangements of the HC variable regions. The flow cytometric analysis of surface Ig HC expression has not been examined thoroughly in either lymphoid hyperplasias or as a diagnostic tool in BCL [14-18]

In this study, we measured the levels of Ig HC

expression in reactive lymphoid hyperplasias and determined the potential utility of this analysis in the diagnosis and classification of BCL.

Materials and methods

Patients and samples

The records of our Hematopathology Laboratory were searched for specimens of lymph nodes and other lymphoid tissues, including spleen, and soft tissue infiltrates, submitted for routine diagnostic flow cytometric analysis. One hundred and twenty three tissue biopsies and excisions were selected. They included BCL and reactive lymphoid hyperplasias, in which Ig HC flow cytometric analysis was performed. These cases were diagnosed as such based on morphology, immunohistochemistry, FCM, and molecular studies, if required. The lymphomas

Ig heavy chain analysis in lymphoid tissue

Table 1. Reagents used for flow cytometric analysis

Antigen	Fluochrome	Clone	Manufacturer
CD19	PerCP	SJ 25C1	BD
CD20	APC	L27	BD
IgA	FITC	Polyclonal	CAL
IgG	PE	G18-145	Pharm
IgM	FITC	Polyclonal	CAL
IgD	PE	IA6-2	Pharm
Kappa	FITC	Polyclonal	DAKO
Lambda	FITC	Polyclonal	DAKO
IgG Goat isotype control	FITC	Polyclonal	CAL
IgG1 mouse isotype control	PE	X40	BD
IgG2a mouse isotype control	PE	X39	BD
IgG1 mouse isotype control	FITC	X40	BD
IgG2a mouse isotype control	FITC	X39	BD

PerCP: Peridinin-chlorophyll-protein, APC: Protein A Phycoprobe, FITC: Fluorescein isothiocyanate, PE: Phycoprobe R-phycoerythrin BD: Becton Dickinson, San Jose, CA. CAL: Caltag Laboratories, Invetrogen Immunodetection, Carlsbad, CA. Pharm: BD Biosciences Pharmingen, San Jose, CA. DAKO; DakoCytomation, Denmark.

Table 2. Reagent combinations used for flow cytometric analysis.

Tube	FITC	PE	PerCP	APC
1	IgG1 mouse isotype control	IgG2 mouse isotype control	IgG1	IgG1
2	IgG2 mouse isotype control	IgG1 mouse isotype control	IgG1	IgG2
	IgG Goat isotype control	None	Anti-CD19	Anti-CD20
3	Anti-IgA Goat F(ab') ₂ antihuman	Anti-IgG Mouse antihuman	Anti-CD19	Anti-CD20
4	Anti-IgM Goat F(ab') ₂ antihuman	Anti-IgD Mouse antihuman	Anti-CD19	Anti-CD20

FITC: Fluorescein isothiocyanate, PE: Phycoprobe R-phycoerythrin, PerCP: Peridinin-chlorophyll-protein, APC: Protein A Phycoprobe

were classified according to established criteria [19]. The research protocol was approved by the Institutional Review Board.

Flow cytometric immunophenotyping

Lymphoid tissues were received fresh and processed within 24 hours of the biopsy procedure. Cell suspensions were prepared by mincing the tissue with scalpels in RPMI medium supplemented with antibiotics, and filtering through a wire mesh screen (#80 mesh). In hemocontaminated samples, erythrocyte lysing was performed by ammonium chloride treatment. The cells were then washed twice in a PBS solution containing 0.1% NaN₃. After the final wash step, cells were re-suspended in RPMI medium (Mediatech, Inc., Manassas, VA) with 10% bovine serum containing a mixture of antibiotics.

Surface labeling of the cells was performed in albumin (Sigma Chemical Company, Saint Louis,

MO)-precoated wells in Falcon 96-well U-bottom assay plates (BD Labware, Franklin Lakes, NJ). A comprehensive panel of antibodies was used, but for the purposes of this study only those listed in **Table 1** were analyzed. The reagent combinations used are shown in **Table 2**. The reagent mixture was added to each microtiter well. For cell staining, approximately 3×10^5 cells were added to the coated wells containing the diluted fluorochrome-conjugated antibody and incubated for 15 min on ice in the dark. Subsequently, the cells were washed twice with 100 microL of phosphate buffer solution and were centrifuged at 500 g for 5 min and the supernatant was discarded. After the last centrifugation and disposal of supernatant, cells were transferred to microtubes in a final volume of 250 microL of PBS and analyzed on a four color FACScalibur flow cytometer (BD Biosciences [BD], San Jose, CA) equipped with both a 488-nm argon laser and a 635-nm diode laser. Daily calibration of the instrument was per-

formed using standardized CaliBRITE Beads (BD) with FACSComp Software (BD), and compensation was performed using appropriately stained normal peripheral blood samples. The data were acquired using CellQuest software (BD). Data analysis was performed using FSC Express 3 (De Novo Software, Los Angeles, CA).

The expression levels of IgG, IgA, IgM, and IgD were determined on CD20- and CD19- expressing B cells. In the BCL, the neoplastic B cells were identified on the basis of their restricted kappa or lambda Ig LC, or the absence of Ig LC expression [14, 20, 21]. In cases of partial neoplastic involvement, a separate analysis of monoclonal and polyclonal B-cells was performed also based on the Ig LC expression. The Mean Fluorescence Intensity (MFI) for each HC expression in the selected B-cell populations was determined by calculating a ratio between the mean channel fluorescence for the antibody labeled cells (IgA, IgG, IgM, or IgD) and the mean channel fluorescence for the appropriate Ig isotype-matched controls.

Statistical analysis

Statistical analysis was performed using the Mann-Whitney test using GraphPad Prism (GraphPad Software, San Diego, CA).

Results

Sample characteristics

The samples consisted of 60 reactive lymphoid hyperplasias and 63 BCL, which included 13 diffuse large cell lymphomas (LCL), 16 small lymphocytic lymphomas (SLL), 18 follicular lymphomas (FL), 9 mantle cell lymphomas (MCL), 4 marginal zone lymphomas (MZL) and 3 Burkitt lymphomas (BL).

Immunophenotypic features

Reactive hyperplasias: The Ig HC expression in cases of reactive hyperplasia was measured on B cells only. In hyperplastic cases without a dominant follicular component (mixed hyperplasia), the B cells clustered as a single population (**Figure 1A**). In these cases, IgD and IgM expression was uniformly high whereas IgA and IgG expression was low in all samples (**Figure 1B**).

In eighteen (30%) hyperplastic cases, two differ-

ent B-cell subpopulations were distinguished by CD20 expression (**Figure 1C**), a finding that reflects a prominent follicular hyperplasia in histologic sections [22]. The discrimination between these two B-cell populations using CD20 was not always possible using CD19, which was expressed more homogeneously among B-cells and did not allow an adequate resolution of different B-cell types (**Figure 1D**). The less intense CD20(+) cells correspond to the follicular mantle cells [22], which also express variable levels of CD23, dim CD5 and no CD10 (data not shown). On the other hand, the more intense CD20(+) cells that represent germinal center cells [22] are of larger size, as determined by forward light scatter signals (**Figure 1C**), and express variable but clearly detectable CD10 and CD38 (data not shown). In these hyperplastic cases with two discrete B-cell populations, Ig HC expression was analyzed independently on the mantle and germinal center cells using CD20 and CD10 expression as well as cell size as discriminators. The mantle cells showed high expression of IgM and IgD while IgG and IgA expression was much weaker or not detectable on these cells (**Figure 1E**). Although variable, IgD expression on the mantle cells was particularly intense, as clearly demonstrated in **Figure 2** while the Ig HC expression on germinal center cells was relatively low for all Ig classes (**Figure 1F**) and difficult to measure. Thus, for comparison with BCL, the measurements of HC expression in these cases were obtained on the mantle B cells.

B-cell lymphomas: In BCL, the expression of a dominant Ig HC was highly variable, and in some cases there was no detectable Ig HC expression. In general, BCL without detectable LC expression demonstrated lack of HC expression (data not shown); however, three lymphomas with no surface LC expression demonstrated HC expression as shown in the example in **Figure 3**.

Compared with reactive lymphoid hyperplasia, lymphomas of all subtypes had more variable expression of IgM (**Figure 4**). IgM expression was significantly higher in hyperplasias than in SLL ($P < 0.001$) and LCL ($P < 0.003$), although some lymphoma cases in these categories showed equal or even higher expression than most of the hyperplastic samples. There was no significant difference in IgM expression between hyperplasias and other B-cell lymphoma subtypes. When all BCL subtypes were compared,

Ig heavy chain analysis in lymphoid tissue

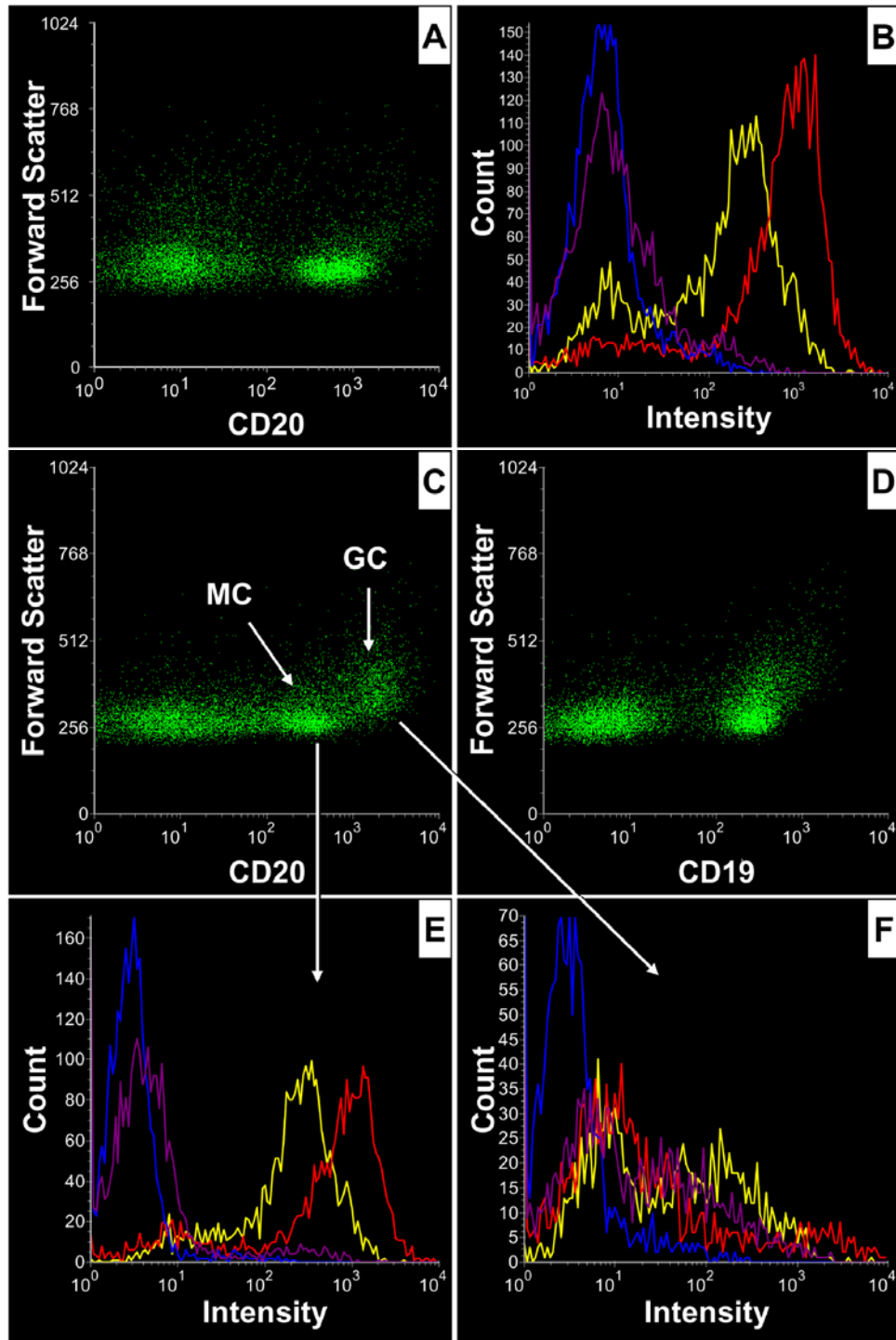


Figure 1. Immunoglobulin heavy chain expression in mixed lymphoid hyperplasia (A, B) and follicular hyperplasia (C-F). In mixed lymphoid hyperplasia, the single population of CD20 (+) B cells (A) shows uniformly high expression of IgM and IgD and very low expression of IgA and IgG (B). In follicular hyperplasia, two distinct populations of mantle cells and germinal center B cells are identified by the combined analysis of CD20 and forward light scatter (C). This separation between the two compartments is lost using CD19 which is expressed more homogeneously on B cells (D). The mantle B cells (MC) exhibit intense expression of IgM and IgD, while IgG and IgA expression is much weaker or not detectable (E). The germinal center cells (GC) show low expression of all immunoglobulin heavy chains (F). (IgA = Blue, IgG = Purple, IgM = Yellow, IgD = Red).

Ig heavy chain analysis in lymphoid tissue

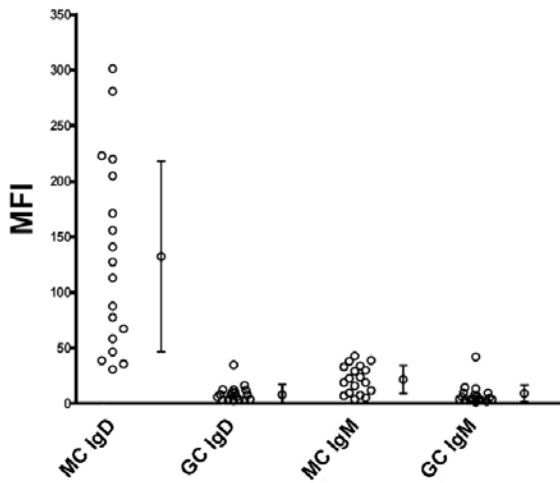


Figure 2. Expression of IgD and IGM by different B cell compartments in follicular lymphoid hyperplasia. IgD expression on the follicular mantle B cells (MC) is more intense than that of germinal center cells (GC), which also show low expression of IgM. (MFI: mean fluorescence intensity).

IgM expression in MCL was higher than in SLL ($p < 0.03$). No significant differences in IgM expression were observed among the other BCL subtypes.

IgD expression on B cells was different in reactive lymphoid tissues compared to BCL of all subtypes. In the majority of cases, the expression of IgD on B cells in reactive lymphoid hyperplasia was significantly more intense than that of BCL (**Figure 5**). The difference in IgD expres-

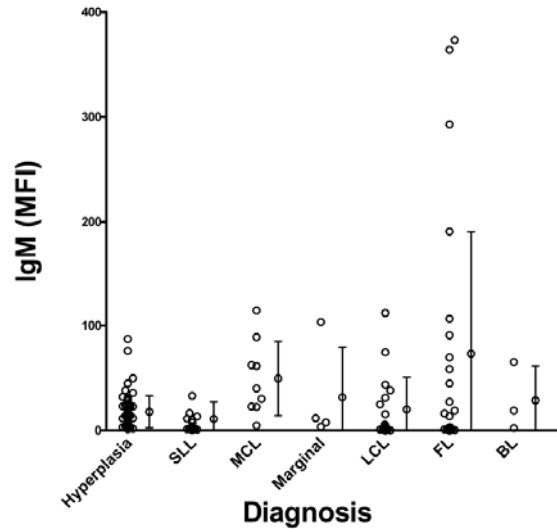


Figure 4. Expression of IgM in hyperplastic lymph nodes and B cell lymphomas (BCL). Compared with reactive lymphoid hyperplasia, BCL of all subtypes generally display more variable expression of IgM. SLL, small lymphocytic lymphoma; MCL, mantle cell lymphoma; LCL, large cell lymphoma; FL, follicular lymphoma; BL, Burkitt lymphoma. MFI: mean fluorescence intensity.

sion among the BCL subtypes was not statistically significant. The differences in the level of IgD and IgM expression by B cells between lymphoid hyperplasia and BCL could also be recognized in most cases by visual inspection of the graphical data. Two representative examples are shown in (**Figure 6**). The correlated analysis

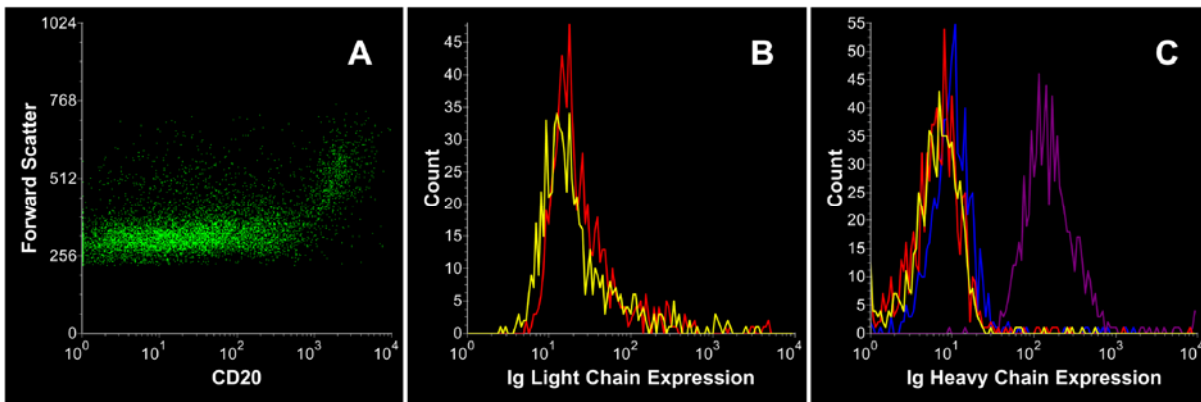


Figure 3. A case of large B cell lymphoma lacking surface light chain expression but demonstrating heavy chain expression. The combined analysis of CD20 and cell size (forward scatter) demonstrates the presence of large B cells with bright CD20 expression (A). These large B cells lack surface immunoglobulin light chains (B; Kappa = red, Lambda = yellow) but express IgG heavy chain (C; IgA = Blue, IgG = Purple, IgM = Yellow, IgD = Red).

Ig heavy chain analysis in lymphoid tissue

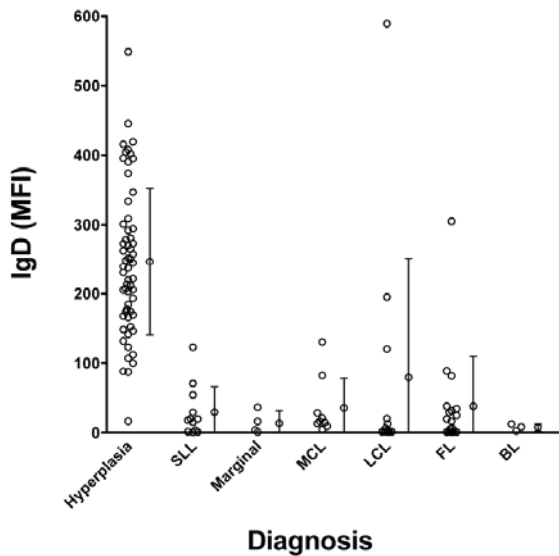


Figure 5. Expression of IgD in hyperplastic lymphoid tissues and B cell lymphomas (BCL). In reactive lymphoid tissues, IgD expression on B cells is significantly more intense than that of BCL of all subtypes. The difference in IgD expression among BCL subtypes was not statistically significant. SLL: small lymphocytic lymphoma; MCL: mantle cell lymphoma; Marginal: marginal zone lymphoma, LCL: large cell lymphoma; FL: follicular lymphoma; BL: Burkitt lymphoma. MFI: mean fluorescence intensity.

of CD20 and IgD expression produced distinct graphical patterns, reflecting the different levels in expression of IgD in normal versus neoplastic B cells.

For cases with partial involvement by BCL, the measurements of the different Ig HCs expressed were recorded exclusively for the neoplastic B cell populations. In six cases of BCL, more than one Ig HC was expressed. In such cases, the measurements were taken independently for each expressed HC. For purpose of analysis, the HC with highest MFI was selected.

Discussion

Soon after its introduction, the immunohistochemical technique was applied to reactive and neoplastic processes in lymphoid tissues and many investigators used it to examine a spectrum of antigens, including Ig HCs in benign lymphoid tissues [23-25]. However, while these studies mapped out the histological distribution of Ig HCs, their intensity of expression could not be reliably measured by this method. The utilization of FCM allowed a more objective and quantitative analysis of antigen expression on individual cells in suspension [26]. Furthermore, this analysis could be selectively applied to subsets of B cells. For instance, in cases where neoplastic and normal B cells coexist in a partially involved lymph node, one can use cell markers such as CD19 or CD20 to identify and selectively gate the malignant and normal subsets of B-cells, based upon different levels of CD20 or CD19 expression [27, 28]. Another advantage of examining individual cells in suspension is that after appropriate cell washings, there is little, if any, interference from background (interstitial) plasma immunoglobulins as

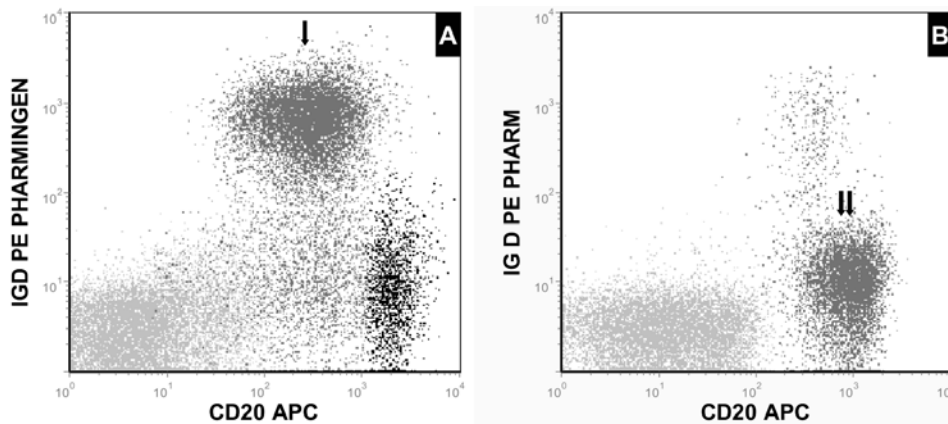


Figure 6. Two representative examples showing differences in IgD expression by normal and neoplastic B cells. In hyperplastic lymphoid tissue, the correlated analysis of CD20 and IgD expression (A) demonstrates that the majority of the mantle cells (arrow) brightly express IgD. Conversely, in lymphoma the neoplastic B cells (double arrows) express significantly lower level of IgD (B). Germinal center cells (black), mantle B cells (gray) and T cells (silver).

it usually happens with tissue sections.

Using flow cytometric measurements of CD20 in tonsils, Gadol et al described a compartmentalization of B cells in human reactive lymphoid processes [22]. Based on the intensity of surface CD20, they demonstrated two main B-cells populations that corresponded to the larger germinal center cells, with more intense CD20 expression, and mantle cells, with less intense CD20 expression. This was one of the earlier demonstrations of B cells heterogeneity in lymphoid tissues, as compared to B cells in circulation, which are mostly uniform [29]. A more recent study demonstrated that in reactive lymphoid tissues LC ratios may differ substantially between germinal center cells and mantle cells [30]. Moreover, the authors observed distinct clusters and skews in LC ratios that may be misinterpreted as evidence of lymphoma. Recognition of these differences is important in the assessment of B cell changes in lymphoid hyperplasia and lymphomas. In our study, approximately 30% of the reactive lymphoid samples showed two discreet B cell populations based on size and CD20 intensity, a finding that is consistent with the observations of Gadol et al [22]. We now also show differences in the type and level of Ig HC expression between cells in these two B cell compartments.

Like reactive lymphoid tissues, the Ig HC expression in BCL has been mostly studied using immunohistochemical techniques [8-12, 31, 32]. Early Ig studies of BCL using immunofluorescence were microscope-based [33, 34], but an adequate Ig expression assessment was not possible until the advent of FCM. There is an extensive body of literature referring to the flow cytometric assessment of Ig expression in B cell lymphoma diagnosis, but the majority of these studies have focused on surface kappa and lambda Ig LC expression [1-7]. Very few publications have addressed the diagnostic utility of surface Ig HC expression in B-cell malignancies using FCM, and the vast majority of these studies were conducted in peripheral blood [16, 29]. Batata and Shen [2] showed that the expression of a single HC, or IgM and IgD together, is complementary to LC restriction detection, and should be considered as a criterion in determining clonality. Shen et al [35] reported that IgM and IgD coexpression in B cell chronic lymphocytic leukemia was the most common immunophenotype, while IgD(+) only was less frequent. A case report by Delville et al. described a bi-

clonal composite low grade BCL with a normal kappa/lambda ratio that expressed separate IgD lambda and IgM kappa clones [36].

In our study, we found that Ig HC expression has the potential of being a useful diagnostic tool in lymphoid tissues suspected of harboring BCL. While this analysis by itself cannot determine the clonality of B cells, the immunophenotypic characteristics of the HC expression can help distinguishing benign (hyperplastic) from neoplastic proliferations. This could be of particular importance in situations when the morphologic architecture provided by histology is not available (i.e., fine needle aspirations), in case with partial involvement by BCL or in cases where there is poor discrimination between kappa and lambda Ig expression due to non-specific binding or to absence or low levels of expression of Ig LC.

The most interesting and useful finding in our study was the difference in IgD expression intensity between BCL and reactive hyperplasias. The majority of BCL subtypes demonstrated either low or no IgD expression, while reactive hyperplasias showed a variable, but more intense, expression of IgD. These differences could be readily appreciated by a visual inspection of the data. The patterns created by the differences in the intensity of IgD expression may be a useful tool to complement other flow diagnostic findings in the discrimination between reactive and malignant B cell processes.

BCL with very weak or no expression of surface Ig LC can pose a diagnostic dilemma. The lack of surface Ig light chain expression on B cells by itself is highly suggestive of lymphoma [14, 20, 21]. In such cases, the expression of a single HC by a B-cell population could be construed as a marker of monoclonality, supporting previous suggestions [2]. Combined with other immunophenotypic abnormalities often present in neoplastic B cells, monotypic surface Ig heavy chain expression, as well as the level of HC expression, could be very useful diagnostic adjuncts in discriminating between lymphoid hyperplasias and BCL, in fine needle aspirate samples, in cases with partial involvement by BCL and lymphomas with weak or no surface light chain expression.

Acknowledgement

No financial support was provided for this work and authors have no conflicts of interest.

Ig heavy chain analysis in lymphoid tissue

Address correspondence to: Dr. Samer Z Al-Quran, Department of Pathology, University of Florida College of Medicine, P.O. Box 100275, Gainesville, FL 32610 -0275; Tel: (352) 265-9919; Fax: (352) 265-9918; E-mail: salquran@ufl.edu

References

- [1] Almasri NM, Zaer FS, Iturraspe JA, Braylan RC. Contribution of flow cytometry to the diagnosis of gastric lymphomas in endoscopic biopsy specimens. *Mod Pathol* 1997; 10: 650-656.
- [2] Batata A, Shen B. Diagnostic value of clonality of surface immunoglobulin light and heavy chains in malignant lymphoproliferative disorders. *Am J Hematol* 1993; 43: 265-270.
- [3] Fukushima PI, Nguyen PK, O'Grady P, Stetler-Stevenson M. Flow cytometric analysis of kappa and lambda light chain expression in evaluation of specimens for B-cell neoplasia. *Cytometry* 1996; 26: 243-252.
- [4] Ibrahim RE, Teich D, Smith BR, Antin J, Olivier AP, Weinberg DS. Flow cytometric surface light chain analysis of lymphocyte-rich effusions. A useful adjunct to cytologic diagnosis. *Cancer* 1989; 63: 2024-2029.
- [5] Liendo C, Danieul L, Al-Katib A, Koziner B. Phenotypic analysis by flow cytometry of surface immunoglobulin light chains and B and T cell antigens in lymph nodes involved with non-Hodgkin's lymphoma. *Am J Med* 1985; 79: 445-454.
- [6] Picker LJ, Weiss LM, Medeiros LJ, Wood GS, Warnke RA. Immunophenotypic criteria for the diagnosis of non-Hodgkin's lymphoma. *Am J Pathol* 1987; 128: 181-201.
- [7] Geary WA, Frierson HF, Innes DJ, Normansell DE. Quantitative criteria for clonality in the diagnosis of B-cell non-Hodgkin's lymphoma by flow cytometry. *Mod Pathol* 1993; 6: 155-161.
- [8] Harris NL, Poppema S, Data RE. Demonstration of immunoglobulin in malignant lymphomas. Use of an immunoperoxidase technic on frozen sections. *Am J Clin Pathol* 1982; 78: 14-21.
- [9] Lauder I, Bird CC, Child JA, Grigor I. Surface membrane phenotypic expression and treatment response of malignant lymphomas. *J Pathol* 1985; 145: 259-268.
- [10] Martin SE, Zhang HZ, Magyarosy E, Jaffe ES, Hsu SM, Chu EW. Immunologic methods in cytology: definitive diagnosis of non-Hodgkin's lymphomas using immunologic markers for T- and B-cells. *Am J Clin Pathol* 1984; 82: 666-673.
- [11] Warnke R, Miller R, Grogan T, Pederson M, Dille J, Levy R. Immunologic phenotype in 30 patients with diffuse large-cell lymphoma. *N Engl J Med* 1980; 303: 293-300.
- [12] Tetu B, Manning JT Jr, Ordonez NG. Comparison of monoclonal and polyclonal antibodies directed against immunoglobulin light and heavy chains in non-Hodgkin's lymphoma. *Am J Clin Pathol* 1986; 85: 25-31.
- [13] Isaacson PG, Dogan A, Price SK, Spencer J. Immunoproliferative small-intestinal disease. An immunohistochemical study. *Am J Surg Pathol* 1989; 13: 1023-1033.
- [14] Kaleem Z, Zehnbauser BA, White G, Zutter MM. Lack of expression of surface immunoglobulin light chains in B-cell non-Hodgkin lymphomas. *Am J Clin Pathol* 2000; 113: 399-405.
- [15] Alexander HD, Markey GM, Morris TC. Diagnostic value of clonality of surface immunoglobulin light and heavy chains in malignant lymphoproliferative disorders. *Am J Hematol* 1994; 46: 256.
- [16] Babusikova O, Stevulova L. Analysis of surface and cytoplasmic immunoglobulin light/heavy chains by flow cytometry using a lysed-whole-blood technique: Implications for the differential diagnosis of B-cell malignancies. *Neoplasma* 2004; 51: 422-430.
- [17] Kettman JR, Smith RG, Uhr JW, Vitetta ES, Sheehan R, Ligler FS, Frenkel EP. Quantitative monitoring of lymphoid malignancies. Application and findings in chronic lymphocytic leukemia. *Blood Cells* 1983; 9: 21-33.
- [18] Robbins BA, Ellison DJ, Spinosa JC, Carey CA, Lukes RJ, Poppema S, Saven A, Piro LD. Diagnostic application of two-color flow cytometry in 161 cases of hairy cell leukemia. *Blood* 1993; 82: 1277-1287.
- [19] Swerdlow SH, Campo E, Harris NL, et al., editors. WHO Classification of Tumours of Haematopoietic and Lymphoid Tissues. 4th ed. Lyon: IARC Press, 2008.
- [20] Li S, Eshleman JR, Borowitz MJ. Lack of surface immunoglobulin light chain expression by flow cytometric immunophenotyping can help diagnose peripheral B-cell lymphoma. *Am J Clin Pathol* 2002; 118: 229-234.
- [21] Zhao XF, Cherian S, Sargent R, Seethala R, Bonner H, Greenberg B, Bagg A. Expanded populations of surface membrane immunoglobulin light chain-negative B cells in lymph nodes are not always indicative of B-cell lymphoma. *Am J Clin Pathol* 2005; 124: 143-150.
- [22] Gadol N, Peacock MA, Ault KA. Antigenic phenotype and functional characterization of human tonsil B cells. *Blood* 1988; 71: 1048-1055.
- [23] Hsu SM, Cossman J, Jaffe ES. Lymphocyte subsets in normal human lymphoid tissues. *Am J Clin Pathol* 1983; 80: 21-30.
- [24] Hsu SM, Jaffe ES. Phenotypic expression of B-lymphocytes. 1. Identification with monoclonal antibodies in normal lymphoid tissues. *Am J Pathol* 1984; 114: 387-395.
- [25] Hsu SM, Jaffe ES. Phenotypic expression of B-lymphocytes. 2. Immunoglobulin expression of germinal center cells. *Am J Pathol* 1984; 114: 396-402.
- [26] Weinberg DS, Ault KA, Gurley M, Pinkus GS. The human lymph node germinal center cell: char-

Ig heavy chain analysis in lymphoid tissue

- acterization and isolation by using two-color flow cytometry. *J Immunol* 1986; 137: 1486-1494.
- [27] Almasri NM, Duque RE, Iturraspe J, Everett E, Braylan RC. Reduced expression of CD20 antigen as a characteristic marker for chronic lymphocytic leukemia. *Am J Hematol* 1992; 40: 259-263.
- [28] Cornfield DB, Mitchell DM, Almasri NM, Anderson JB, Ahrens KP, Dooley EO, Braylan RC. Follicular lymphoma can be distinguished from benign follicular hyperplasia by flow cytometry using simultaneous staining of cytoplasmic bcl-2 and cell surface CD20. *Am J Clin Pathol* 2000; 114: 258-263.
- [29] Deneys V, Mazzon AM, Marques JL, Benoit H, De Bruyere M. Reference values for peripheral blood B-lymphocyte subpopulations: a basis for multiparametric immunophenotyping of abnormal lymphocytes. *J Immunol Methods* 2001; 253: 23-36.
- [30] Reichard KK, McKenna RW, Kroft SH. Comparative analysis of light chain expression in germinal center cells and mantle cells of reactive lymphoid tissues. A four-color flow cytometric study. *Am J Clin Pathol* 2003; 119: 130-136.
- [31] Harris NL, Data RE. The distribution of neoplastic and normal B-lymphoid cells in nodular lymphomas: use of an immunoperoxidase technique on frozen sections. *Hum Pathol* 1982; 13: 610-617.
- [32] Cachia AR, Diss TC, Isaacson PG. Composite mantle-cell lymphoma and plasmacytoma. *Hum Pathol* 1997; 28: 1291-1295.
- [33] Aisenberg AC, Wilkes B. Lymphosarcoma cell leukemia: the contribution of cell surface study to diagnosis. *Blood* 1976; 48: 707-715.
- [34] Habeshaw JA, Bailey D, Stansfeld AG, Greaves MF. The cellular content of non Hodgkin lymphomas: a comprehensive analysis using monoclonal antibodies and other surface marker techniques. *Br J Cancer* 1983; 47: 327-351.
- [35] Shen PU, Fuller SG, Rezuze WN, Sherburne BJ, DiGiuseppe JA. Laboratory, morphologic, and immunophenotypic correlates of surface immunoglobulin heavy chain isotype expression in B-cell chronic lymphocytic leukemia. *Am J Clin Pathol* 2001; 116: 905-912.
- [36] Delville JP, Heimann P, El Housni H, Boutriaux M, Jeronnez A, Remmelink M, Lasudry J, Pradier O, Kentos A. Biclinal low grade B-cell lymphoma confirmed by both flow cytometry and karyotypic analysis, in spite of a normal kappa/lambda Ig light chain ratio. *Am J Hematol* 2007; 82: 473-480.