Int J Clin Exp Pathol 2014;7(12):8862-8868
www.ijcep.com /ISSN:1936-2625/IJCEP0002903

Original Article

Expression of TWIST, an inducer of epithelial-mesenchymal transition, in nasopharyngeal carcinoma and its clinical significance

Xianlu Zhuo[1,2], Aoshuang Chang[2], Chuang Huang[3], Li Yang[2], Zhaolan Xiang[4], Yan Zhou[5]

[1]Department of Radiation Oncology, Chongqing Cancer Institute, Chongqing, China; [2]Affiliated Hospital of Guiyang Medical College, Guiyang, China; [3]Department of Head and Neck Surgery, Chongqing Cancer Institute, Chongqing, China; [4]Department of Otolaryngology, Southwest Hospital, Third Military Medical University, Chongqing, China; [5]Department of Stomatology, Xinqiao Hospital, Third Military Medical University, Chongqing, China

Received September 30, 2014; Accepted November 26, 2014; Epub December 1, 2014; Published December 15, 2014

Abstract: Epithelial-mesenchymal transition (EMT) has been implicated in the development of a number of cancers. An important EMT inducer, TWIST, has been detected to be over-expressed in a variety of tumors, but rarely been studied in nasopharyngeal carcinoma (NPC). This study aimed to examine TWIST expression and its association with clinicopathological factors and prognosis in NPC. A total of 65 NPC and 20 normal samples were involved in the present study. RT-PCR and immunohistochemistry were used to examine the mRNA and protein expressions of TWIST in NPC and normal tissues. The relationship of TWIST expression levels with clinical features and prognosis of NPC patients were analyzed. The positive rate of TWIST expression was markedly higher in NPC tissues than that in normal tissues. Over-expression of TWIST was correlated with N stage and the presence of distant metastasis. Patients with positive TWIST expression had a significantly shorter overall survival time relative to patients with negative TWIST expression. The data suggest that TWIST over-expression has a correlation with lymphatic and distant metastasis in NPC. Moreover, it might be a novel biomarker for prediction of advanced tumor progression and a potential unfavorable prognostic factor as well as a potential treatment target for NPC.

Keywords: Nasoparyangeal carcinoma, TWIST, expression, inmmunohistochemistry, prognosis

Introduction

Nasopharyngeal cancer (NPC) is a type of fast-growing tumor originates from nasopharyngeal region and is characterized by a high frequency of nodal and distant metastasis at diagnosis [1]. The incidence of NPC is rare in many areas of the world but common in Southeast Asia and North Africa [2]. Epidemiologically, external factors such as Epstein-Barr virus (EBV) infection, smoking, drinking and environmental chemical pollutions have been thought to be risk factors for NPC [3-5]. Besides, internal factors such as genetic variation have been indicated to play a role in the development of NPC [6].

Previously, epithelial-mesenchymal transition (EMT), a key event of embryogenesis that has been shown to be correlated closely with development and progression of tumors, has attracted much attention [7]. EMT is an essential step for the formation of different tissues and organs during the process of embryonic development, while in adult tissue it may be inhibited for maintaining epithelial integrity and homeostasis [8]. Aberrant activation of EMT in epithelial tumors usually has been implicated in development and recurrence of the cancers. During this process, some molecules have been regarded as inducers of EMT. TWIST, a basic helix-loop-helix transcription factor, has been thought to be one of the EMT inducers and detected in a variety of carcinomas. Recent reports showed that TWIST is a useful predictor of unfavorable prognosis for ovarian cancer [9] and renal cell carcinoma [10]. Besides this, over-expression of TWIST might be associated with lymph node metastasis for thyroid cancer [11] and gastric cancer [12]. Moreover, TWIST might contribute to breast cancer progression by regulating

Table 1. Patient characteristics

Characteristic	No. of patients
Age (year)	
< 45	40
≥ 45	25
Gender	
Male	39
Female	26
Clinical stage	
I	8
II	20
III	13
IV	24
T stage	
T1	19
T2	11
T3	21
T4	14
N stage	
N0	22
N1	17
N2	14
N3	12
Distant metastasis	
M0	55
M1	10

expression of MMP-2 and -9 [13]. Therefore, TWIST might not only play a crucial role in early events of cancers, but also act as an essential factor in their advanced phases.

Up to date, only a few studies have evaluated the expression of TWIST in NPC tissues. However, the results were inconclusive. In the present study, we assessed the expression of TWIST in NPC tissues and further evaluated its association with the clinicopathological data and patient outcomes.

Materials and methods

Patients and tissue samples

A total of 65 paraffin-embedded NPC samples from NPC patients who were histologically and clinically diagnosed from the affiliated hospital of Guiyang Medical College, Southwest Hospital and Xinqiao Hospital, China, between 2001 and 2010. Twenty samples of benign nasopharyngeal disease were used as controls (**Table 1**). All of the patients received no radiotherapy or chemotherapy before operation. Patients were informed of the investigational nature of the research and each provided written informed consent prior to recruitment. For reverse transcriptase polymerase chain reaction (RT-PCR) examination, 15 cases of freshly resected tumor and 15 cases of normal mucosa tissues were immediately cut into small pieces and snap frozen in liquid nitrogen. The stage and the histology of cases were classified according to the 2010 American Joint Committee on Cancer (AJCC, 7th edition). The characteristics of the NPC patients are listed in **Table 1**. All patients were treated with standard curative radiotherapy with or without relevant chemotherapy. The follow-up time for overall survival (OS) ranged from 10-80 months.

Immunohistochemical staining

TWIST protein expression in NPC and normal tissues were tested by using the two-step PV method of immunohistochemistry (IHC). Samples were fixed with 10% neutral formaldehyde solution. The staining was performed on 4 μm sections from formalin-fixed and paraffin-embedded tissue. The slides were deparaffinized, rehydrated and treated with 3% hydrogen peroxided for 20 min to inhibit endogenous peroxidase. The sections were rinsed with distilled water and saturated in phosphate buffered saline (PBS) for 5 min and then were incubated with a 1:50 dilution of rabbit anti-polyclonal antibody (primary antibody; Abcam) overnight at 4°C. Then the reaction was performed using the PV-9000 Polymer Detection System (Zhongshan Biotech, Beijing, China). The staining was visualized using DAB solution and counterstained with hematoxylin. IHC staining was conducted according to the manufacture's instructions.

Evaluation of IHC staining

The IHC stain results were identified by integrated scoring. Four fields of view, each at 400 × magnification were randomly sampled from the upper, lower, left, right and central part of the slice. The results were evaluated and scored independently by two pathologists without knowledge of the clinical parameters of the cases. The expression of TWIST was classified into several groups according to the percentage of positively staining cells: Grade 0 (negative), ≤ 5%; Grade 1, 5%-25%; Grade 2, 25%-50%; Grade 3, 50%-75%; and Grade 4, ≥ 75%.

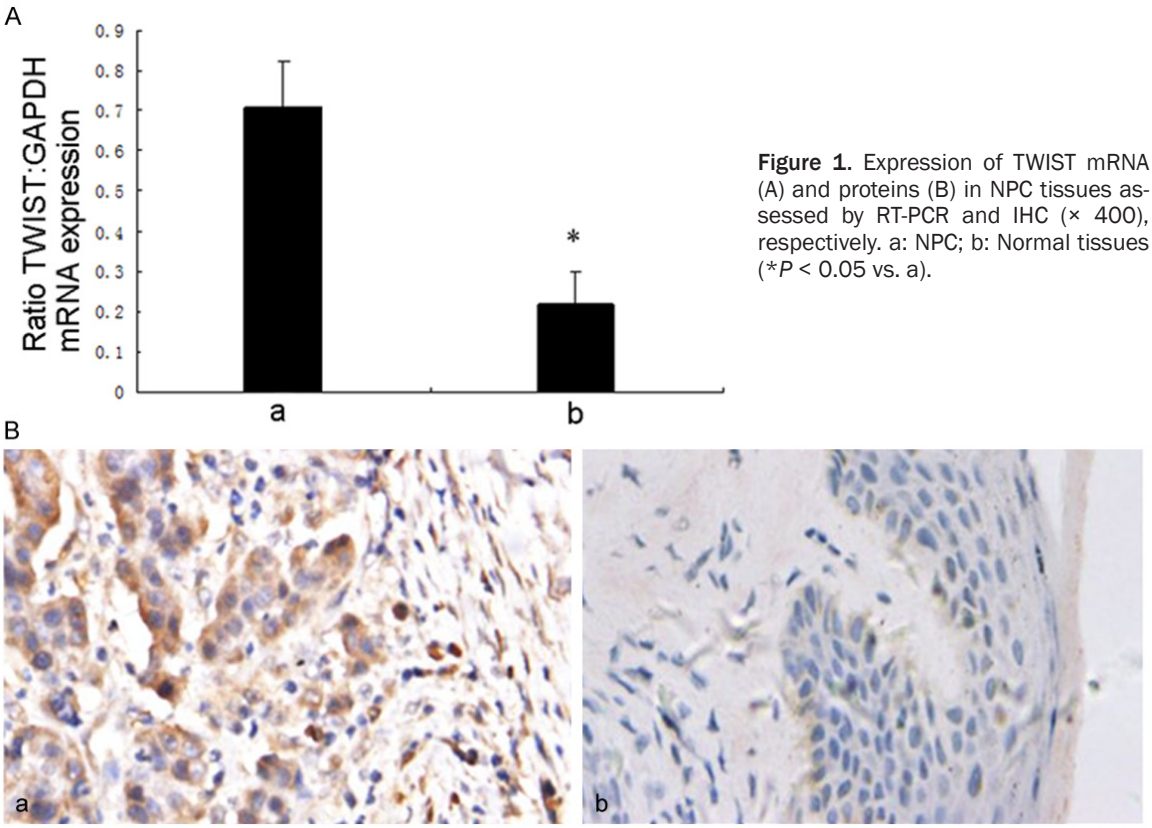

Figure 1. Expression of TWIST mRNA (A) and proteins (B) in NPC tissues assessed by RT-PCR and IHC (× 400), respectively. a: NPC; b: Normal tissues (*$P < 0.05$ vs. a).

Table 2. Expression of TWIST proteins in NPC and normal tissues

Type	n	TWIST				*P* value
		-	+	++	+++	
NPC	65	19	15	18	13	< 0.05
Normal	20	17	2	1	0	

The staining intensity was categorized as follows: Grade 0, negative; Grade 1, weak; Grade 2, moderate; and Grade 3, strong. The proportion and intensity scores were then multiplied to gain a total score: score 0-1, negative (-); score 2-3, mildly positive (+); score 4-5, moderate positive (++); score ≥ 6, strong positive (+++).

Semiquantitative RT-PCR assay

Total RNA was isolated from tissues with TRIzol Reagent (Invitrogen) and first strand cDNA was synthesized from 1 μg total RNA using Oligo d (T) primer (Invitrogen) and ReveTra Ace (TOYOBO, Osaka, Japan). PCR was done on the cDNA product using the following primers for TWIST: F: 5'-GGAGTCCGCAGTCTTACGAG-3' and R: 5'-TCTGGAGGACCTGGTAGAGG-3'. for GAPDH: F: 5'-CAGTGCCAGCCTCGTCTCAT-3' and R: 5'-AGGGGCCATCCACAGTCTTC-3'. Thermal cycler parameters included one cycle at 94°C for 0.5 min, and 30 cycles involving denaturation at 94°C for 30 s annealing at 58°C for 45 s and extension at 72°C for 60 s. Extension was performed for an additional 10 min after the completion of the indicated cycles. The bands were quantified by densitometric scanning of band intensities and normalized to the levels of GAPDH using Image-Pro Plus 5.0 software (Media Cybernetics, Silver Spring, MD, USA).

Statistical analysis

For continuous variables, data were expressed as mean value ± SD. Differences between groups were analyzed with Analysis of Variances (ANOVA) or a *t*-test. χ^2 test or Fisher's exact test was used to differentiate the rates of different groups. Survival curves were plotted by the Kaplan-Meier method and compared by using the log-rank test. These analyses were performed by utilizing Microsoft excel program (Version: 2003) and SPSS for Windows version 18.0 (SPSS Inc., Chicago, IL). *P* value less than 0.05 was considered statistically significant.

Table 3. Relationship between TWIST expression and clinicopathological factors

Variables	Total	Twist expression		*P* value
		Positive	Negative	
Gender				
Male	39	27	12	> 0.05
Female	26	19	7	
Age (years)				
< 45	40	28	12	> 0.05
≥ 45	25	18	7	
Clinical stage				
I + II	28	17	11	> 0.05
III + IV	37	29	8	
T stage				
T1 + T2	30	19	11	> 0.05
T3 + T4	35	27	8	
N stage				
N0 + N1	39	23	16	< 0.05
N2 + N3	26	23	3	
Distant metastasis status				
M0	55	36	19	< 0.05
M1	10	10	0	

Results

Expression of TWIST mRNA assessed by RT-PCR

To learn the status of TWIST mRNA expression levels in NPC and normal tissues, RT-PCR assay was used. mRNAs were obtained from 15 NPC and 15 normal tissues. The results showed that TWIST mRNA expression was markedly higher in NPC tissues relative to that in the normal tissues (**Figure 1A**), indicating that TWIST mRNA levels in NPC tissues were up-regulated.

Expression of TWIST protein assessed by IHC

The samples were tested for TWIST expression by IHC with the specific antibodies. As shown in **Table 2**, positive staining of TWIST was observed in 70.8% (46/65) and 15% (3/20) of NPC and the control samples, respectively. Specific staining was found in the nuclei and cytoplasm of the cells (**Figure 1B**). The positive rate of TWIST expression in NPC tissues was significantly higher than that in the normal tissues, in line with the mRNA expressions ($P < 0.05$).

Relationship between clinicopathologic features and expression of TWIST proteins

The association of TWIST expression with clinicopathologic parameters was presented in **Table 3**. No associations could be observed between TWIST positive expression and age, gender, T and clinical stage, respectively. Nevertheless, there were marked associations of TWIST expression with N stage and Distant metastasis status. Patients with advanced N stage present elevated TWIST positive expression rate relative to patients with early N stage. Expression rate of TWIST in patients with distant metastasis was markedly higher than that in patients without distant metastasis.

Association of TWIST protein expression with the prognosis of human NPC

The association between TWIST expression and the prognosis of NPC was evaluated. As shown in **Figure 2**, the log-rank test showed that the negative TWIST expression group had a longer survival time, while the positive TWIST group had a shorter survival time ($P < 0.05$), indicating that TWIST positive expression might be a prognostic factor for NPC patients.

Discussion

In the present study, we examined the expression of TWIST in NPC tissues by IHC and RT-PCR and found that TWIST was over-expressed in the NPC tissues compared to the normal tissues. Over-expression of TWIST in NPC might be associated with advanced N stage and the presence of distant metastasis, indicating that TWIST might be an important biomarker for NPC and contribute to cancer development and progression.

NPC is characterized by silent development and atypical clinical features, such as early metastasis to the neck lymph nodes. The mechanisms of NPC development are not fully understood. Recently, EMT has attracted much attention because this term describes a process in which cells lose epithelial and gain mesenchymal characteristics. This process is

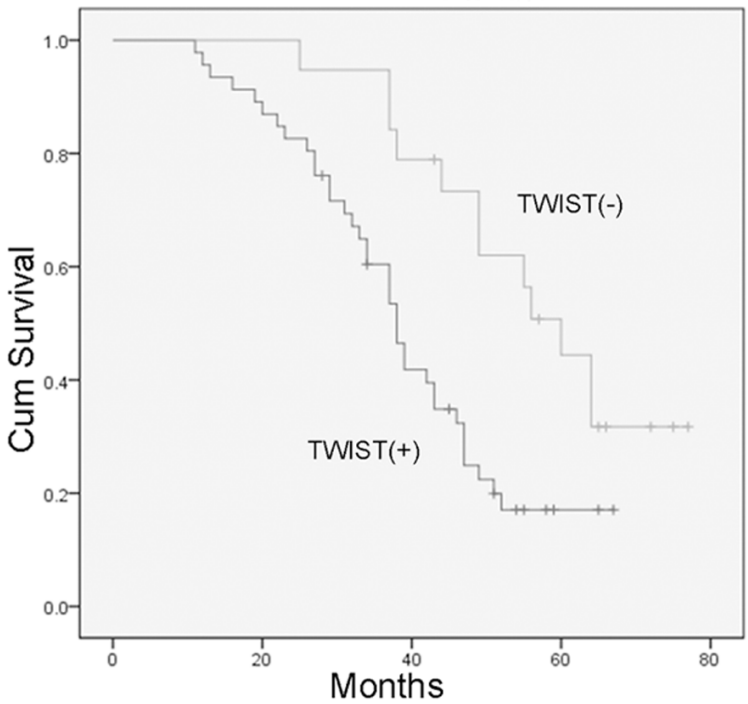

Figure 2. The overall survival Kaplan-Meier curves in patients with positive and negative expression of TWIST.

accompanied by a loss of cell-cell cohesiveness, leading to enhanced cell migratory capacity [14]. Thus, the EMT pathway is of great therapeutic interest in the treatment of cancer and could be targeted either to prevent tumor dissemination in patients at high risk of developing metastatic lesions or to eradicate existing metastatic cancer cells in patients with more advanced disorders [15].

TWIST as an important inducer of EMT has been detected to be over-expressed in a number of cancers. In this study, over-expression of TWIST was observed in NPC tissues, indicating that TWIST might have a correlation with the genesis of NPC. The results further showed that elevated expression of TWIST was associated with advanced N stage and distant metastasis, in accordance with a previous study published in 2006 [16]. The data suggested that TWIST might mainly enhance the metastatic ability of cancer cells and contribute to NPC progression. The mechanisms of TWIST in cancer progression are not clear yet. TWIST could inhibit E-cadherin expression and interfere with the p53 tumor-suppressor pathway [17]. As a transcription factor, it might alter gene expression and promote loss of cell-cell adhesion, leading to a shift in cytoskeletal dynamics and a change from epithelial morphology and physiology to the mesenchymal phenotype [18]. Thus, the cells acquired elevated migratory abilities. Moreover, Twist can recruit stromal macrophages and promote angiogenesis [19]. In addition, TWIST might increase microvessel density through up-regulation of MMP-9 expression [20]. Therefore, TWIST might contribute to cell migration and metastasis via complex pathways. Notably, in the present study, the data failed to show a correlation between TWIST expression and T stage and clinical stage, inconsistent with evidence that tumor volumes were associated with an inreased incidence of nodal metastasis and cancer development [21]. Therefore, the results should be interpreted with care because a deviation might exist possibly due to the limited sample size and any confounding factors. Future studies with large sample sizes considering more confounding factors are required.

In the present study, NPC patients with negative TWIST expression had a longer survival time compared to those with positive TWIST expression, indicating that TWIST might act as a biomarker predicting NPC progression and survival.

Several limitations might be included in this study. First, the present study evaluated the roles of TWIST in NPC and found that TWIST might act as an indicator for prediction of NPC progression. Nevertheless, the underlying mechanisms of TWIST contributing to NPC metastasis are still unknown. Second, this study only involved patients with relatively detailed information rather that patients with incomplete information. Therefore, any selection bias might exist. Third, the sample size in the present study is limited. Thus, future studies with large sample sizes in vivo and in vitro are needed to explore the underlying mechanisms and increase power to address this issue.

In summary, the results of the present study showed that over-expression of TWIST might be associated with lymphatic and distant metastasis of NPC. TWIST might be a significant prognostic factor in predicting overall survival of NPC and a potential target for cancer biotherapy.

Acknowledgements

The present study was supported by the National Natural Science Foundation of China (No. 81101145) and Special Foundation of China Postdoctoral Science (2012T50851).

Disclosure of conflict of interest

None.

Address correspondence to: Dr. Xianlu Zhuo, Department of Radiation Oncology, Chongqing Cancer Institute, Chongqing 400000, China. E-mail: zhuoxianlu@gmc.edu.cn

References

[1] Mao CG, Tao ZZ, Wan LJ, Han JB, Chen Z and Xiao BK. The efficacy of traditional Chinese Medicine as an adjunctive therapy in nasopharyngeal carcinoma: a systematic review and meta-analysis. J BUON 2014; 19: 540-548.

[2] Kontos CK, Fendri A, Khabir A, Mokdad-Gargouri R and Scorilas A. Quantitative expression analysis and prognostic significance of the BCL2-associated X gene in nasopharyngeal carcinoma: a retrospective cohort study. BMC Cancer 2013; 13: 293.

[3] Chen CJ, Hsu WL, Yang HI, Lee MH, Chen HC, Chien YC and You SL. Epidemiology of virus infection and human cancer. Recent Results Cancer Res 2014; 193: 11-32.

[4] Khlifi R, Olmedo P, Gil F, Molka FT, Hammami B, Ahmed R and Amel HC. Risk of laryngeal and nasopharyngeal cancer associated with arsenic and cadmium in the Tunisian population. Environ Sci Pollut Res Int 2014; 21: 2032-2042.

[5] Polesel J, Franceschi S, Talamini R, Negri E, Barzan L, Montella M, Libra M, Vaccher E, Franchin G, La Vecchia C and Serraino D. Tobacco smoking, alcohol drinking, and the risk of different histological types of nasopharyngeal cancer in a low-risk population. Oral Oncol 2011; 47: 541-545.

[6] Jiang N, Liu N, Yang F, Zhou Q, Cui R, Jiang W, He Q, Li W, Guo Y, Zeng J, Yun J, Chen X, Zhou B, Sun Y, Wang H, Chen ZG and Ma J. Hotspot mutations in common oncogenes are infrequent in nasopharyngeal carcinoma. Oncol Rep 2014; 32: 1661-1669.

[7] Wendt MK, Balanis N, Carlin CR and Schiemann WP. STAT3 and epithelial-mesenchymal transitions in carcinomas. JAKSTAT 2014; 3: e28975.

[8] Macara IG, Guyer R, Richardson G, Huo Y and Ahmed SM. Epithelial Homeostasis. Curr Biol 2014; 24: R815-R825.

[9] Kim K, Park EY, Yoon MS, Suh DS, Kim KH, Lee JH, Shin DH, Kim JY, Sol MY and Choi KU. The Role of TWIST in Ovarian Epithelial Cancers. Korean J Pathol 2014; 48: 283-291.

[10] Ohba K, Miyata Y, Matsuo T, Asai A, Mitsunari K, Shida Y, Kanda S and Sakai H. High expression of Twist is associated with tumor aggressiveness and poor prognosis in patients with renal cell carcinoma. Int J Clin Exp Pathol 2014; 7: 3158-3165.

[11] Wang N, Luo HJ, Yin GB, Dong CR, Xu M, Chen GG and Liu ZM. Overexpression of HIF-2alpha, TWIST, and CXCR4 is associated with lymph node metastasis in papillary thyroid carcinoma. Clin Dev Immunol 2013; 2013: 589423.

[12] Gao XH, Yang XQ, Wang BC, Liu SP and Wang FB. Overexpression of twist and matrix metalloproteinase-9 with metastasis and prognosis in gastric cancer. Asian Pac J Cancer Prev 2013; 14: 5055-5060.

[13] Zhao M, Hu HG, Huang J, Zou Q, Wang J, Liu MQ, Zhao Y, Li GZ, Xue S and Wu ZS. Expression and correlation of Twist and gelatinases in breast cancer. Exp Ther Med 2013; 6: 97-100.

[14] Steinestel K, Eder S, Schrader AJ and Steinestel J. Clinical significance of epithelial-mesenchymal transition. Clin Transl Med 2014; 3: 17.

[15] Davis FM, Stewart TA, Thompson EW and Monteith GR. Targeting EMT in cancer: opportunities for pharmacological intervention. Trends Pharmacol Sci 2014; 35: 479-488.

[16] Song LB, Liao WT, Mai HQ, Zhang HZ, Zhang L, Li MZ, Hou JH, Fu LW, Huang WL, Zeng YX and Zeng MS. The clinical significance of twist expression in nasopharyngeal carcinoma. Cancer Lett 2006; 242: 258-265.

[17] Fan CC, Wang TY, Cheng YA, Jiang SS, Cheng CW, Lee AY and Kao TY. Expression of E-cadherin, Twist, and p53 and their prognostic value in patients with oral squamous cell carcinoma. J Cancer Res Clin Oncol 2013; 139: 1735-1744.

[18] Gonzalez DM and Medici D. Signaling mechanisms of the epithelial-mesenchymal transition. Sci Signal 2014; 7: re8.

[19] Low-Marchelli JM, Ardi VC, Vizcarra EA, van Rooijen N, Quigley JP and Yang J. Twist1 induces CCL2 and recruits macrophages to promote angiogenesis. Cancer Res 2013; 73: 662-671.

[20] Che N, Zhao XL, Sun T, Zhao XM, Gu Q, Dong XY, Zhao N, Liu YR, Yao Z and Sun BC. The role of Twist1 in hepatocellular carcinoma angiogenesis: a clinical study. Hum Pathol 2011; 42: 840-847.

[21] Fu J, Zhou JY, Chong VF and Khoo JB. Indication of lower neck irradiation in nasopharyngeal carcinoma without nodal metastasis: the potential impact of tumor volume. Chin Med J (Engl) 2013; 126: 2120-2124.