

Original Article

Application of IMF screws to assist internal rigid fixation of jaw fractures: our experiences of 168 cases

Zhenxi Bai^{1*}, Zhibiao Gao¹, Xia Xiao¹, Wenjuan Zhang¹, Xing Fan¹, Zhaoling Wang^{2*}

¹Department of Stomatology, Affiliated Hospital of Yan'an University, Yan'an 716000, Shaanxi, China;

²Department of Stomatology, General Hospital of Jinan Military Command, Jinan 250031, Shandong, China.

*Equal contributors.

Received July 1, 2015; Accepted August 20, 2015; Epub September 1, 2015; Published September 15, 2015

Abstract: Intermaxillary fixation (IMF) screws were first introduced to achieve IMF as a kind of bone borne appliance for jaw fractures in 1989. Because this method can overcome many disadvantages associated with tooth borne appliance, IMF screws have been popularly used for jaw fractures since then. From March 2011 to February 2014, we treated 168 cases with single or multiple jaw fractures by open reduction and a total of 705 IMF screws were intraoperatively applied in all the cases to achieve IMF and maintain dental occlusion as an adjuvant to open reduction. The numbers, implantation sites and complications of IMF screws were retrospectively analyzed. In our experience, we found that IMF screws were important to assist open reduction of jaw fractures but their roles should be objectively assessed and the reliability of open reduction and internal rigid fixation must be emphasized. Much attention should be paid when implanting.

Keywords: Intermaxillary fixation (IMF), IMF screw, jaw fracture, open surgery

Introduction

When treating jaw fractures, one of the most important purposes is to restore the pre-injury occlusion. To achieve this goal, intermaxillary fixation (IMF) is conventionally applied during the procedure. Historically many types of tooth-borne devices are used for restoration of occlusion and mandible immobilization, such as arch bars, dental and interdental wiring, metallic and nonmetallic splints. Additionally, Arthur and Bernado [1] introduced a technique of applying cortical bone screws for IMF, which is indeed a kind of bone borne device. As compared with tooth borne devices, bone screws can reliably achieve dental occlusal restoration with many advantages [2], such as saving time, simple intraoral manipulation, stable anchorage for IMF even on patients with teeth problems, minimal hardware exposure in oral cavity and improved oral hygiene, decreased possibility of viral pathogens transmission, painless and fast removal. Since it was first introduced in 1989 [1], IMF technique has become increasingly popular in clinic practices. In our depart-

ment, we treated 168 cases of jaw fractures that underwent open reduction and internal rigid fixation under general anesthesia. IMF screws were applied in this series for intraoperatively temporary IMF or postoperatively short time IMF. In this article, our experiences were reported.

Materials and methods

A total of 168 patients with jaw fractures, male aged from 13 to 73 years old (mean age 36 years old), who presented to the Department of Stomatology of the Affiliated Hospital of Yan'an University, Yan'an, China, from March 2011 to February 2014, were included in this study. The study was reviewed and approved by the Ethics Committee of General Hospital of Yan'an University.

Of these cases, 80 suffered with single mandibular fractures, 56 with multiple mandibular fractures, 20 with maxillary fractures and 12 with combined maxillo-mandibular fractures. All patients underwent open reduction and rigid internal fixation under general anesthesia. Self

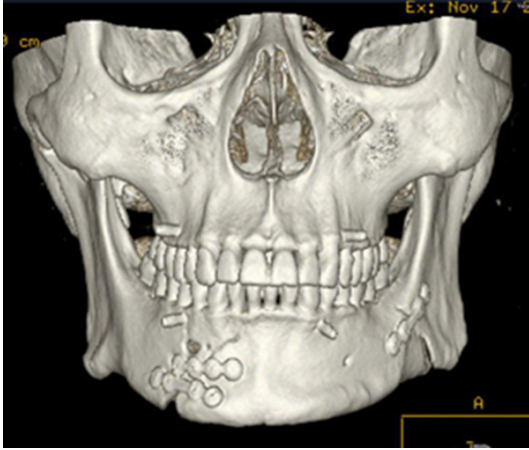


Figure 1. Frontal 3-dimensional CT view of mandibular fractures (in mental and left angle region) treated by open reduction in conjunction with intermaxillary fixation. 4 IMF screws were applied between canines and first premolars and removed 4 days after surgery.

tapping titanium IMF screws of 2 mm diameter and 8-10 mm length with 3.5 mm-long head were intraoperatively used for IMF to assist occlusal restoration. The implantation sites were 5-8 mm above mucogingival line and determined by fracture lines. Basically, there was one screw applied in each quadrant (**Figure 1**) and 4-6 screws per patient were applied. After horizontally incising mucosa of implantation site about 2-3 mm long, trans-mucosal drilling was done with 1.6 mm diameter drill of 10 mm length. And then the screw was screwed in till the head reach the mucosa and then its stability was checked. When open reduction of fractured fragments was achieved, elastic loops were used to establish intermaxillary elastic traction and thus to maintain the recovered occlusion. Thereafter, internal rigid fixation by titanium plates and screws was done. Dental occlusion was then checked. For cases with satisfied occlusion, IMF was released and the IMF screws were soon removed, while for those with occlusal discrepancy postoperatively traction was needed to adjust the occlusion. The screws were finally removed till the occlusion was restored.

The numbers, implantation sites and complications of IMF screws were retrospectively analyzed. All cases were followed up for 1 to 3 months to evaluate the recovery of dental occlusions and bony healing.

Results

A total of 705 screws were used in these 168 cases. 4 screws per patient were applied in 147 cases (88%). 6 screws per patient were applied in 12 cases (7%) and 5 screws per patient were applied in 9 cases (5%). All cases with more than 4 screws had multiple fracture lines.

The most preferred site for implantation was between the premolars (47.7%) followed by the space between canine and first premolar (41.4%). The other screws (10.9%) were inserted in the spaces between second premolar and first molar (7.1%), between lateral incisor and canine (2.3%), between middle incisor and lateral incisor (1.1%), and between first molar and second molar (0.4%).

Several complications were observed. During implantation, 6 screws were fractured and subsequently replaced. Pressure ulcers of the mucosa occurred around 23 screws (3.3%) and therefore buffers were applied when elastic traction. Ulcers spontaneously healed after removal of screws. Damage to dental roots was confirmed by X-ray examination in implantation of 13 screws (1.8%) because of toothache. The complaints were subsided after screws removal. No special treatment was needed. Loosening of 11 screws (1.6%) was noticed. Soft tissue burying of 7 screws (1.0%) were observed in this series. No other complications were found.

Dental occlusions of 92 cases (out of 168 cases) were satisfied after internal rigid fixation and the screws were removed after wound closure. 76 cases received postoperatively elastic traction for 3 to 14 days, among which 71 cases achieved satisfied occlusion while the other 5 cases having multiple fractures received occlusal adjustments to get acceptable occlusions. All the fractures healed uneventfully. There was no infection associated with the IMF screws. No obvious complications were found during follow-up.

Discussion

Since IMF screws were first introduced for treatment of mandibular fractures, this technique have showed more advantages over tooth borne devices for IMF [3], and nowadays, IMF screws are widely used for treatment of jaw

Intermaxillary fixation (IMF) screws for jaw fractures

fractures. In this study, a total of 705 IMF screws were applied for intermaxillary fixation to assist reduction of jaw fractures, and similar documented advantages were found.

Due to application of plating systems for open reduction and internal rigid fixation of jaw fractures, prolonged IMF was reduced. Nevertheless, IMF is still indispensable for treatment of jaw fractures [4]. In literatures, 4 to 10 screws were applied for IMF according to the fracture types [3, 5]. Considering internal rigid fixation can provide stabilization of reduced fractured fragments, in this study not more than 6 screws were applied. As a result, 4 screws were enough for 88% cases and only 1 or 2 more screws were needed to enhance the anchorage for those with multiple fracture lines in this series. Most of the cases (163 out of 168 cases) achieved satisfied outcomes. It means that internal rigid fixation could lessen the number of IMF screws needed for temporary IMF. However, there were 5 cases of this series could not achieve satisfied occlusion even after 14-days elastic traction. Despite that these cases had multiple fracture lines, the iatrogenic forces produced when conducting internal rigid fixation may result in the occlusal discrepancy, for plating systems make it very hard to adjust the dental occlusion merely by IMF if dental occlusion is not properly restored before rigid fixation. It requires that unexpected forces must be avoided when conducting internal rigid fixation by precise operation. We think the main purpose of IMF screws application is to intraoperatively assist open reduction and internal rigid fixation and sometimes to adjust postoperative dental occlusion. IMF is a good adjunctive method rather than a determining method.

Because of the protrusion of anterior jaws, the preferred area for IMF screws implantation is from canine to first molar [3, 6]. We also chose this area for 89% implantation of IMF screws. However, the sites of implantation were also determined by the course of fracture lines. As posterior implantation is somewhat complicated [7], only 0.4% of screws was placed between first molar and second molar. For cases with posterior fracture line, IMF screws were applied in the frontier area and the main part of occlusal platform was kept stable by elastic IMF. After that, posterior fragment was manually

reduced and then rigid fixed by plating system. This could greatly facilitate the procedure of open reduction and fixation. In our opinion, it is not necessary to place screws on both sides of fracture line (**Figure 1**).

Since there is no absolutely safe method for clinical practices, some complications related to IMF screws were also founded in our series, but the incidence rate was a little lower than ever reported [3, 8-10]. We attribute this lower incidence rate to following some principals when implanting IMF screws. Most of all, the reliability of open reduction and internal rigid fixation was emphasized to ensure a short duration of IMF with less IMF screws and thus minimized the related complications. Besides that, the sites of implantation were carefully selected as discussed above to secure screws and avoid dental root damages. In this procedure, X-ray examination of alveolar may be of great help. And when drilling, the depth and direction were carefully controlled and entangling of soft tissues was avoided. This operation was conducted under direct sight for enhanced safety. Meanwhile, coolant was used to minimize thermal damage. As for prevention of screw fracture, proper rotational stresses and correct direction for implantation should always be kept in mind. As over-tight traction (and/or a long distance between maxillary screws with their mandibular counterparts) on the outer surface of the jaws may cause tilting of fractured fragments and thus leads to occlusal gapping [3], we preferred elastic traction between IMF screws to produce consistent and mild force to actively reduce fractured fragments and restore the pre-injury occlusion.

In summary, from our observation, IMF screws are of great help for open reduction treatment of jaw fractures as an adjuvant when properly applied. However, the associated complications could not be overlooked and much attention should be paid on the operation. Furthermore, their roles should be objectively assessed and the reliability of open reduction and internal rigid fixation must be emphasized.

Acknowledgements

This work was supported by the China Postdoctoral Science Foundation (NO. 2014M-552697).

Intermaxillary fixation (IMF) screws for jaw fractures

Disclosure of conflict of interest

None.

Address correspondence to: Dr. Zhenxi Bai, Department of Stomatology, Affiliated Hospital of Yan'an University, Yan'an 716000, Shaanxi, China. Tel: +86 911 2881278; E-mail: jasonbai145@126.com; Dr. Zhaoling Wang, Department of Stomatology, General Hospital of Jinan Military Command, Jinan, Shandong, 250031, China. Tel: +86 531 51665976; E-mail: zhaolingw@163.com

References

- [1] Arthur G, Bernado N. A simplified technique of maxillo-mandibular fixation. *Br J Oral Maxillofac Surg* 1989; 47: 1234.
- [2] Nandini GD, Balakrishna R, Rao J. Self tapping screws v/s Erich arch bar for inter maxillary fixation: a comparative clinical study in the treatment of mandibular fractures. *J Maxillofac Oral Surg* 2011; 10: 127-31.
- [3] Cornelius CP, Ehrenfeld M. The use of MMF screws: surgical technique, indications, contraindications, and common problems in review of the literature. *Craniomaxillofac Trauma Reconstr* 2010; 3: 55-80.
- [4] Akadiri OA, Omitiola OG. Maxillo-mandibular fixation: utility and current techniques in modern practice. *Niger J Med* 2012; 21: 125-33.
- [5] West GH, Griggs JA, Chandran R, Precheur HV, Buchanan W, Caloss R. Treatment outcomes with the use of maxillomandibular fixation screws in the management of mandible fractures. *J Oral Maxillofac Surg* 2014; 72: 112-20.
- [6] Purmal K, Alam MK, Pohchi A, Abdul Razak NH. 3D mapping of safe and danger zones in the maxilla and mandible for the implantation of intermaxillary fixation screws. *PLoS One* 2013; 8: e84202.
- [7] Ansari K, Hamlar D, Ho V, Hilger P, Côté D, Aziz T. A comparison of anterior vs posterior isolated mandible fractures treated with intermaxillary fixation screws. *Arch Facial Plast Surg* 2011; 13: 266-270.
- [8] Coburn DG, Kennedy DW, Hodder SC. Complications with intermaxillary fixation screws in the management of fractured mandibles. *Br J Oral Maxillofac Surg* 2002; 40: 241-243.
- [9] Coletti DP, Salama A, Caccamese JF Jr. Application of intermaxillary fixation screws in maxillofacial trauma. *J Oral Maxillofac Surg* 2007; 65: 1746-1750.
- [10] Hashemi HM, Parhiz A. Complications using intermaxillary fixation screws. *J Oral Maxillofac Surg* 2011; 69: 1411-4.