

## Original Article

# Clinicopathological features of cryoglobulinemic glomerulonephritis associated with HBV infection: a retrospective analysis of 8 cases in China

Chen Wang<sup>1\*</sup>, Zi-Yin Ye<sup>2\*</sup>, De-Hua Zeng<sup>3</sup>, Fei-Lai Xie<sup>3</sup>, Li-Juan Qu<sup>3</sup>, Zhi-Yong Zheng<sup>3</sup>

<sup>1</sup>Department of Pathology, Fujian Provincial Hospital, Fujian Provincial Clinical College of Fujian Medical University, Fuzhou, China; <sup>2</sup>Department of Pathology, The First Affiliated Hospital of Sun Yat-sen University, Guangzhou, China; <sup>3</sup>Department of Pathology, Dongfang Hospital, Fujian Medical University, Fuzhou, China. \*Equal contributors and co-first authors.

Received July 9, 2015; Accepted August 21, 2015; Epub September 1, 2015; Published September 15, 2015

**Abstract:** Aims: We retrospectively analyzed clinicopathologic features of 8 cases of hepatitis B virus-associated glomerulonephritis with hyaline thrombi, to confirm the diagnosis of cryoglobulinemic glomerulonephritis (CRYGN) associated with HBV infection. Methods: Retrospective analysis was carried out with demographic information, clinical manifestations, laboratory parameters, pathological and prognostic features. Results: The median age of 8 patients was 30.5 years (range, 21-75 years), including 6 males and 2 females (M:F = 3:1). One patient had Raynaud's syndrome. Cryoglobulin testing was performed in 4 cases of our series, and 3 cases had elevated cryocrit (>256). Serum C4 decreased in all detected cases. Histopathologically, all cases showed hyaline thrombi occluded in capillary lumina; Co-deposit of IgG, IgM, IgA, Fib, C3d, C4d, C1q, HBsAg and HbCAb were identified in hyaline deposit/hyaline thrombi with polyclonal Igκ and Igλ staining. Ultrastructural examination confirmed the hyaline thrombi to be huge electron-dense bodies, which were a homogeneous texture. Conclusions: The results suggest that 8 cases in the series are CRYGN associated with HBV infection. The incidence of CRYGN associated HBV was extremely low. Our series suggested that prognosis of CRYGN associated HBV was better in patients with mild symptoms, but it was poor in elder patients with severe vasculitis.

**Keywords:** Hyaline thrombi, cryoglobulinemia, glomerulonephritis, hepatitis B virus

## Introduction

Mixed cryoglobulinemia is occasionally seen in patients with hepatitis B virus (HBV) infection, which present as protracted purpura, ulcerative skin lesions, etc [1, 2]. It may share similar mechanism as HCV infection commonly with a poly-oligoclonal B-lymphocyte expansion, which are responsible for the production of different autoantibodies and immune-complexes, such as mixed cryoglobulins [3].

Kidney may be affected by HBV infection. Although pathology of hepatitis B virus-associated glomerulonephritis (HBV-GN) has not been clearly defined so far, it is believed to be an immune complex-mediated process that is most often associated membranous glomerulopathy or membranoproliferative glomerulonephritis types I and III [4]. We have found a few

cases of HBV-GN showed membranous nephropathy and membranoproliferative glomerulonephritis with hyaline thrombi occluded in capillary lumina, which was believed to be mixed cryoglobulins. HBV infection is an uncommon cause of cryoglobulinemia. Renal cryoglobulinemia has been rarely reported in the setting of chronic hepatitis B infection. We retrospectively analyzed clinicopathologic features of a series of HBV-GN cases with hyaline thrombi, which thought to be cryoglobulinemic glomerulonephritis (CRYGN) associated with HBV infection, may expand our understanding of the disease.

## Materials and methods

### Patients

Renal biopsy records from 2006, Jan to 2014; Jun had been retrieved from the archive of

## Cryoglobulinemic glomerulonephritis associated with HBV infection

Department of pathology, Fujian DongFang Hospital, China. In a total of 34117 consecutive cases of renal biopsy, there were 1970 cases (5.77%) with hepatitis B virus markers (HBsAg or HBcAg) deposition, and 8 cases (0.023%) of HBV-GN with hyaline thrombi.

Clinical information and laboratory values were obtained by review of medical records, including sex, age, disease course (onset to renal biopsy time), clinical diagnosis, proteinuria (g/24 hours), microscopic hematuria (+, >10 red blood cells/HPF; 2+, >20 red blood cells/HPF; 3+, >30 red blood cells/HPF), serum creatinine (SCr) (normal range 53-124  $\mu\text{mol/L}$ ), blood urea nitrogen (BUN) (normal range 2.9-8.9  $\text{nmol/L}$ ), serum C3 (normal range 0.90~1.80 g/L), serum C4 (normal range 0.10-0.40 g/L), blood pressure (hypertension was defined as systolic pressure >140 mmHg or diastolic blood pressure >90 mmHg), HBV marks (HBsAg, HBeAg, anti-HBs, anti-HBe and anti-HBc), Serum cryoprecipitate (normal titer range 0-32 at 4°C, pathological titer is greater than or equal to 256 at 4°C).

With/without liver dysfunction, arthritis, myalgia or Raynaud's syndrome, bone marrow biopsies were performed in all patients. Follow up time was recorded from the time of discharge. Patient progressing to end-stage renal disease (ESRD) was defined as end point of study.

This study was approved by the Human Ethics Committee of The DongFang Provincial Hospital.

### Methods

All renal biopsy specimens were submitted for light microscopy examination. Specimens for light microscopy were fixed in 10% formaldehyde (formalin), embedded in paraffin and sections were cut at four microns and stained with hematoxylin and eosin (H&E), periodicacid-Schiff (PAS) and periodic acid-silver methenamine and Masson's trichrom (PAM-Masson).

The 3rd and 6th cases were submitted for electron microscopy examination.

Formalin-fixed, paraffin-embedded sections of the biopsied tissue were stained with primary antibody used for immunohistochemical study by the Elivision system, which were IgG (DAKO),

IgA (DAKO), IgM (DAKO), C3d (Abcam), C4d (Biomedica), C1q (DAKO), Fib (DAKO), CD68 (PGM-1) (EliVision), CD61 (EliVision), Ig $\kappa$  (DAKO), Ig $\lambda$  (DAKO), HBsAg (EliVision), anti-HBc (EliVision) and Apo E (DAKO). IgG, IgA, IgM, C3d, C1q, Fib, Ig $\kappa$  and Ig $\lambda$  were retrieved with high-pressure heating method in 0.01 mol/L pH6.0 citrate buffer and 0.4% gastric enzyme (Anresco) (9 minutes for IgG, Ig $\kappa$ , Ig $\lambda$  and C3d; 10 minutes for IgA, IgM and Fib [5]). HBsAg and HBcAb were retrieved with high-pressure heating method with 0.05% type-XXIV protease for 7 minutes). CD68 (PGM-1) and CD61 were retrieved with high-pressure heating method. Apo E was not retrieved. The remaining steps were performed according to the kit manual.

Evaluation for immunohistochemical results: A semiquantitative grading of the extent and intensity of all the antibodies staining was performed. A score of 0 to 3 was defined as follows: 0, no staining (negative); 1, less than 25% of arterioles stained (+, weak); 2, 25% to 50% arterioles stained (2+, moderate); 3, more than 50% arterioles stained (3+, strong). The total scores were scores of extent multiply by those of intensity.

### Results

#### *Clinical features (Table 1)*

There were 8 cases of HBV-GN in the study, including 6 male and 2 females (M:F = 3:1). The median age was 30.5 years (range, 21-75 years). All patients had proteinuria and microscopic hematuria to different extents. One patient had mild elevated BUN. The serum creatinine was normal in all the patients. Two patients had hypertension. The 3rd and 4th cases had chronic hepatitis B. Seven cases had arthralgia and myoalgia to different extents, One case had Raynaud's syndrome. Serum cryoglobulin testing was performed in 4 cases, 3 cases of which were positive (the titer is greater than 256). Serum C3 and serum C4 was detected in 5 cases: serum C3 decreased in 2 cases; serum C4 decreased in all detected cases. Serum HBsAg, HBeAg and anti-HBcAb were positive in all cases. Serum HCV antibody and Bence-Jones protein were negative in all cases. Bone marrow biopsies were negative for plasmacytosis or tumor involvement in all

## Cryoglobulinemic glomerulonephritis associated with HBV infection

**Table 1.** Clinical features of cases with HBV-GN with hyaline thrombi

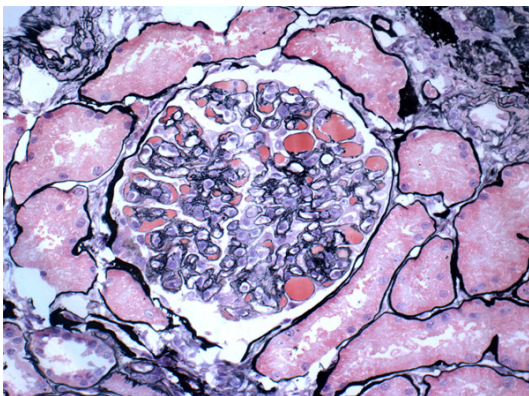
NO	Gender	Age	Disease course	Serum cryoprecipitate (>256)	Urine protein (g/24 hr)	Microscopic hematuria	SCr (umol/L)	BUN (mmol/L)	Hypertension	Serum C3 (g/L)	Serum C4 (g/L)	Liver dysfunction	Raynaud's syndrome	Follow up time (months)	ESRD
1	M	32	3 Months	positive	1.47	3+	69	5.39	No	-	-	No	No	Loss to follow up	-
2	M	29	2 Months	-	2.13	3+	75	5.77	No	-	-	No	No	Loss to follow up	-
3	F	35	2weeks	positive	1.07	1+	63	5.24	No	1.2	0.08	Yes	No	49	No
4	M	29	1 year	-	0.75	3+	86	3.33	No	0.56	0.07	Yes	No	40	No
5	M	21	2 years	negative	0.75	3+	82	5.56	No	1.2	0.04	No	No	39	No
6	F	25	4 months	-	0.61	2+	57	6.72	Yes	1.29	0.05	No	No	32	No
7	M	59	2 months	-	8.07	2+	79	4.34	No	-	-	No	No	23	No
8	M	75	6 months	positive	1.11	3+	81	9.76	Yes	0.41	0.03	No	Yes	13	Died

**Table 2.** Pathologic features of cases with HBV-GN with hyaline thrombi

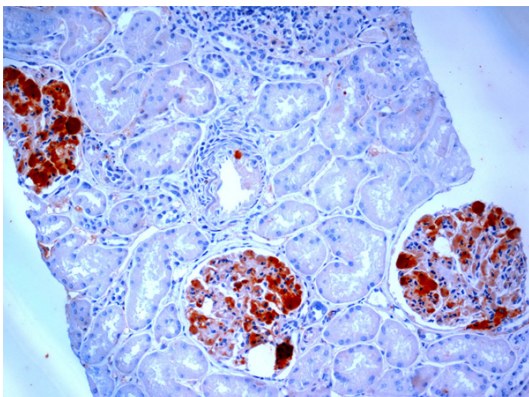
No.	Morphologic patterns	Immunohistochemical staining											
		IgG*	IgM*	IgA*	C3d*	C4d*	C1q*	Fib*	Igκ*	Igλ*	HBsAg*	HBcAg*	PGM-1**
1	Membranous nephropathy	9	4	1	9	9	4	0	2	2	4	1	0
2	Membranous nephropathy	4	1	0	6	9	1	0	1	1	4	4	1
3	Membranous nephropathy	6	4	1	9	9	0	1	2	2	4	4	0
4	Membranous nephropathy	2	4	0	9	9	1	4	1	1	4	4	2
5	Membranous nephropathy	9	1	1	9	9	2	4	1	1	4	0	1
6	Diffuse mesangial proliferative nephropathy with focal membranoproliferation	4	9	1	9	9	6	4	2	2	9	1	1
7	Membranous nephropathy	4	4	1	4	6	4	2	2	2	4	0	1
8	Diffuse mesangial proliferative nephropathy with focal membranoproliferation	1	9	1	6	6	2	4	1	2	1	1	3

\*Results of immunohistochemical staining were evaluated by total scores. \*\*CD68 (PGM1) was average numbers of macrophages within each glomerular capillary.

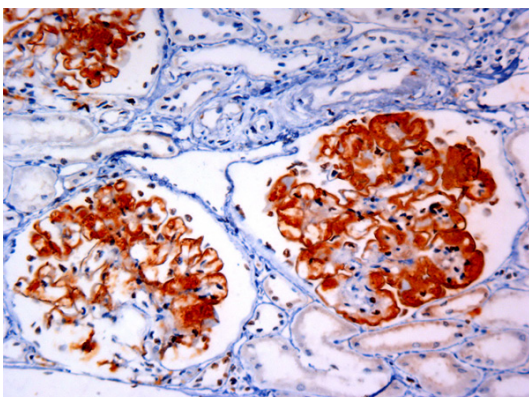
## Cryoglobulinemic glomerulonephritis associated with HBV infection



**Figure 1.** HBV-GN with hyaline thrombi, showed membranous nephropathy, with round or oval homogenous huge hyaline deposit in mesangial areas, and glomerular capillaries obliterated with hyaline thrombi occluded in capillary lumina (PASM-Masson  $\times 400$ ).



**Figure 2.** HBsAg deposit in mesangial areas and hyaline thrombi (EliVision  $\times 200$ ).



**Figure 3.** IgM deposit in mesangial areas, capillary loops and hyaline thrombi (EliVision  $\times 200$ ).

cases. SLE and IgM monoclonal gammopathy had also been ruled out.

### *Light microscopy*

Six cases exhibited diffuse membranous nephropathy and two cases exhibited diffuse mesangial proliferative nephropathy with focal membranoproliferation (**Table 2**). All cases showed round or oval homogenous huge hyaline deposit in mesangial areas, with hyaline thrombi occluded in capillary lumina. Hyaline thrombi deposit was stained purple with PAS and red with PASM-Masson (**Figure 1**). There were focal segmental or global glomerular sclerosis, tubular atrophy and interstitial fibrosis. Congo red staining was negative.

### *Immunohistochemical study*

Co-deposit of IgG, IgM, IgA, Fib, C3d, C4d, C1q, HBsAg and HBcAb were identified in mesangial area, capillary loops and hyaline deposit/hyaline thrombi (**Figures 2, 3**). There were 0-3 CD68 (PGM-1) positive macrophages within each glomerular. CD61 staining was negative. Staining for Ig $\kappa$  and Ig $\lambda$  showed polyclonal expression.

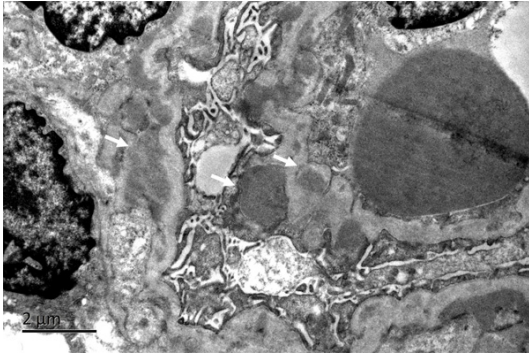
### *Electron microscopy*

Ultrastructural examination confirmed an increase in the mesangial cells and mesangial matrix with an influx of inflammatory cells. Glomerular capillary lumina were occluded partially or completely by huge electron-dense bodies, which was a homogeneous texture (**Figures 4, 5**). There was no organized structures such as microtubular, fiber-like, crystal or granular structure in electron dense deposits. GBM was segmental thickened with diffusely spike-like projection. Electron-dense deposits in subendothelial and subepithelial regions were common, with segmental mesangial cells and new basement membrane-like materials interposition into subendothelial space. Podocytes were diffusely effacement associated with microvillous transformation. Tubules were mild atrophy. And there was interstitial fibrosis with a variable number of lymphocytes and monocytes infiltrated.

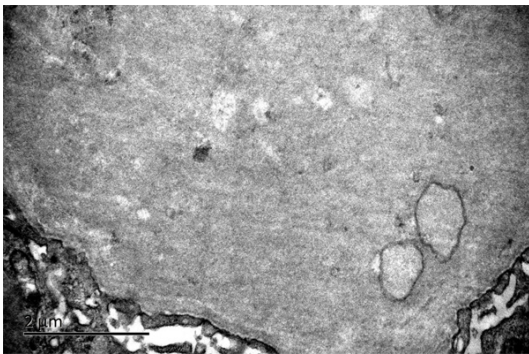
### *Therapy*

Treatment included steroids, antiviral therapy and traditional Chinese medial herbal therapy. With an average follow up of 20 months (range, 13-49 months), the patient with Raynaud's syndrome died, 2 patients lost to follow up. And the

## Cryoglobulinemic glomerulonephritis associated with HBV infection



**Figure 4.** Electron-dense deposits in subendothelial and subepithelial and mesangial areas (EM).



**Figure 5.** Glomerular capillary lumina were occluded partially or completely by huge electron-dense bodies, which was a homogeneous texture (EM).

other 5 patients had persistent proteinuria and urine occult blood. None of the patients developed renal dysfunction.

### Discussion

There are no available diagnostic criteria for mixed cryoglobulinemia; a new revised criterion, including clinico-pathological and virological findings, has been successively proposed [6]. Although serum cryoprecipitate positivity is essential in making diagnosis of cryoglobulinemia [6-8], cryoglobulin testing is underutilized in clinical practice in China. It has been neglected in clinical laboratories and by clinicians due to several factors, such as the length of time it takes for serum cryoglobulin analysis to be performed in the laboratory, the perceived difficulty in getting optimal sampling conditions and a failure to appreciate that even apparently low levels of cryoglobulin can be associated with severe symptoms in some patients [9, 10]. Even so cryoglobulin testing was performed in

4 cases of our series, and 3 cases had elevated cryocrit (>256), the negative case may associated with missing the best optimal time of blood cold agglutination. Moreover, clinical manifestations of all the cases were consistent with cryoglobulinemia [6-9], e.g. 1 case had Raynaud's syndrome, and 7 cases presented with arthralgia and myoalgia to different extents, and physicians highly suspected the symptoms related to cryoglobulinemia. Serum C4 decreased in all detected cases, which was accordance to cryoglobulinemia.

Fornasieri et al have reproduced an experimental model of cryoglobulinemic glomerulonephritis (CRYGN) in mice by injecting them with human IgMk-IgG cryoglobulins. Hyaline thrombi were detected in glomerular capillaries lumens, which were confirmed to be electron-dense deposits by electron microscopy, suggesting that the hyaline thrombi were mixed cryoglobulins [11]. All cases of the present series showed membranous nephropathy or membranoproliferative glomerulonephritis with capillary lumens occluded by hyaline thrombi. Immunohistochemical study showed deposit of prominent IgG/IgM and polyclonal deposit of Igκ and Igλ, which shared similar immunophenotype with mixed cryoglobulins. Electron microscopy examination of 2 cases confirmed hyaline thrombi were similar electron dense deposits to that produced in Fornasieri's study, which probably was deposit of mixed cryoglobulins.

Ultrastructural features of CRYGN varied greatly in literatures. Some specific organized structures have been identified by electron microscopy, such as microtubular, fiber-like, crystal and granular structure [12-14]. Faraggiana et al have reported the deposits of CRYGN in five cases displayed two main patterns; a homogeneous texture in two cases and tubular or annular structures in three cases [15]. The 2 cases of the present series submitted for electron microscopy examination showed huge electron dense deposit occluded in capillary lumens, which was also a homogeneous texture in our study. Thus the hyaline thrombi were suspected to be mixed cryoglobulins, when amyloidosis, fibrillary glomerulonephritis, immunotactoid glomerulopathy, collagenofibrotic glomerulopathy and fibronectin glomerulopathy were ruled out [13]. We believed that ultrastructural feature of a homogeneous texture occluded in capillary

## Cryoglobulinemic glomerulonephritis associated with HBV infection

lumens was essential ultrastructural features of CRYGN; while special organized structures were not necessarily identified.

Mixed cryoglobulinemia includes type II cryoglobulinemia and type III cryoglobulinemia [16]. Type II is characterized by polyclonal IgG and monoclonal IgM and type III by polyclonal IgG and IgM. Type II cryoglobulinemia is associated with hepatitis C virus infection. HCVs are detected in about 90% of patients with Type II cryoglobulinemia [17-19]. Mixed cryoglobulinemia may be associated with HBV infection [20-23], which may related to lymphoproliferative diseases developed from hepatitis B virus infection [24]. Hyaline thrombi in all the 8 cases of our series were staining for IgG/IgM, HBsAg and HBcAb, with polyclonal Igκ and Igλ deposit, suggesting the hyaline thrombi were mixed cryoglobulins associated with HBV infection. Fornasieri [11] et al studied the dynamic formation of immunodeposits in mixed cryoglobulins nephropathy, and found that the deposit expanded gradually from mesangial areas to subendothelial regions and capillary lumens. They speculated that hyaline thrombi result from in situ build-up of true huge endoluminal immunodeposits after saturation of the clearance capacity of the mesangium. So we speculated that HBV associated lymphoproliferation may contribute to CRYGN of the present series. Excessive immune complex form mixed cryoglobulins and accumulates in glomeruli, and deposit in mesangial areas, subendothelial and subepithelial regions subsequently, showing histopathologic patterns such as atypical membranous nephropathy or membranoproliferative glomerulonephritis, which might share a part of mechanism of HBV-GN.

HBV infection is prevalent in China. In the present study, there were 5.77% cases with HBV marks deposit in the retrospectively reviewed 34117 renal biopsy specimen. HBV-GN with hyaline thrombi accounted for 0.023%, suggesting that incidence of CRYGN associated HBV were extremely low.

As CRYGN associated HBV is extremely rare, and clinical manifestation is usually atypical, misdiagnosis is probably happened from time to time. Histopathologic diagnostic key point is hyaline thrombi with patterns of atypical membranous nephropathy or membranoproliferative glomerulonephritis by light microscopy, with capillary lumens occluded by hyaline

thrombi, which is confirmed to be electron dense deposit by electron microscopy, organized structure may be found. Serum cryoprecipitate positivity and decreased serum C4 are of great value, when CRYGN is suspected based on clinical manifestation. Therapy strategy is distinct from other nephritis. Non-steroidal anti-inflammatory drugs (NSAIDs) accompany with anti-viral treatment can be used in mild diseases. Plasmapheresis, corticosteroids and immunosuppressive treatment should be applied in typical cases [7]. Nucleoside/nucleotide analogues [26, 27] and entecavir used in cases with purpura and vasculitis have been reported recently [1, 2, 22].

The present series showed that CRYGN associated HBV has a male predominance, usually occurred in middle age. Seven of the 8 collected cases presented arthralgia, myoalgia, hematuria and proteinuria to different extents, slightly elevated BUN, decreased serum C4, without progressing ESRD. However the case with Raynaud's syndrome died, which might developed multi-organ failure caused by cryoglobulinemic vasculitis. Our series suggested that prognosis of CRYGN associated HBV is better in patients with mild symptoms, but it is poor in patients in old age with severe vasculitis.

### Acknowledgements

The authors thank all of their colleagues in their department who gave great help, especially technologists Zeng Ling, Li Min, and Liu Qinghong. This study was supported by a grant from the Nanjing Military Fuzhou General Hospital Research Fund 2010 and from Nanjing Military Medicine & Health Division Fund 08MA103.

### Disclosure of conflict of interest

None.

**Address correspondence to:** Dr. Zhi-Yong Zheng, Department of Pathology, Dongfang Hospital, 156 Xierhuanbei Road, Fuzhou 350025, Fujian, China. Tel: +86-591-83717703; Fax: +86-591-83717703; E-mail: l-morning@163.com

### References

- [1] Enomoto M, Nakanishi T, Ishii M, Tamori A, Kawada. N Entecavir to treat hepatitis B-associated cryoglobulinemic vasculitis. *Ann Intern Med* 2008; 149: 911-2.

## Cryoglobulinemic glomerulonephritis associated with HBV infection

- [2] D'Amico E, Pace-Palitti V, Di Lembo E, Palazzi C. Successful treatment of hepatitis B virus infection and related cryoglobulinaemic purpura with nucleoside/nucleotide analogues. *Clin Exp Rheumatol* 2013; 31: 155.
- [3] Vladareanu AM, Ciufu C, Neagu AM, Onisai M, Bumbea H, Vintilescu AM, Dobrea C, Arama V, Mihailescu R, Arama S. The impact of hepatitis viruses on chronic lymphoproliferative disorders-preliminary results. *J Med Life* 2010; 3: 320-9.
- [4] Bhimma R, Coovadia HM. Hepatitis B. virus-associated nephropathy. *Am J Nephrol* 2004; 24: 198-211.
- [5] Zhang R, Lin J, Qu L, Zheng F, Zheng Z. C3d deposition in the media of renal arterioles is a useful marker for arteriosclerosis in IgA nephropathy. *Ann Diagn Pathol* 2014; 18: 104-108.
- [6] Ferri C, Zignego AL, Pileri SA. Review. Cryoglobulins. *J Clin Pathol* 2002; 55: 4-13.
- [7] Takada S, Shimizu T, Hadano Y, Matsumoto K, Kataoka Y, Arima Y, Inoue T, Sorano S. Cryoglobulinemia. *Mol Med Rep* 2012; 6: 3-8.
- [8] Sargur R, White P, Egnor W. Cryoglobulin evaluation: best practice? *Ann Clin Biochem* 2010; 47: 8-16.
- [9] Mascia MT, Ferrari D, Campioli D, Sandri G, Mussini C, Ferri C. Non HCV-related mixed cryoglobulinemia. *Dig Liver Dis* 2007; 39: S61-S64.
- [10] Monti G, Saccardo F, Castelnovo L, Novati P, Sollima S, Riva A, Sarzi-Puttini P, Quartuccio L, De Vita S, Galli M. Prevalence of mixed cryoglobulinaemia syndrome and circulating cryoglobulins in a population-based survey: the Origgio study. *Autoimmun Rev* 2014; 13: 609-14.
- [11] Fornasieri A, Tazzari S, Li M, Armelloni S, Tarelli LT, Sessa A, D'Amico G. Electron microscopy study of genesis and dynamics of immunodeposition in IgMk-IgG cryoglobulin-induced glomerulonephritis in mice. *Am J Kidney Dis* 1998; 31: 435-42.
- [12] Ojemakinde K, Turbat-Herrera EA, Zeng X, Gu X, Herrera GA. The many faces of cryoglobulinemic nephropathy: a clinico-pathologic study of 47 cases with emphasis on the value of electron microscopy. *Ultrastruct Pathol* 2014; 38: 367-76.
- [13] Iskandar SS, Herrera GA. Glomerulopathies with organized deposits. *Semin Diagn Pathol* 2002; 19: 116-32.
- [14] Monga G, Mazzucco G, Casanova S, Boero R, Cagnoli L, Barbiano di Belgiojoso G, Confalonieri R. Ultrastructural glomerular findings in cryoglobulinemic glomerulonephritis. *Appl Pathol* 1987; 5: 108-15.
- [15] Faraggiana T, Parolini C, Previato G, Lupo A. Light and electron microscopic findings in five cases of cryoglobulinemic glomerulonephritis. *Virchows Arch A Pathol Anat Histol* 1979; 384: 29-44.
- [16] Della Rossa A, Marchi F, Catarsi E, Tavoni A, Bombardieri S. Mixed cryoglobulinemia and mortality: a review of the literature. *Clin Exp Rheum* 2008; 26: S105-S108.
- [17] Fabrizi F, Pozzi C, Farina M, Dattolo P, Lunghi G, Badalamenti S, Pagano A, Locatelli F. Hepatitis C virus infection and acute or chronic glomerulonephritis: an epidemiological and clinical appraisal. *Nephrol Dial Transplant* 1998; 13: 1991-7.
- [18] Agnello V, Chung RT, Kaplan LM. A role for hepatitis C virus infection in Type II cryoglobulinemia. *New Engl J Med* 1992; 327: 1490-1495.
- [19] Cacoub P, Fabiani FL, Musset L, Perrin M, Frangeul L, Leger JM, Hureau JM, Piette JC, Godeau P. Mixed cryoglobulinemia and hepatitis C virus. *Am J Med* 1994; 9: 124-132.
- [20] Yamazaki T, Akimoto T, Okuda K, Sugase T, Takeshima E, Numata A, Morishita Y, Iwazu Y, Yoshizawa H, Komada T, Iwazu K, Saito O, Takemoto F, Muto S, Kusano E. Purpura with ulcerative skin lesions and mixed cryoglobulinemia in a quiescent hepatitis B virus carrier. *Intern Med* 2014; 53: 115-9.
- [21] Löhr H, Goergen B, Weber W, Gödderz W, Meyer zum Büschenfelde KH, Gerken G. Mixed cryoglobulinemia type II in chronic hepatitis B associated with HBe-minus HBV mutant: cellular immune reactions and response to interferon treatment. *J Med Virol* 1994; 44: 330-335.
- [22] Levo Y, Gorevic PD, Kassab HJ, Zucker-Franklin D, Franklin EC. Association between hepatitis B virus and essential mixed cryoglobulinemia. *N Engl J Med* 1977; 296: 1501-1504.
- [23] Enríquez R, Sirvent AE, Andrada E, Escolano C, Rodríguez JC, Millán I, Gutiérrez F, Amorós F. Cryoglobulinemic glomerulonephritis in chronic hepatitis B infection. *Ren Fail* 2010; 32: 518-22.
- [24] Vladareanu AM, Ciufu C, Neagu AM, Onisai M, Bumbea H, Vintilescu AM, Dobrea C, Arama V, Mihailescu R, Arama S. The impact of hepatitis viruses on chronic lymphoproliferative disorders-preliminary results. *J Med Life* 2010; 3: 320-9.
- [25] Kawakami T, Ooka S, Mizoguchi M, Soma Y, Yamazaki M. Remission of hepatitis B virus-related cryoglobulinemic vasculitis with entecavir. *Ann Intern Med* 2008; 149: 911-912.
- [26] Enomoto M, Nakanishi T, Ishii M, Tamori A, Kawada N. Entecavir to treat hepatitis B-associated cryoglobulinemic vasculitis. *Ann Intern Med* 2008; 149: 912-3.
- [27] Viganò M, Martin P, Cappelletti M, Fabrizi F. HBV-associated cryoglobulinemic vasculitis: remission after antiviral therapy with entecavir. *Kidney Blood Press Res* 2014; 39: 65-73.