

Original Article

Adipositas cordis sudden death: a series of 79 patients

Yan-Hong Liang¹, Jun Zhu², Ding-Rong Zhong³, Dong-Yan Hou¹, Gui-Ling Ma¹, Zhi-Yong Zhang¹, Lin Zhang¹

¹Department of Cardiology, Heart Failure Center, Capital Medical University, Beijing Chao-Yang Hospital, Beijing, China; ²Department of Occupational Medicine and Toxicology, Capital Medical University, Beijing Chao-Yang Hospital, Beijing, China; ³Department of Pathology, Peking Union Medical College Hospital, Peking Union Medical College & Chinese Academy of Medical Sciences, Beijing, China

Received July 21, 2015; Accepted August 25, 2015; Epub September 1, 2015; Published September 15, 2015

Abstract: Background: The principal aim of this study was to investigate the clinical, epidemiological and pathologic features for a series of 79 cases of adipositas cordis sudden death. Methods: We analyzed clinical and autopsy pathological features of 79 patients (43 females and 36 males) with adipositas cordis who died suddenly between 1975 and 2010. Data were extracted from China National Knowledge Infrastructure and Wan Fang Database. Results: The average age of the 79 cases was 36.6±1.4 years old ranging from 13 to 68, and 82.3% of them were between 20 to 50 years old. Sudden death was the first symptom in 62 (78.5%) of the cases, only 17 (21.5%) had a history of chest distress or dyspnea. More than 4/5 (87.3%) of the cases had no any past medical history. At autopsy, the subjects' heart weight was mild or moderately increased, and a large amount of fatty tissues but not fibrous or fibro fatty was accumulated underneath the epicardium and infiltrated toward the right ventricle walls, and even infiltrated to all layers of the cardiac walls. Regional epidemiological data showed that about 80% of cases were living north and only 20% were living south of the Yangzi River, but not any familial heredity. Conclusion: Adipositas cordis sudden death is a very severe disease, it occurs mostly in youth and middle-aged and sudden death is often the first symptom. There is a significant regional difference, but not any genetic correlation. The pathogenesis of adipositas cordis sudden death should to be further explored.

Keywords: Sudden death, autopsy, arrhythmogenic right ventricular cardiomyopathy

Introduction

Adipositas cordis is associated with sudden death. There has been a remarkable unexplained increase in adipositas cordis sudden death around the world. It is worth noting that the vast majority of subjects do not have any clinical symptoms or obvious abnormalities on routine electrocardiogram and angiocardiography before sudden death happens [1, 2]. Adipositas cordis can be confirmed only by post-mortem examination [3, 4], but the cause of adipositas cordis was known very little so far.

In fact, a controversial diagnosis, about adipositas cordis, fatty infiltration of the right ventricle and arrhythmogenic right ventricular cardiomyopathy (ARVC), has been existing for a long time [5]. Back in 2005, Italy scholar put forward this question and thought that arrhythmogenic right ventricular cardiomyopathy should be kept distinct from both fatty infiltration of the right ven-

tricle and adipositas cordis, in order to avoid an over-diagnosis of ARVC [6].

There are two problems in the diagnosis of adipositas cordis: 1. There are no standard methods to pre-diagnose adipositas cordis even before sudden death; 2. Are Adipositas cordis and ARVC the same disease, or two completely different diseases? In order to better understand the adipositas cordis sudden death, we analyzed clinical symptoms, epidemiological data, familial heredity and pathological features for a sample of a large cohort of 79 cases with adipositas cordis sudden death, which were reviewed over 35 years.

Patients and methods

Patients

Between 1975 and 2010, 79 cases (43 females and 36 males) adipositas cordis sudden death

Adipositas cordis sudden death

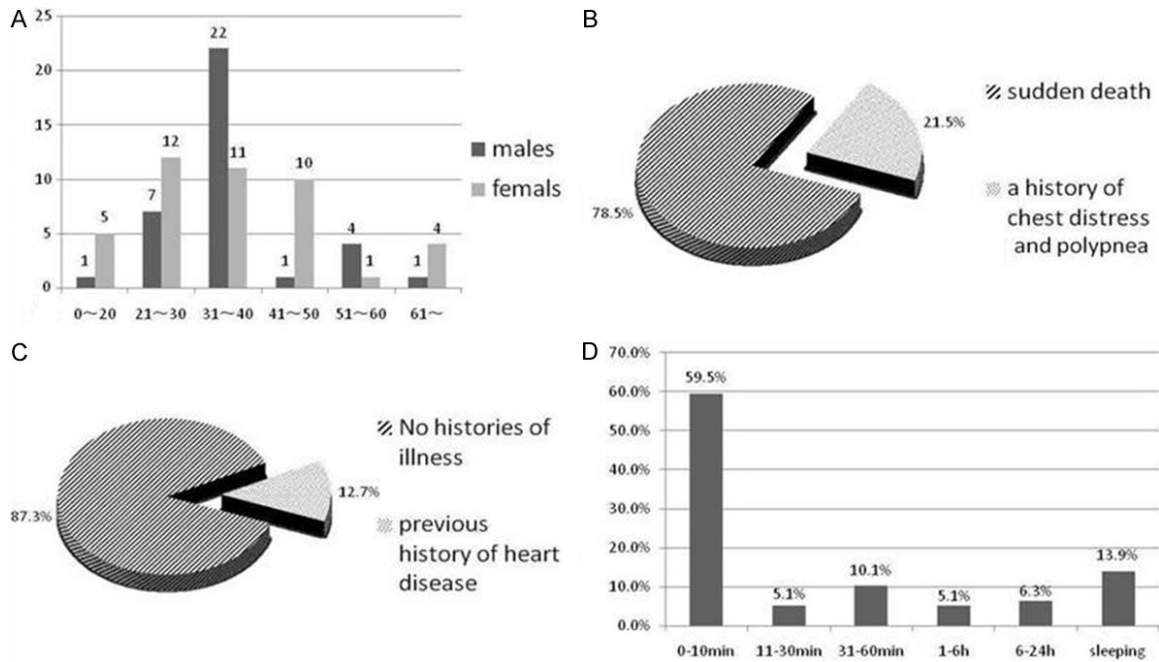


Figure 1. A. Age and gender distribution of affected individuals. The vast majority of cases (82.3%) were 20-50 years of age. 41.8% were 31-40 years of age. B. Accompanying symptoms. 78.5% (nearly 4/5) of cases had sudden death as the first symptom. Only 21.5% of cases presented with chest discomfort or dyspnea. C. Previous history of heart disease. 87.3% (more than 4/5) of the cases had no past medical history. Only 12.7% of cases had a history of cardiac disease. D. Time to death. 59.5% (nearly 3/5) of cases died within 10 minutes of onset of symptoms. 13.9% of cases died in their sleep.

were confirmed by autopsy. The patients were ranging in age between 13 and 68. The medical data were retrospectively obtained from case reports, including China National Knowledge Infrastructure and Wan Fang Database. Three key words, adipositas cordis, sudden death and post-mortem, were used to search for these case reports of the patients with adipositas cordis sudden death. We collected all the clinical presentation and genetic data, pathological data, and regional distribution of each patient.

The diagnostic criterion of adipositas cordis [7] was the inclusion criteria, which were mainly determined by pathological features: (1) A large amount of mature adipose tissues accumulated underneath the epicardium and infiltrated toward the left and right ventricle walls and even infiltrated to all layers of the cardiac walls; (2) There were varying degrees of dystrophy, breaking down and disappearance of the remaining heart muscle fibers, which have reached to the underneath of endocardium; (3) atrium cavities expended, atrioventricular valves and semilunar valves opened and formed a relatively incomplete close, the heart

looked like a globe in shape and the heart weight exceeded normal value; and (4) The patients may also have the associated atherosclerosis but have no coronary heart disease, hypertension, myocardial collagen or infected pathological changes. Case reports with no confirmed by pathological were exclusion.

This study was conducted in accordance with the declaration of Helsinki. The study was approved by the Medical Ethics Committee of the Capital Medical University Chao-Yang Hospital.

Clinical data

We analyzed age, sex, past medical history, provoking causes, accompanying symptoms, medical record before sudden death, family history, death time, geographic location and complications, and the autopsy report which included heart weight, pathological specimen of the heart. Even more, the microscopic appearance was also analyzed in detail. The fatty infiltration of the myocardium and the degrees of fatty filtration to cardiac muscles were observed.

Adipositas cordis sudden death

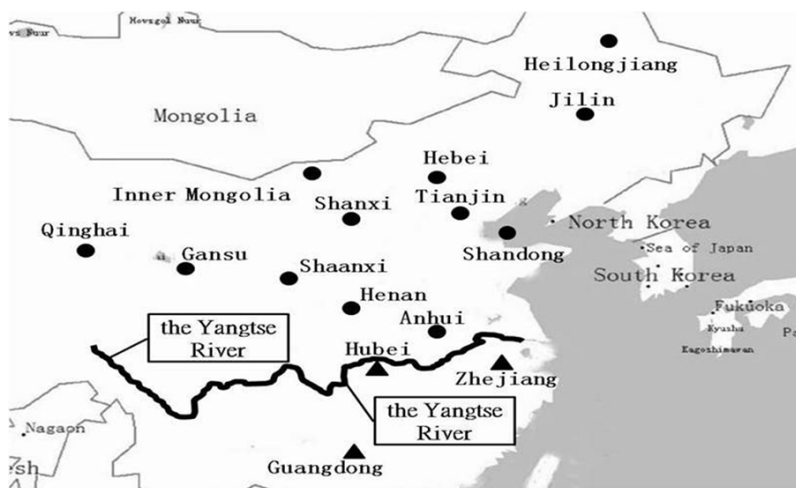

Figure 2. Geographic location of reported cases. Patients lived in 15 provincial-level administrative regions, including 12 northern provincial-level administrative regions and 3 southern provincial administrative regions. Cases involving the north, a total of 12 (12/15), Shaanxi, Hebei, Shanxi, Henan, Jilin, Inner Mongolia, Gansu, Heilongjiang, Qinghai, Anhui, Tianjin, Shandong. Relates to the south, a total of 3 (3/15), Hubei, Guangdong, Zhejiang. ● indicates provinces located North of the Yangzi river. ▲ indicates provinces located South of the Yangzi river.

Pathological data

Post-mortem was conducted for all the patients. At autopsy, all of 79 cases were verified adipositas cordis. Under the visualization with microscope, only a large amount of fatty tissues but not fibrous or fibrofatty had accumulated underneath the epicardium and infiltrated toward the right ventricle walls and even infiltrated to all layers of the cardiac walls.

Statistical analysis

The data were expressed as mean \pm standard error (SE) and categorical variables as numbers and percentages of the total. For group comparisons, chi-square test for categorical variables was used, and a two sided *P*-value of <0.05 was considered to be significant. These analyses were performed with SPSS 19.0 statistical software package.

Results

General data

Among the 79 cases with adipositas cordis sudden death, there were 36 males and 43 females ranging in age from 13 to 68 years (mean age: 36.6 ± 1.4 years). Sixty-five cases (82.3%) were

between 20 and 50 years. The distributions of age ranges and sexes were shown in **Figure 1A**.

Accompanying symptoms and previous medical histories

This disorder was not diagnosed or suspected before the subjects died. Sudden death was the first symptom in 62 (78.5%) of the cases. Only 17 (21.5%) had a history of chest distress or dyspnea. (**Figure 1B**). More than 4/5 (87.3%) of the cases had no past medical history, and only 12.7% had a history of previous cardiac disease (**Figure 1C**).

Family history

We found that these cases were sporadic, not only without any familial genetic, but also unrelated to each other. Otherwise, there had no familial occurrence and aggregation.

Death time

There were 47 (59.5%) of the patients died within 10 minutes and among them 42 (90%) didn't have any preceding signs or symptoms (**Figure 1D**). The average time to death after the first symptom in 79 cases was 1.4 ± 0.6 hours.

The complications

The complications of fatty liver and coronary atherosclerosis were not as serious as we expected. In all cases, only 9 cases (11.4%) had light fatty infiltration and 5 cases (6.3%) had very light of coronary atherosclerosis, most cases had no obvious complications.

Regional distribution

The reported cases were distributed among 15 provinces (or province-level municipalities) including Shaanxi, Hebei, Shanxi, Henan, Jilin, Yunnan, Inner Mongolia and Shandong, etc. Among which, 12 provinces (or province-level municipalities) were located in the North of

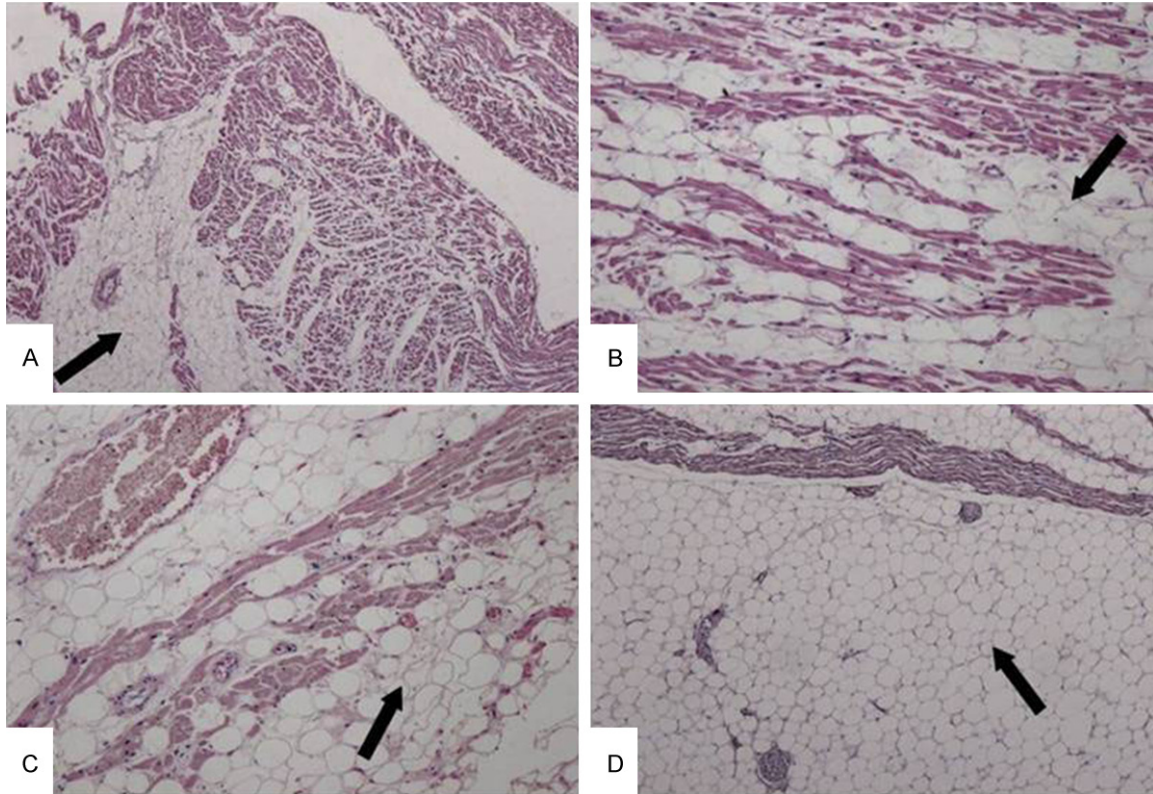


Figure 3. Major Pathological Changes. A. A large amount of mature adipose tissue without fibrous or fibrofatty components infiltrated the right ventricle near the ventricular cavity (H&E, 100×). B & C. Adipose tissue infiltrated the cardiac muscle interstices. There was atrophy of cardiac muscle fibers. Only a few atrophied muscle fibers remained. There was no striated cardiac muscle. (H&E, 400×). D. Transmural fatty infiltration of the right ventricular wall was seen. Myocardial tissue was almost completely replaced by adipose tissue in severe cases (H&E, 400×).

Yangzi river and 3 provinces were located in the South of Yangzi river. The rate of occurrence in the North of Yangzi River was significantly higher than the South side ($P=0.001$), as show in **Figure 2**.

Microscopic characteristics

Under the visualization with microscope, a large amount of mature adipose tissues without fibrous or fibrofatty had accumulated underneath the epicardium and infiltrated toward the right ventricle walls and even infiltrated to all layers of the cardiac walls.

There are varying degrees of dystrophy, breaking down and disappearance of the remaining heart muscle fibers, which have reached to the underneath of endocardium. The most pronounced change that occurs with fatty infiltration involves the right ventricle. The cardiac muscle fibers in the infiltrated sites basically shrank and disappear. Only a few shrank muscle fibers remain but the striated muscles have

disappeared. A few muscle fibers show compensatory hypertrophy or the fiber continuity are broken down, which are mainly characterized by the presence of a large amount of fatty tissues underneath the epicardium of the right ventricle, the fatty tissues have infiltrated to interspaces of cardiac muscle fibers and cardiac muscle fibers have shrunk in the sites where a large amount of fatty tissues have infiltrated (**Figure 3**).

Fatty infiltration of the myocardium

Post-mortem was conducted for all the patients. Among 79 cases whose heart size had been provided, the volume of 37 cases are increased, 4 cases are normal. In the specimens of heart, we can see the adipose tissues infiltrated to right ventricular, even infiltrated to all layers of the right ventricular walls. Among 79 cases, 39 cases (49.4%) fatty infiltrated into right ventricle, 31 cases (39.2%) fatty infiltrated into right ventricle and apex, 7 (8.9%) cases fatty infiltrated into right and left ventricle, 2 (2.5%)

Adipositas cordis sudden death

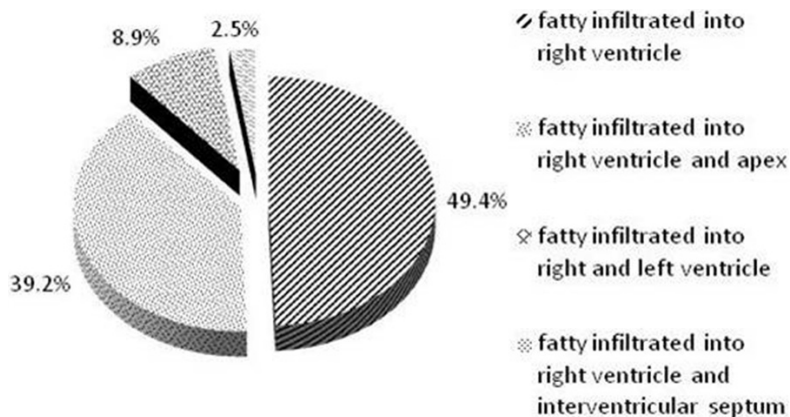


Figure 4. Fatty infiltration of the myocardium. All cases were characterized by the presence of a large amount of fatty tissue underneath the epicardium of the right ventricle. Thirty-nine cases (49.4%) had fatty infiltration of the right ventricle. Thirty-one cases (39.2%) had fatty infiltration of the right ventricle and apex of the heart. Seven cases (8.9%) had fatty infiltration of the right and left ventricle. Two cases (2.5%) had fatty infiltrated of the right ventricle and interventricular septum.

cases fatty infiltrated into right ventricle and interventricular septum (**Figure 4**).

Discussion

In this study, we reported a series of 79 patients with adipositas cordis sudden death, of which 82.3% were between 20 and 50 years, and 78.5% of cases died suddenly without any provoking factors and 13.9% of cases died during sleeping. All cases were sporadic, without any familial genetic, but there were obvious regional. Main pathological features were a large amount of fatty tissues but not fibrous or fibrofatty which was very different from ARVC that had accumulated underneath the epicardium and infiltrated toward the right ventricle walls and even infiltrated to all layers of the cardiac walls. Otherwise, these cases were not accompanied by fatty liver and coronary atherosclerosis.

What do we know about adipositas cordis? We know very little over history. It was an Italian investigator named Bronzini E [5] firstly proposed the concept of adipositas cordis in 1959. Thereafter, there were very few reports about adipositas cordis from the period of 1960 to 1995. Until 1996, Borkowski et al. [8] reported, a form of case-report, a case of patient whose left ventricle was broken and was latterly confirmed to be adipositas cordis by post-mortem. A majority of the subsequent reports also were case-reports [8-10] and there were very few systemically analyzed data. These characteris-

tics were consistent with those reported by Chinese investigators which were affirmed by our study.

Adiposity of the heart, also known as adipositas cordis, is usually an incidental finding at autopsy and is rarely thought to be of clinical significance [1]. In the early 1980s to 1990s, some researchers reported that patients with cardiac adiposity were usually obese and often had systemic hypertension and atherosclerotic heart disease [11, 12], but the viewpoint was controversial with the development of medicine.

The mechanisms underlying fatty infiltration to cardiac muscles have not been clearly understood. We know very little about adipositas cordis sudden death. As Cristina Basso stated [6]: adipositas cordis, fatty infiltration of right ventricle, and ARVC, just is a matter of fat? Some researchers thought that adipositas cordis and ARVC may be the same disease [13, 14].

ARVC is a genetic disease characterized by myocyte loss and fibrofatty tissue replacement [15]. It is an autosomal dominant hereditary heart disease. A familial history of ARVC is present in 30% to 50% of cases, and the disease is considered a genetic cardiomyopathy, usually inherited in an autosomal dominant pattern with variable penetrance and expressivity; in addition, autosomal recessive forms have been reported (Naxos disease and Carvajal syndrome) [14]. In our study, we find that adipositas cordis sudden death cases are sporadic and do not have any familial heredity. There are no familial occurrence and aggregation. However, there are 50%-70% ARVC cases haven't familial history. Are they overlapped with adipositas cordis or are they at the different stage of the same disease? It needs further to explore, and determine the diagnostic criteria.

ARVC is a myocardial disease characterized by partial or entire replacement of the myocardium of the right ventricular by fatty or fibro fatty tissue [6]. The lesions are mainly found among

the right ventricular myocardial fibers [16, 17]. While ARVC also has associated fatty infiltration of the right ventricle, it may be different from adipositas cordis. Two important histologic features of ARVC are significant fibrosis (replacement-type) and a degenerative change of the myocytes entrapped within areas of fibrous-fatty tissue. The fibrofatty variant is found in two-thirds of cases with inflammatory cell infiltrates and focal myocyte necrosis. These findings are compatible with a true myocarditis [16].

There are many reports of ARVC and few of adipositas cordis, especially adipositas cordis associated with sudden death. We don't identify a cause of adipositas cordis sudden death. In our study, it is more common than previous suggestion. Most cases occurred without any prior signs or symptoms, even death happen while sleeping. They were sporadic, without any familial genetic. Therefore, we speculate that adipositas cordis might be an independent disease.

Adipositas cordis sudden death is a very severe disease, it occurs mostly in youth and middle-aged and shows the characteristic of "sudden onset and sudden death". There is a significant regional difference, but not genetic correlated. The mechanisms and the cause underlying adipositas cordis sudden death are not clear currently, and more frequent than previous thoughts. We thought that adipositas cordis sudden death should be kept distinct from arrhythmogenic right ventricular cardiomyopathy, and should reach a consensus as soon as possible.

Acknowledgements

This project was supported by the Natural Science Foundation of China (81370340) and Beijing Natural Science Foundation (7142064).

Disclosure of conflict of interest

None.

Address correspondence to: Lin Zhang, Heart Failure Center, Department of Cardiology, Capital Medical University, Beijing Chao-Yang Hospital, No. 8 Gong-Ti South Road, Beijing, 100020, China; Beijing Key Laboratory of Metabolic Disorders Related Cardiovascular Diseases, Beijing, China. Tel: 86-10-85231066; Fax: 86-10-65951064; E-mail: linzhangdoc@yeah.net; Jun Zhu, Department

of Occupational Medicine and Toxicology, Capital Medical University, Beijing Chao-Yang Hospital, No. 8 Gong-Ti South Road, Beijing, 10020, China. E-mail: zhujunBeijingCY@sina.com

References

- [1] House AA, Walley VM. Right heart failure due to ventricular adiposity: 'adipositas cordis', an old diagnosis revisited. *Can J Cardiol* 1996; 12: 485-489.
- [2] Rowin EJ, Yucel KE, Salomon R, Maron MS. Adipositas Cordis, An uncommon cardiomyopathy identified by cardiovascular magnetic resonance. *Circulation* 2010; 10: 2212-2214.
- [3] Godínez-Valdez VH, Cázares-Campos I, Aranda-Fraustro A, López-Jiménez F, Cárdenas M, Márquez MF. Cardiac rupture in a patient with an acute myocardial infarction and extensive fatty infiltration of the heart ("adipositas cordis"). *Int J Cardiol* 2012; 154: e62-e64.
- [4] Barnard SP, Kitching PA, Kulatilake EN. Right ventricular rupture after coronary surgery. *Cardiovasc Surg* 1994; 2: 723-4.
- [5] Bronzini E, Novi AM. Anatomopathological contribution to the study of the fatty heart. (Study on 100 cases). *Arch Maragliano Patol Clin* 1959; 15: 1045-1069.
- [6] Basso C, Thiene G. Adipositas cordis, fatty infiltration of the right ventricle, and arrhythmogenic right ventricular cardiomyopathy. Just a matter of fat? *Cardiovasc Pathol* 2005; 14: 37-41.
- [7] Huang Y, Zhang L, Zhou LF. Post-mortem for three cases of patients with fatty heart-related sudden death. *Chinese Journal of Pathology* 2003; 32: 392-393.
- [8] Borkowski P, Cespedes E, Agatston AS, Robinson MJ. Left ventricle rupture through an area of fatty infiltration: case report and review of the literature. *Cardiovasc Pathol* 1996; 5: 85-88.
- [9] Krishnamani R, Nawgiri RS, Konstam MA, Warner KG, Salomon RN, DeNofrio D. Fatty infiltration Of right ventricle (adipositas cordis): an unrecognized cause of early graft failure after cardiac transplantation. *J Transplant* 2005; 24: 1143-1145.
- [10] Madala MC, Franklin BA, Chen AY, Berman AD, Roe MT, Peterson ED, Ohman EM, Smith SC Jr, Gibler WB, McCullough PA; CRUSADE Investigators. Obesity and age of first non-ST-segment elevation myocardial infarction. *J Am Coll Cardiol* 2008; 52: 979-85.
- [11] Roberts WC, Roberts JD. The floating heart or the heart too fat to sink: Analysis of 55 necropsy patients. *Am J Cardiol* 1983; 52: 1286-1289.
- [12] Shirani J, Roberts WC. Clinical, electrocardiographic and morphological features of massive

Adipositas cordis sudden death

- fatty deposits ('lipomatous hypertrophy') in the atrial septum. *JAMA* 1993; 22: 226-238.
- [13] Burke AP, Farb A, Tashko G, Virmani R. Arrhythmogenic Right Ventricular Cardiomyopathy and Fatty Replacement of the Right Ventricular Myocardium: Are They Different Diseases? *Circulation* 1998; 97: 1571-1580.
- [14] Fontaine G, Fontaliran F, Frank R. Arrhythmogenic Right Ventricular Cardiomyopathies: Clinical Forms and Main Differential Diagnoses. *Circulation* 1998; 97: 1532-1535.
- [15] Pinamonti B, Brun F, Mestroni L, Sinagra G. Arrhythmogenic right ventricular cardiomyopathy: From genetics to diagnostic and therapeutic challenges. *World J Cardiol* 2014; 6: 1234-1244.
- [16] Thiene G, Basso C. Arrhythmogenic right ventricular cardiomyopathy-An update. *Cardiovasc Pathol* 2001; 10: 109-117.
- [17] Roberts JD, Veinot JP, Rutberg J, Gollob MH. Inherited cardiomyopathies mimicking arrhythmogenic right ventricular cardiomyopathy. *Cardiovasc Pathol* 2010; 19: 316-320.