

## Case Report

# Rectal leiomyoma with multiple uterine myomas: report of a case

Yusheng Chen\*, Xiaobo Bo\*, Weidong Gao, Weizhong Sheng, Bo Zhang

Department of General Surgery, Zhongshan Hospital, Fudan University, Shanghai, China. \*Equal contributors and co-first authors.

Received December 19, 2015; Accepted April 5, 2016; Epub June 1, 2016; Published June 15, 2016

**Abstract:** Leiomyomas appearing in rectum are rare. It is rarer when rectal leiomyoma is complicated with multiple uterine myomas. Here we report a rectal leiomyoma complicated with multiple uterine myomas in a 47-year old woman. The patient presented with a mass and symptoms of constipation and rectal discomfort. After pre-operative preparation, then the patient underwent the treatment of completely surgical clearance of the tumor which was diagnosed before operation as a stromal tumor. Pathologic examination revealed the features of a leiomyoma with no malignancy. The patient was assigned to a continuous follow-up program and there was no recurrence in the 12 months following surgery.

**Keywords:** Leiomyoma, rectum, multiple uterine myomas

### Case report

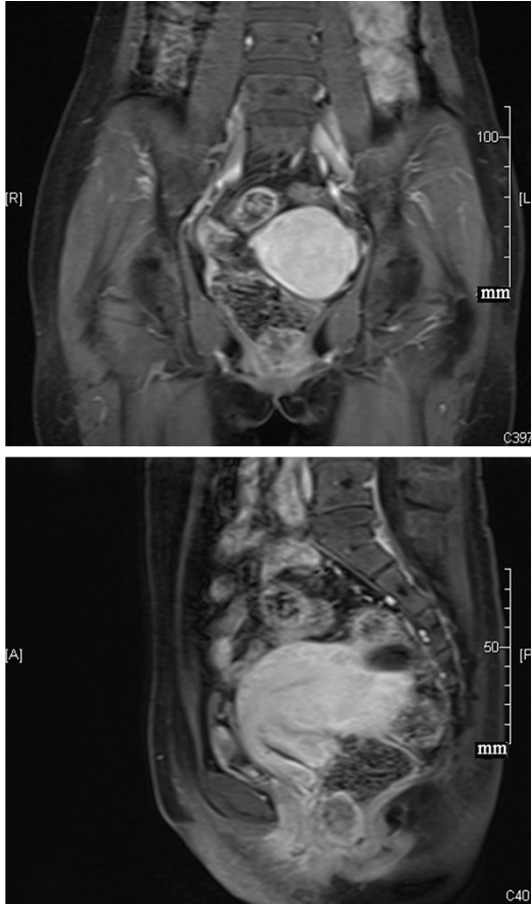
A 47-year-old hypertensive female was admitted to our hospital with a 2-year history of constipation and rectal discomfort. The patient had the change of character of stool in recent months. No family history of colorectal disease or inherited diseases was remarkable. Also, there were no remarkable findings in her blood test. Gynecological ultrasound suggested multiple uterine myomas. A subsequent flexible colonoscopy disclosed a 3 cm × 3 cm mobile mass in the anterior wall of the rectum, 2 cm above the anal verge, and the tumor was soft texture, with no ulceration at its top. The rest parts of the colon and rectum appeared normal. Then an enhanced pelvic Magnetic resonance image (MRI) was performed. The MRI suggested that a 2.6 × 2.7 × 2.1 cm mass lesion arising from anterior rectal wall near anal edge extending up to the enteric cavity, and the surface was smooth. Besides, there was no evidence of tumor infiltration in the rectal wall. It also showed multiple uterine myomas, the larger of which was 5.3 × 5.5 cm (**Figure 1**). A tentative diagnosis of gastrointestinal stromal tumors was therefore made. After pre-operative preparation, a transanal tumor incision was made under general anesthesia. The tumor

was then integrally dissected. Macroscopic and histological analysis revealed features of a benign leiomyoma (**Figure 2**). Based on the opinions of the patients, we did not have the surgery of uterine myomas. The patient was released from hospital on the third postoperative day. There was no recurrence in the 12 months following surgery.

### Discussion

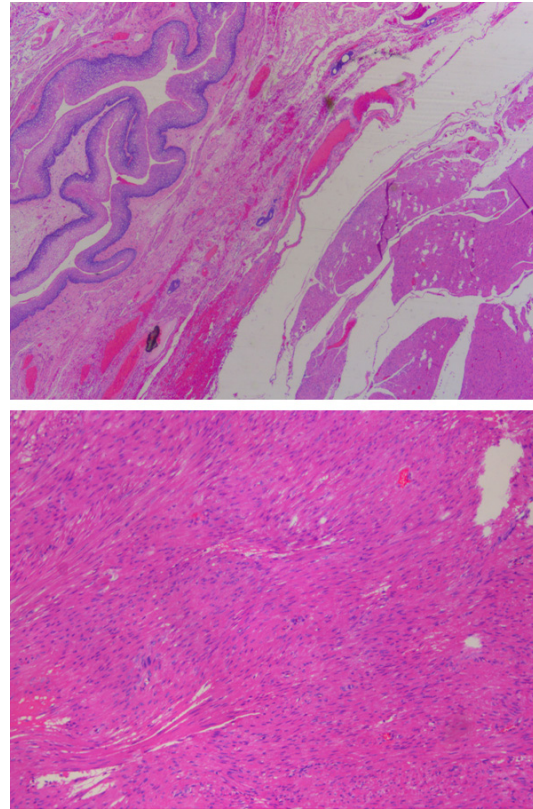
Leiomyomas appearing in rectum are rare [1, 2]. Leiomyoma of the anorectal region represent 3% of all gastrointestinal leiomyoma, and less than 0.1% of rectal tumors [2-5]. The rectal leiomyomas have been reported in previous literature. But it is rarest when rectal leiomyoma occurs with multiple uterine myomas. Reviews by Hatch et al. [6] revealed that anorectal leiomyomas predominately occur between 40 and 59 years of age with a significant male predominance (71%). The patient of our case was a 47-year old female. Patients suffering from rectal leiomyomas often remain asymptomatic until the mass reached a large size. The most common symptoms when patients suffering from rectal leiomyomas are bleeding, palpable mass, and obstruction [6]. Our patient experienced 2-year history of constipation and rectal

## Rectal leiomyoma with multiple uterine myomas



**Figure 1.** Magnetic resonance showing a rectal mass with multiple uterine myomas.

discomfort with no bleeding. Besides, she also had a half-year history of irregular menstruation due to the existence of multiple uterine myomas. Rectal leiomyomas often remain intramural [7]. Our case presented here had tumors in the anterior wall of the rectum, 2 cm above the anal verge. The preoperative gynecological ultrasound and the enhanced pelvic MRI showed the mass in the rectal and multiple uterine myomas. It also offers the relationships between the mass and the anorectum, helping us choose the best surgical procedure. Then at the time of the operation, the tumor mass was easily found, dissected, and excised. Since it is rare when rectal leiomyoma occurs with multiple uterine myomas, there is lack of reliable relationship between rectal leiomyoma and the uterine myomas. Until now, surgery is the only effective way to treat rectum leiomyoma. Therefore, we choose the treatment of completely surgical clearance of the rectal tumor. We sug-



**Figure 2.** Histological section of the rectal mass.

gested that the patient should undergo gynecological surgical procedure in future. Since the patient had tumor with no gross or histological features of malignancy, her management through a local excision was considered adequate. Even if histological analysis revealed features of a benign leiomyoma, there is still the possibility of local recurrence or local malignant change in the future. She was assigned to a follow-up program.

In conclusion, this patient demonstrated a rare case of rectal leiomyoma with multiple uterine myomas. Besides, there was no evidence of residual leiomyoma or recurrence 12 months after surgery

### Disclosure of conflict of interest

None.

**Address correspondence to:** Bo Zhang, Department of General Surgery, Zhongshan Hospital, Fudan University, Shanghai, China. E-mail: zhangbozsy@163.com

## Rectal leiomyoma with multiple uterine myomas

### References

- [1] Simmang CL, Reed K and Rosenthal D. Leiomyomas of the gastrointestinal tract. *Mil Med* 1989; 154: 45-7.
- [2] Tran T, Davila JA and El-Serag HB. The epidemiology of malignant gastrointestinal stromal tumors: an analysis of 1,458 cases from 1992 to 2000. *Am J Gastroenterol* 2005; 100: 162-8.
- [3] Bruneton JN, Drouillard J, Roux P, Lecomte P and Tavernier J. Leiomyoma and leiomyosarcoma of the digestive tract—a report of 45 cases and review of the literature. *Eur J Radiol* 1981; 1: 291-300.
- [4] De Palma GD, Rega M, Masone S, Siciliano S, Persico M, Salvatori F, Maione F, Esposito D, Bellino A and Persico G. Lower gastrointestinal bleeding secondary to a rectal leiomyoma. *World J Gastroenterol* 2009; 15: 1769-70.
- [5] Saunders RN, Pattenden C and Agarawal PK. Heavy rectal bleeding secondary to the passage of a rectal leiomyoma per anus. *Ann R Coll Surg Engl* 2004; 86: W44-6.
- [6] Hatch KF, Blanchard DK, Hatch GF, Wertheimer-Hatch L, Davis GB, Foster RS and Skandalakis JE. Tumors of the rectum and anal canal. *World J Surg* 2000; 24: 437-43.
- [7] Miettinen M, Kopczynski J, Makhlof HR, Sarlomo-Rikala, M, Gyorffy H, Burke A, Sobin LH and Lasota J. Gastrointestinal stromal tumors, intramural leiomyomas, and leiomyosarcomas in the rectum and anus: a clinicopathologic, immunohistochemical, and molecular genetic study of 144 cases. *Am J Surg Pathol* 2001; 25: 1121-33.