

Case Report

An ALK-positive NSCLC patient with the G1202R mutation detected by next-generation sequencing

Katsuhiko Yoshimura^{1,2}, Shiro Imokawa³, Yusuke Inoue^{1,2}, Ippei Ohnishi^{2,4}, Tomoaki Kahyo², Shioto Suzuki⁴, Toshihide Ueno⁵, Fumihiko Tanioka⁴, Manabu Soda⁵, Takafumi Suda¹, Hiroyuki Mano⁵, Haruhiko Sugimura²

¹Second Division, Department of Internal Medicine, Hamamatsu University School of Medicine, Hamamatsu, Japan; ²Department of Tumor Pathology, Hamamatsu University School of Medicine, Hamamatsu, Japan; ³Division of Respiratory Medicine, Iwata City Hospital, Iwata, Japan; ⁴Division of Pathology, Iwata City Hospital, Iwata, Japan; ⁵Department of Cellular Signaling, Graduate School of Medicine, The University of Tokyo, Japan

Received January 21, 2016; Accepted April 18, 2016; Epub June 1, 2016; Published June 15, 2016

Abstract: Anaplastic lymphoma kinase (ALK) tyrosine kinase inhibitors are currently essential drugs in the treatment of the subset of patients with non-small-cell lung cancer (NSCLC) showing ALK rearrangement. Notwithstanding, even the response to ALK inhibitors is usually not sustained in these patients, because of the occurrence of secondary mutations in ALK, MET amplification, or other unknown alterations. Herein, we report the case of a 70-year-old Japanese woman who was diagnosed as having advanced adenocarcinoma of the lung with ALK rearrangement. Treatment with crizotinib as well as with pemetrexed yielded good responses initially, however, the disease eventually progressed. Then, treatment with alectinib, a second-generation ALK inhibitor, was initiated, which yielded a dramatic response, which was sustained approximately for two months. When the disease progressed again, we re-challenged the patient with pemetrexed again, which resulted in marked tumor shrinkage, however, the tumor eventually recurred again. At autopsy, tumors were found in the lung, hilar lymph nodes, spleen, pleura and peritoneum, and examination of the lung tumor tissue obtained at autopsy by next-generation sequencing (NGS) revealed G1202R substitution, a secondary ALK mutation. Our experience emphasizes the importance of repeated genomic analyses of the tumor tissue at several time-points during the course of time, including after death, to explain intractable cancer progression under molecular-targeted therapy. An important lesson from this case is that the timing of treatment with regimens including molecular-target agents and other conventional therapies must be chosen taking into account the underlying molecular events in the tumors.

Keywords: ALK G1202R, alectinib, resistance, ALK-positive NSCLC, next-generation sequencing

Introduction

The EML4-ALK (echinoderm microtubule-associated protein-like 4-anaplastic lymphoma kinase) fusion gene is one of the genetic abnormalities observed in non-small cell lung cancer (NSCLC) [1]. Crizotinib, an ALK tyrosine kinase inhibitor (TKI), and alectinib, a second-generation ALK TKI, have been shown to be effective in most cases of ALK-positive NSCLC [2], however, some cases become resistant to these TKIs over the course of time, and the mechanisms underlying such resistance have only partially been elucidated. Recently, we used the second-generation ALK inhibitor, alectinib, in a patient who developed crizotinib resistance. The duration of the response to alectinib

was, however, limited, and the patient died due to cancer progression. Autopsy was conducted, and next-generation sequencing was applied to a tumor specimen obtained at autopsy to determine the cause of the drug resistance, which revealed the G1202R mutation of ALK.

Case report

The patient was a 70-year-old Japanese female never-smoker who was diagnosed as having Stage IV adenocarcinoma in April 2012 (**Figure 1A**). Magnetic resonance imaging of the brain at that time revealed multiple brain metastases, therefore, whole-brain radiotherapy was started (30 Gy in 10 fractions). Mutational analysis of the tumor revealed expression of the

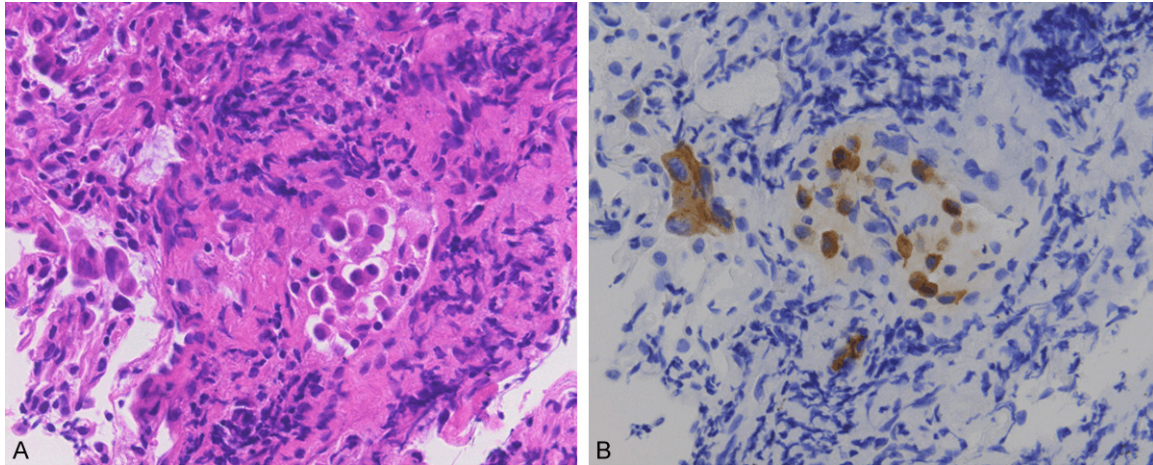


Figure 1. Tumor histology of transbronchial biopsy. A. Hematoxylin-eosin staining at 40x magnification shows features consistent with the lung adenocarcinoma. B. Immunohistochemistry for ALK shows a positive result.

wild type of epidermal growth receptor factor (EGFR). Therefore, the patient was initially treated with four cycles of carboplatin/pemetrexed/bevacizumab followed by four cycles of maintenance bevacizumab, according to the available guideline at that time, from April 2012 to October 2012, however, disease progression was detected in November 2012 (**Figure 2A**). At around the same time, since the use of ALK inhibitors in clinical practice had begun to be covered by the national health insurance system in Japan [3], additional testing for ALK rearrangement was performed, in the hope of identifying another drug suitable for treating our patient. Fluorescence in situ hybridization assay of the tumor tissue for identifying ALK rearrangement revealed indeterminate results, however, immunohistochemical analysis revealed positive staining for ALK expression (**Figure 1B**). Thus, treatment with crizotinib was initiated, and the patient showed dramatic response after the first 3 months of crizotinib treatment, which lasted for an additional 5 months. However, since crizotinib needed to be discontinued from April 2013 to July 2013 because the patient developed appetite loss as an adverse effect of the drug, the primary lesion in the left lower lobe (LLL) gradually grew. Hence, we administered two cycles of docetaxel, however, the tumor grew rapidly, accompanied by the development of pleural effusion. We resumed the crizotinib treatment in August 2013. The patient showed good response again, and the pleural effusion diminished in size. Thereafter, the tumor lesion remained sta-

ble for nine months. Although the LLL lesion gradually began to grow again from May 2014, the crizotinib treatment was continued, because of the ongoing clinical benefit in that the patient remained asymptomatic. Over the next four months, the LLL lesions continued to grow. Based on the diagnosis of crizotinib resistance, we considered using alectinib, which had just become available in the market in Japan. We initiated alectinib at the dose of 600 mg orally twice daily in September 2014. A good response was obtained after two weeks (**Figure 2B**). However, after two months of treatment, the disease began to progress rapidly again. In December 2014, the patient was administered pemetrexed again, and the tumor shrank markedly (**Figure 2B**). However, pemetrexed was stopped after only one cycle because of the development of an anaphylactic reaction. Thereafter, the performance status of the patient worsened progressively, so that all anti-cancer drugs were withdrawn and the patient was provided with best supportive care. She died in March 2015, and an autopsy was done with the consent of the patient's family.

Tumor tissues were obtained at autopsy and kept frozen, and the specimens were submitted along with the formalin-fixed, paraffin-embedded tissue specimens obtained at the time of diagnosis to the Department of Cellular Signaling, the University of Tokyo. Whole-exome sequencing of the resected tumor as well as the spleen (as a paired normal) with a next-generation sequencer (NGS) (HiSeq 2500, Illumina)

Alectinib-resistant mutation G1202R by NGS

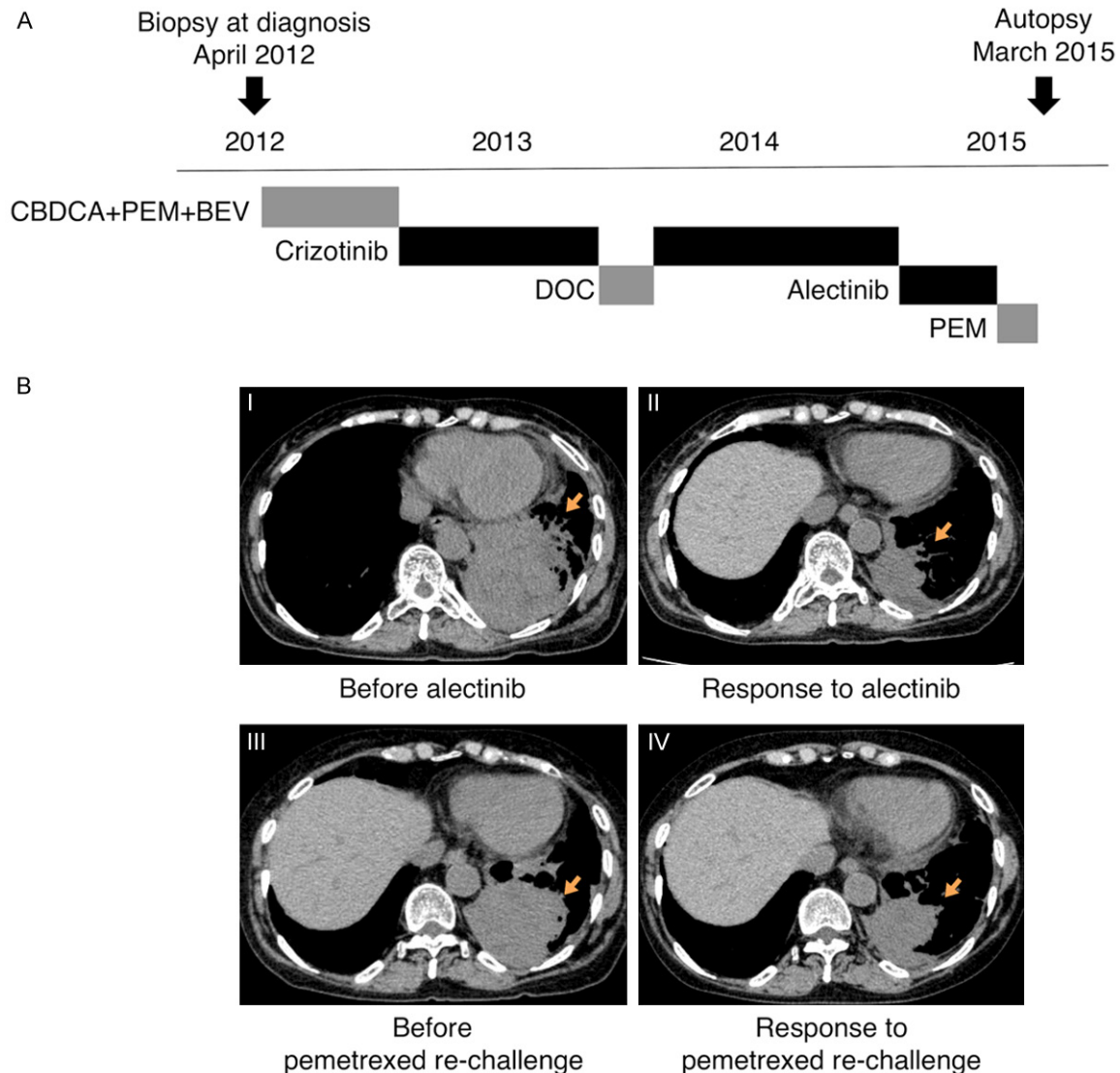


Figure 2. Clinical course. A. Treatment course. B. Chest CT findings. I, II: Before and after alectinib. III, IV: Before and after pemetrexed re-challenge. CBDCA: carboplatin, PEM: pemetrexed, BEV: bevacizumab, DOC: docetaxel.

revealed the presence of a somatic, non-synonymous mutation within ALK (G1202R) (Figure 3). We could not conduct NGS analysis of the biopsy specimen obtained at the first diagnosis because of an insufficient amount of tissue. Since the G1202R substitution of ALK has been reported to produce resistance to ALK inhibitors such as alectinib, we considered that the resistance to alectinib in this case was due to the G1202R mutation.

Discussion

Herein, we report the case of an ALK-positive NSCLC patient with the EML4-ALK (G1202R) mutation in the tumor, which caused resistance

to alectinib. Alectinib is one of the second-generation ALK inhibitors, and is a highly selective inhibitor, with activity against the L1196M and G1269A mutations. It yields a good tumor response even after failure of crizotinib. Although ALK-positive lung cancer responds well to alectinib, it is said that the disease often progresses because of acquired resistance [4, 5].

Several mechanisms of resistance to ALK inhibitors have been reported [4]. In one-third of the resistant cases, the lung cancers acquire secondary mutations within the ALK tyrosine kinase domain. Not only L1196M and G1269A, but also G1202R, are recognized as acquired mutations. Another mechanism of resistance

Alectinib-resistant mutation G1202R by NGS




Figure 3. Sequence reads mapped to the ALK locus. Sequence reads obtained from the tumor (lower panel) or paired normal tissue (upper panel) were aligned to the ALK locus (encoded by the minus strand) corresponding to the glycine¹²⁰² of its protein product using the Integrative Genomics Viewer (<https://www.broadinstitute.org/igv/>). Note that approximately 44% of the reads contain T (shown red) instead of the wild-type nucleotide C, thus changing the codon for arginine from “GGA” to “AGA”.

involves amplification of the ALK fusion genes and activation of alternative signaling pathways, such as the EGFR, KIT, MET and insulin-like growth factor 1 receptor pathways [5].

The G1202R mutation is located in the active site of ALK, facing the drug binding pocket, and corresponds to the BCR-ABL G321W mutation [6]. G1202R has been demonstrated in vitro to confer a high level of resistance to all other ALK inhibitors in current clinical use [4]. To date, several cases with secondary resistance associated with G1202R have been reported [4, 7, 8]. One patient was initiated on treatment with alectinib, like in our case [7]. In another patient,

the G1202R mutation occurred during treatment with ceritinib, another second-generation ALK inhibitor [8]. In the clinical setting, G1202R is so far recognized as a highly recalcitrant mutation. Recently, PF-06463922, a potent and selective ROS1/ALK inhibitor, was shown to be effective against tumors with a number of ALK-resistant mutations, including G1202R [9, 10]. This drug is now in the spotlight for overcoming acquired resistance, and a clinical trial is under way (NCT01970865).

Interestingly, we observed a dramatic response after pemetrexed re-challenge in our present case. Re-challenge with pemetrexed has been

attempted in a patient with lung adenocarcinoma harboring an EGFR (L858R) mutation after the patient developed resistance to erlotinib [11]. In addition, as for ALK-positive NSCLC, some retrospective studies have suggested that adding pemetrexed to crizotinib is beneficial in terms of the progression-free survival and objective response [12, 13]. Other prospective studies have also demonstrated that ALK-positive patients treated with pemetrexed showed better objective responses than those treated with docetaxel [14]. ALK-positive NSCLC is intrinsically more sensitive to pemetrexed, because of the low RNA levels of thymidylate synthase usually present in ALK-positive NSCLC [13, 15]. Thus, there is a relationship between ALK positivity and the efficacy to pemetrexed, and pemetrexed is another crucial drug in the treatment of ALK-positive lung cancer. Moreover, after the disease gradually progressed in our patient, we continued crizotinib administration, which may have contributed to prolonging her survival. A recent retrospective investigation has demonstrated that continuing crizotinib treatment even beyond RECIST-defined disease progression is beneficial in patients with advanced ALK-positive NSCLC [16].

One of the limitations of the present analysis was that re-biopsy was not performed after the appearance of crizotinib resistance in our patient, therefore, we could not determine the exact chronology of the emergence of the G1202R mutation. However, considering the initial good response to alectinib, it is reasonable to assume that the G1202R mutation occurred concurrently with the emergence of alectinib resistance.

Further investigation is warranted to clarify and develop a means to overcome the resistance to alectinib. Genomic analyses of re-biopsy specimens at appropriate timings may be expected to provide useful clues to our understanding of tumor behaviors in clinical settings. Our experience in the utilization of both molecular-targeted agents and chemotherapeutic agents such as alectinib and pemetrexed suggests that attention to the timing of administration, bearing in mind the underlying molecular events in the tumor cells, is of critical importance—especially among patients with ALK-positive NSCLC.

Acknowledgements

This work was supported in part by grants-in-aids from the Ministry of Education, Culture,

Science, Sports and Technology, AMED, SRF, PTCRF, and National Cancer Center Research and Development Fund.

Disclosure of conflict of interest

None.

Address correspondence to: Dr. Haruhiko Sugimura, Department of Tumor Pathology, Hamamatsu University School of Medicine, 1-20-1 Handayama Higashi-ku, Shizuoka 431-3129, Hamamatsu, Japan. Tel: +81-53-435-2220; Fax: +81-53-435-2225; E-mail: hsugimur@hama-med.ac.jp

References

- [1] Soda M, Choi YL, Enomoto M, Takada S, Yamashita Y, Ishikawa S, Fujiwara S, Watanabe H, Kurashina K, Hatanaka H, Bando M, Ohno S, Ishikawa Y, Aburatani H, Niki T, Sohara Y, Sugiyama Y and Mano H. Identification of the transforming EML4-ALK fusion gene in non-small-cell lung cancer. *Nature* 2007; 448: 561-566.
- [2] Kwak EL, Bang YJ, Camidge DR, Shaw AT, Solomon B, Maki RG, Ou SH, Dezube BJ, Janne PA, Costa DB, Varella-Garcia M, Kim WH, Lynch TJ, Fidias P, Stubbs H, Engelman JA, Sequist LV, Tan W, Gandhi L, Mino-Kenudson M, Wei GC, Shreeve SM, Ratain MJ, Settleman J, Christensen JG, Haber DA, Wilner K, Salgia R, Shapiro GI, Clark JW and Iafrate AJ. Anaplastic lymphoma kinase inhibition in non-small-cell lung cancer. *N Engl J Med* 2010; 363: 1693-1703.
- [3] Ministry of Health, Labor and Welfare (MHLW) of Japan. Central Social Medical Insurance Council (Chuijkyo), SOU-3 [updated 2014 26-Aug, cited 2015 Nov-10]. Available from: <http://www.mhlw.go.jp/topics/2014/03/tp-0305-01.html>.
- [4] Katayama R, Shaw AT, Khan TM, Mino-Kenudson M, Solomon BJ, Halmos B, Jessop NA, Wain JC, Yeo AT, Benes C, Drew L, Saeh JC, Crosby K, Sequist LV, Iafrate AJ and Engelman JA. Mechanisms of acquired crizotinib resistance in ALK-rearranged lung Cancers. *Sci Transl Med* 2012; 4: 120ra117.
- [5] Isozaki H, Takigawa N and Kiura K. Mechanisms of Acquired Resistance to ALK Inhibitors and the Rationale for Treating ALK-positive Lung Cancer. *Cancers (Basel)* 2015; 7: 763-783.
- [6] Fontana D, Ceccon M, Gambacorti-Passerini C and Mologni L. Activity of second-generation ALK inhibitors against crizotinib-resistant mutants in an NPM-ALK model compared to EML4-ALK. *Cancer Med* 2015; 4: 953-965.
- [7] Ignatius Ou SH, Azada M, Hsiang DJ, Herman JM, Kain TS, Siwak-Tapp C, Casey C, He J,

Alectinib-resistant mutation G1202R by NGS

- Ali SM, Klempner SJ and Miller VA. Next-generation sequencing reveals a Novel NSCLC ALK F1174V mutation and confirms ALK G1202R mutation confers high-level resistance to alectinib (CH5424802/RO5424802) in ALK-rearranged NSCLC patients who progressed on crizotinib. *J Thorac Oncol* 2014; 9: 549-553.
- [8] Friboulet L, Li N, Katayama R, Lee CC, Gainor JF, Crystal AS, Michellys PY, Awad MM, Yanagitani N, Kim S, Pferdekamper AC, Li J, Kasibhatla S, Sun F, Sun X, Hua S, McNamara P, Mahmood S, Lockerman EL, Fujita N, Nishio M, Harris JL, Shaw AT and Engelman JA. The ALK inhibitor ceritinib overcomes crizotinib resistance in non-small cell lung cancer. *Cancer Discov* 2014; 4: 662-673.
- [9] Zou HY, Friboulet L, Kodack DP, Engstrom LD, Li Q, West M, Tang RW, Wang H, Tsaparikos K, Wang J, Timofeevski S, Katayama R, Dinh DM, Lam H, Lam JL, Yamazaki S, Hu W, Patel B, Bezwada D, Frias RL, Lifshits E, Mahmood S, Gainor JF, Affolter T, Lappin PB, Gukasyan H, Lee N, Deng S, Jain RK, Johnson TW, Shaw AT, Fantin VR and Smeal T. PF-06463922, an ALK/ROS1 Inhibitor, Overcomes Resistance to First and Second Generation ALK Inhibitors in Preclinical Models. *Cancer Cell* 2015; 28: 70-81.
- [10] Johnson TW, Richardson PF, Bailey S, Brooun A, Burke BJ, Collins MR, Cui JJ, Deal JG, Deng YL, Dinh D, Engstrom LD, He M, Hoffman J, Hoffman RL, Huang Q, Kania RS, Kath JC, Lam H, Lam JL, Le PT, Lingardo L, Liu W, McTigue M, Palmer CL, Sach NW, Smeal T, Smith GL, Stewart AE, Timofeevski S, Zhu H, Zhu J, Zou HY and Edwards MP. Discovery of (10R)-7-amino-12-fluoro-2,10,16-trimethyl-15-oxo-10,15,16,17-tetrahydro-2H-8,4-(m etheno)pyrazolo[4,3-h][2,5,11]-benzoxadiazacyclotetradecine-3-carbonitrile (PF-06463922), a macrocyclic inhibitor of anaplastic lymphoma kinase (ALK) and c-ros oncogene 1 (ROS1) with pre-clinical brain exposure and broad-spectrum potency against ALK-resistant mutations. *J Med Chem* 2014; 57: 4720-4744.
- [11] Li S, Zhou F, Ren S and Zhou C. Response to pemetrexed rechallenge after acquired resistance of EGFR-TKI in a patient with advanced NSCLC. *Lung Cancer* 2014; 84: 203-205.
- [12] Camidge DR, Kono SA, Lu X, Okuyama S, Baron AE, Oton AB, Davies AM, Varella-Garcia M, Franklin W and Doebele RC. Anaplastic lymphoma kinase gene rearrangements in non-small cell lung cancer are associated with prolonged progression-free survival on pemetrexed. *J Thorac Oncol* 2011; 6: 774-780.
- [13] Lee JO, Kim TM, Lee SH, Kim DW, Kim S, Jeon YK, Chung DH, Kim WH, Kim YT, Yang SC, Kim YW, Heo DS and Bang YJ. Anaplastic lymphoma kinase translocation: a predictive biomarker of pemetrexed in patients with non-small cell lung cancer. *J Thorac Oncol* 2011; 6: 1474-1480.
- [14] Shaw AT, Kim DW, Nakagawa K, Seto T, Crino L, Ahn MJ, De Pas T, Besse B, Solomon BJ, Blackhall F, Wu YL, Thomas M, O'Byrne KJ, Moro-Sibilot D, Camidge DR, Mok T, Hirsh V, Riely GJ, Iyer S, Tassell V, Polli A, Wilner KD and Janne PA. Crizotinib versus chemotherapy in advanced ALK-positive lung cancer. *N Engl J Med* 2013; 368: 2385-2394.
- [15] Takezawa K, Okamoto I, Okamoto W, Takeda M, Sakai K, Tsukioka S, Kuwata K, Yamaguchi H, Nishio K and Nakagawa K. Thymidylate synthase as a determinant of pemetrexed sensitivity in non-small cell lung cancer. *Br J Cancer* 2011; 104: 1594-1601.
- [16] Ou SH, Janne PA, Bartlett CH, Tang Y, Kim DW, Otterson GA, Crino L, Selaru P, Cohen DP, Clark JW and Riely GJ. Clinical benefit of continuing ALK inhibition with crizotinib beyond initial disease progression in patients with advanced ALK-positive NSCLC. *Ann Oncol* 2014; 25: 415-422.