

Original Article

Efficacy of three different therapies for cesarean scar pregnancy

Liming Guan

Department of Obstetrics and Gynaecology, Zhabei District Central Hospital, No. 619, Zhonghuaxin Road, Zhabei District, Shanghai 200000, China

Received May 5, 2016; Accepted November 29, 2016; Epub February 1, 2017; Published February 15, 2017

Abstract: Background: There are many reports involving efficacy of caesarean scar pregnancy (CSP) treatment, there are still some controversial issues: whether uterine curettage can be carried out after medical treatment, whether laparotomic excision causes patients harm seriously than other methods. Purpose: To evaluate the effects of three methods for CSP treatment. Methods: In this study, a total of 39 women with CSP were assigned to 3 groups, patients in group 1 were administrated methotrexate (MTX) and mifepristone followed by uterine curettage under hysteroscope guidance; patients in group 2 underwent uterine artery embolization (UAE) followed by uterine curettage; patients in group 3 underwent laparotomic resection. Results: The hospital cost in group 1 was the lowest, while the time for normalization of serum β -hCG and hospital stay time were longest among three groups. Intraoperative blood loss of patients in group 2 were the least and success rates were the highest, while hospital cost were relatively higher among three groups. In group 1 group 2, pathology of uterine clean showed pregnant trophoblastic tissues become necrosis tissues. Laparotomy in group 3 showed uterine tissues in scar were fragile and easy bleeding. Hospital stay time and time for normalization of serum β -hCG in group 3 were the shortest among three groups, while hospital cost, blood loss during operation were in the middle of three groups. The most common side effects after patients administration of MTX were anorexia or mild nausea. Patients in group 2 and group 3 appeared mild postoperative complications such as wound pain, fever, increase of blood white cell could be successfully controlled. Conclusion: Among the three methods for CSP treatment, UAE followed by uterine curettage is safer and more effective therapy, hospital cost is relatively higher. If serum β -hCG values are not too high, the sick can adopt the option of enough dose of medical treatment followed by uterine curettage under firmly monitored, medical treatment can make pregnant trophoblastic tissues become necrosis tissues and lost invasive ability, which can greatly reduced blood loss of uterine curettage, hospital cost is low, but a patient may take longer time in hospital and turn to other therapy methods for treatment failure. Laparotomic resection can remove the uterine scar tissues, repair the uterine defect, the operation relatively is easy to be performed without causing too harm to patients. This research was allowed by the ethics committee of Zhabei district central hospital. Trial registration number: 2015-016.

Keywords: Cesarean scar pregnancy (CSP), uterine artery embolization (UAE), uterine curettage, human chorionic gonadotropin (hCG), methotrexate (MTX)

Introduction

Caesarean scar pregnancy (CSP) is an unusual form of ectopic implantation, which is induced by imbedded pregnant tissue into uterine cesarean scar. Since the pregnant tissue imbedded site is fragile and easy bleeding. Woman with CSP are confronted with risks of uterine rupture, massive bleeding, even life-threatening and loss of fertility [1, 2].

In China, the CSP can be encountered with more frequently in recent years, it was report-

ed, rates of CSP were 36.2/100,000 in 2010, for cesarean delivery rate was over 50% in all childbirth. So a rise in the number of cesarean delivery is the epidemiological reason. The principal physiopathologic factors are that cesarean operations disrupt endometrium and myometrium, cause scar tissue formation [3].

Many literatures reported their strategies of CSP treatment had good curative effect. But there have been no universal standard guides for the CSP treatment now. It is recommended medical treatment methotrexate (MTX) followed

Different methods for CSP treatment

by uterine curettage or uterine artery embolization (UAE) followed by uterine curettage as criterion therapy. But other scholars suggest uterine curettage should not be considered as a therapeutic option, because of the risk of massive bleeding. Some other scholars believe that laparotomic resection is the best choice for the CSP treatment. So there are still some controversial issues, whether uterine curettage can be carried out after medical treatment, whether laparotomic excision causes patients harm seriously than other methods [3-5].

In this study, the effects of the CSP treated by three different options were compared, one method underwent medical treatment (MTX + mifepristone) followed by uterine curettage, one method underwent UAE followed by uterine curettage, and the third method underwent laparotomic resection.

Materials and methods

39 women diagnosed as CSP in Zhabei district central hospital hospitalized from January 2011 to March 2015 were enrolled in this study.

The inclusion criteria were as following: (1) An experience of cesarean childbirth; (2) A short time of menelipsis and serum β -hCG rises above normal level; (3) Diagnosis standards of ultrasonography were according to references [5, 6]: a. Pregnant tissue not found within cavity of uterus and the cervix; b. The pregnant tissue was embedded at the front wall close to the cervix; c. Short of or a flaw in the myometrium between the bladder and the pregnant tissue. All patients in this study were diagnosed as CSP by transvaginal ultrasound.

The research was ratified by the ethics committee of Zhabei district central hospital, and all patients agreed to attend to the research and filled in the written agreement. Conflict interest did not exist. Trial registration number: 2015-016. All patients in the research were well-informed of the benefits, clinical efficacy, potential hazards, the treatment costs, uncertain factors related to conservative treatment and risk of laparotomic resection.

All of the patients were assigned into 3 groups, the patients in group 1 were received medical treatment followed by uterine clean; patients in group 2 were performed UAE followed by uter-

ine clean; patients in group 3 were performed laparotomic resection.

The patients in group 1 and group 2 included patients demanded specified method for treatment; patients in group 1 serum β -hCG <5.000 mIU/ml.

The patients in group 3 included serum β -hCG >30.000 mIU/ml or patients asked for laparotomic resection directly; the patients of group 1, group 2 treatment failed; or patients in emergency condition.

The women in group 1 were administrated MTX (MTX, intramuscular injection 50 mg in 1 day, 3 days, 5 days) and mifepristone (mifepristone, orally 25 mg 2 dose per day for a week) followed by uterine clean. The serum β -hCG value were detected every three days, if serum β -hCG values decline was dissatisfied, then patients would be administrated next course of treatment at 7 days later. When serum β -HCG value decline to within 100 U/L, the patients underwent uterine curettage firmly guidance by hysteroscope. The patients were followed up until first menstruation initiated.

13 patients in group 2 underwent uterine artery embolization (UAE) followed by uterine clean.

Uterine artery embolization underwent by local anesthesia with 1% lidocaine within inguinal region. X-ray angiography of two side arteria iliaca interna was performed through right-sided femoral artery. When the head-end of the catheter was inserted into uterine artery of patient, X-ray angiography was performed by the contrast agent iopamidol, MTX was injected into uterine artery at dose of 50 mg/m² separated on equal terms in the both side uterine arteries. Absorbable genlatin sponge mixed with iopamidol was infused into two side uterine arteries till the major uterine artery blood flow was stopped by deposit of iopamidol.

Uterine clean underwent 2 days after uterine artery embolization.

13 patients in group 3 underwent laparotomy resection under combined spinal epidural anesthesia.

Patients in group 3 underwent similar surgical operation steps. This included dissection of the peritoneum between the bladder and the uter-

Different methods for CSP treatment

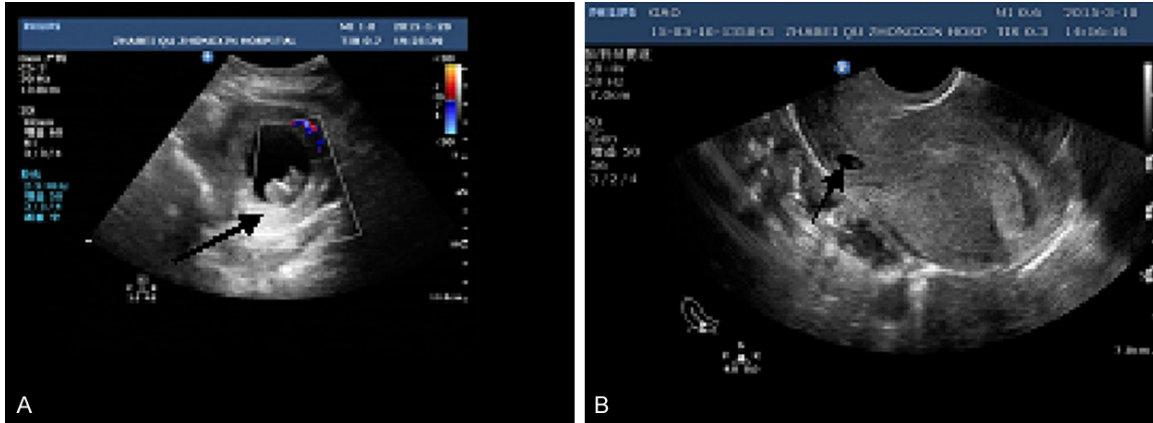


Figure 1. A. Ultrasonography showed the gestational sac implanted in the scar that grew toward the urinary bladder (arrow indicated). B. Ultrasonography showed the gestational sac implanted in the scar that grew toward the uterine cavity (arrow indicated).

us, pushing the bladder downwards, ligation of ascending branches of uterine arteries, excision of the whole gestation sac in scar, repairing the defect of uterus as well as the peritoneum

Laparotomic exploration often showed former cesarean scar rough, brittle and adhered with bladder firmly. The residual myometrium were weak or interruptive. Intrauterine pregnant tissues were faintly visible through thin serosal layer covered. If there was local adhesions, adhesiolysis was performed; the bladder was pushed downward appropriately to avoid both bladder injury. The whole cervicoisthmic region containing the gestation sac was exposed. The next step was to resect the pregnant tissue in uterine scar and clean residual pregnant tissues in uterine cavity completely. The uterine incision was sutured in three layers. The internal two layers were closed interrupted by 1-0 absorptive surgical sutures (Polysorb CL-923; Covidien, Ltd) through uterine full-thickness, and the outside peritoneum was sutured incessantly by the same suture material.

A succeeding treatment was regarded as a patient with CSP fully recovered without severe complications and uterus preserved.

Intraoperative blood loss, operation time, hospital stay time, hospital cost, serum β -hCG value, and postoperative complication were recorded.

Operation time in group 1 was duration of dilatation and curettage (D&C), operation time in

group 2 was duration of uterine artery embolization (UAE) + period of D&C, operation time in group 3 was duration of surgical operation.

Statistical methods

The quantitative variables (such as hemoglobin) in the study were displayed by mean \pm SD, one-way analysis of variance (ANOVA) was used to analyze the variance in different groups. Qualitative variables (such as distribution of patients age, size of pregnancy mass, and pregnant history) were presented as percentage (%), chi-square test were used to calculate the efficacy of different treatment methods. The data was calculated by statistical analysis software (GraphPad Software, Inc., USA). Confidence intervals of 95% were regarded as statistically significant. The significance level was set at p less than 0.05.

Follows-up

Serum β -HCG was detected per week till to normal level. Patients were followed up 3 to 6 months. The first return of the menstrual cycle was recorded. Vaginal ultrasound screening was carried out to determine if there were residual pregnant tissues within the former uterine scar tissues. The patients were advised to adopt an appropriate method for contraception at least one year.

Results

The data of 39 patients with CSP from Zhabei district central hospital from January 2011 to

Different methods for CSP treatment

Table 1. General information of patients with cesarean scar pregnancy

	Group 1 (n=13)	Group 2 (n=13)	Group 3 (n=13)	F/ χ^2	P value
Age (y)				$\chi^2=2.280$	0.684
≤ 30	3 (23.1)	4 (30.8)	3 (23.1)		
31-40	8 (61.5)	9 (69.2)	8 (61.5)		
>40	2 (15.4)	0 (0)	2 (15.4)		
Cesarean history (n)	1-2	1-2	1-2	$\chi^2=0.00$	1.000
Menolipsis	10 (76.9)	9 (69.2)	9 (69.2)	$\chi^2=253$	0.881
Irregular vaginal bleeding (%)	4 (30.8)	3 (23.1)	4 (30.8)	$\chi^2=253$	0.881
Abdominal pain	1 (7.7)	1 (7.7)	2 (23.1)	$\chi^2=1.835$	0.399
Serum β -hCG (mIU/ml)				$\chi^2=0.465$	0.916
$\leq 10,000$	11 (84.6)	10 (76.9)	10 (76.9)		
10,001-30,000	1(7.7)	2 (15.4)	2 (15.4)		
$>30,000$	1 (7.7)	1 (7.7)	1 (7.7)		
Size of mass (cm)				$\chi^2=1.08$	0.916
≤ 1	1 (7.7)	0 (0)	1 (7.7)		
2-3	8 (61.5)	9 (69.2)	8 (61.5)		
>3	4 (30.8)	4 (30.8)	4 (30.8)		
Thickness of uterine scar (mm)				$\chi^2=0.958$	0.916
≤ 0.5	1 (7.7)	2 (15.4)	2 (15.4)		
0.6-1	2 (15.4)	3 (23.1)	3 (23.1)		
>1	10 (76.9)	8 (61.5)	8 (61.5)		
Hemoglobin (g/L)*	123.38 \pm 16.47	112.92 \pm 15.67	120.92 \pm 13.66	F (2, 36)=1.940	0.1584

*Data of hemoglobin were presented as mean \pm SD and data were analyzed by one-way ANOVA. The rest data were presented as count (%), and data were used two-sided χ^2 test analysis. F: degrees of freedom.

March 2015 were enrolled in this study. All of 39 patients met the requirement for CSP inclusion criteria, ultrasonography showed the gestational sac imbedded in the front wall of uterine cavity near the cervix. According to the gestational sac implantation site visualizing by ultrasound imagine, it was divided into two types, the gestational sac that protrude toward abdominal cavity even invade the urinary bladder, the gestational sac that grew toward the uterine cavity.

The gestational sac that grew toward the urinary bladder included 16 patients, 12 of them in group 3 and 4 of them in group 2 (**Figure 1A**). The gestational sac that grew toward the uterine cavity including 23 patients, 13 of them in group 1 and 9 of them in group 2, 1 of them in group 3 (**Figure 1B**).

General characteristics of patients with CSP were showed in **Table 1**. The mean maternal age of all registered patients was 33.0 years (range: 25 to 43 years), 23 patients had underwent one cesarean operations and 16 patients had underwent two cesarean operations. The

average gestational age at diagnosis was 53.0 days (range: 35 to 89 days), the initiative preoperative β -HCG level was 256-35, 690 mIU/ml.

According to two-sided χ^2 test analysis, it was not found statistical significances in distribution of patients age, size of pregnant tissues, pregnant history, and serum β -hCG level among the patients in three groups ($P>0.05$). According to one-way ANOVA analysis, it was found no statistical significant different in patients hemoglobin among three groups ($P>0.05$).

13 women in group 1 underwent medical treatment, then serum β -hCG changes were detected every 3 days, if serum β -hCG dropped less than 25%, or elevated, the patients would be given second course of treatment 7 days later. The average β -HCG level was 8,153.26 \pm 2115.33 IU/L (from 1960 to 31,335 IU/L).The maximum numbers of medical treatment courses in group 1 were 3. The longest time that patients β -HCG reached negative values was about a month. See **Table 1**. This included: 7 patients were given 3 courses of medical treat-

Different methods for CSP treatment

Table 2. Intraoperative information, main outcomes of patients with cesarean scar pregnancy

	Group 1 (n=13)	Group 2 (n=13)	Group 3 (n=13)	F (2, 36)	P value
Blood loss in operation (ml)*	153.27±60.24	66.44±15.97	92.11±25.40	8.212	0.0012
Operation time, Min. *	15.77±0.93	52.15±1.29	50.31±2.09	2375	0.0001
Treatment success rate (%)**	10 (76.9)	13 (100)	12 (92.3)	$\chi^2=78.000$	0.000
hCG fall normal level time (d)*	34.31±5.28	21.60±2.29	19.62±2.90	66.10	0.0001
Postoperative fever rate (>38.0°C) (%)**	1 (7.7)	9 (69.2)	3 (23.1)	$\chi^2=12.00$	0.002
WBC, N rise rate (%)**	1 (7.7)	7 (53.8)	6 (46.2)*	$\chi^2=6.909$	0.032
Wound pain rate (%)**	0 (0)	2 (15.4)	6 (46.2)	$\chi^2=8.8006$	0.012
Hospital cost, RMBYuan*	4826.62±241.57	13253.87±1084.02	8468.46±629.42	427.7	0.0001
Hospital stay (d)*	30.38±3.52	12.31±1.55	7.69±1.18	343.7	0.0001
Postoperative first menstrual time days*	23.69±2.14	25.54±3.55	24.92±4.48	1.482	0.2407

*Data were presented as mean ± SD and data were analyzed by one-way ANOVA. **Data were presented as count (%), and data were used two-sided χ^2 test analysis. WBC: white blood count, N: neutrophil. F: degrees of freedom.

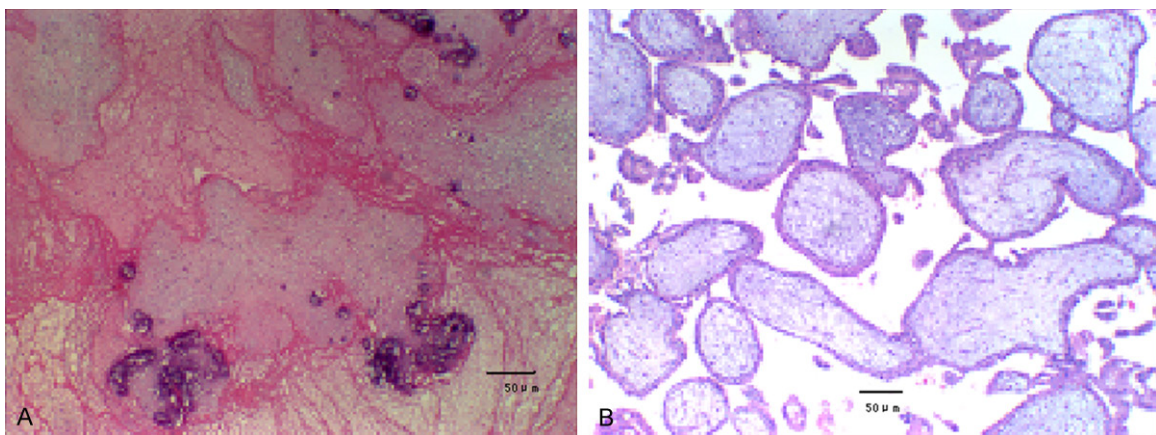


Figure 2. A. Patients with cesarean scar pregnancy underwent medical treatment followed by uterine curettage, postoperative pathology showed degenerative necrosis trophoblastic tissue with calcification, 100×. B. Patients with cesarean scar pregnancy underwent uterine artery embolization followed by uterine curettage, postoperative pathology of curettage showed degenerative chorionic villi tissue, 100×.

ment. 4 patients were given 2 courses of medical treatment. The other 2 patients underwent laparotomic excision after 2 courses medical treatment failed.

3 patients in group 1 received suction curettage under ultrasonic guidance because of incomplete abortion. The average blood loss of these 3 patients was 95.5 ml (range: 80-135 ml). Because of heavy vaginal bleeding, so curettage monitoring method was used ultrasonic guidance to replace hysteroscopic guidance. See **Table 2**.

The rest of eight patients in group 1 received uterine curettage under hysteroscope guidance when serum β -HCG value declined within 100 U/L, hysteroscope could directly determine the pregnancy tissue location and visualize whole

procedure of separating the pregnant tissues from uterine wall. The pregnant tissues were successfully removed with one curettage among seven patients. The mean hemorrhage amount of these nine patients reached 153.5 ml (range: 90 to 210 ml).

Patients in group 1 adopted pharmacologic treatment followed by uterine curettage, postoperative pathology of uterine curettage showed degenerative necrosis trophoblastic tissue with calcification (**Figure 2A**).

One of them, one patient encountered massive blood loss during uterine curettage, an emergency uterine artery embolization was performed, vaginal bleeding stopped and ultrasonic monitored curettage was performed second time. The patients was received blood transfu-

Different methods for CSP treatment

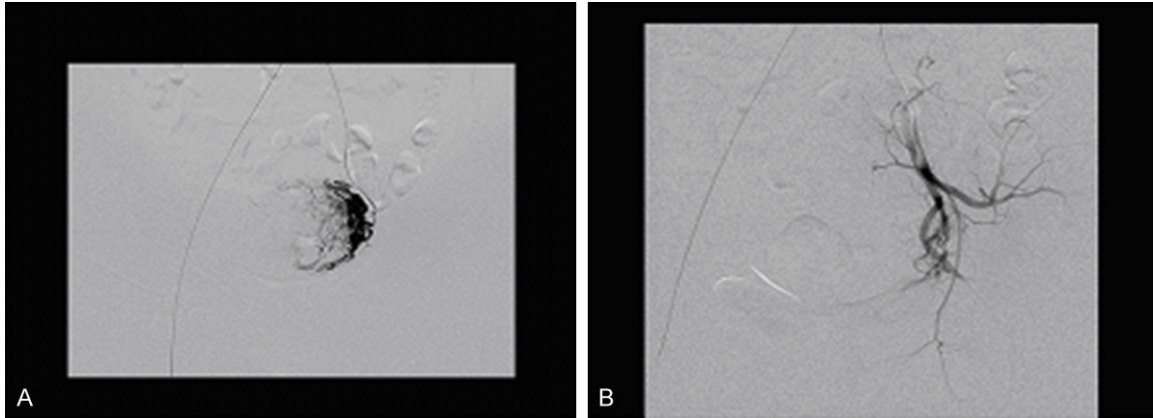


Figure 3. A. X-ray DSA of the uterine artery, arterial phase showed enlarging filling artery by absorbable genlatin sponge. B. After the embolization of uterine artery, x-ray DSA found uterine vascular shadow was dismissed.

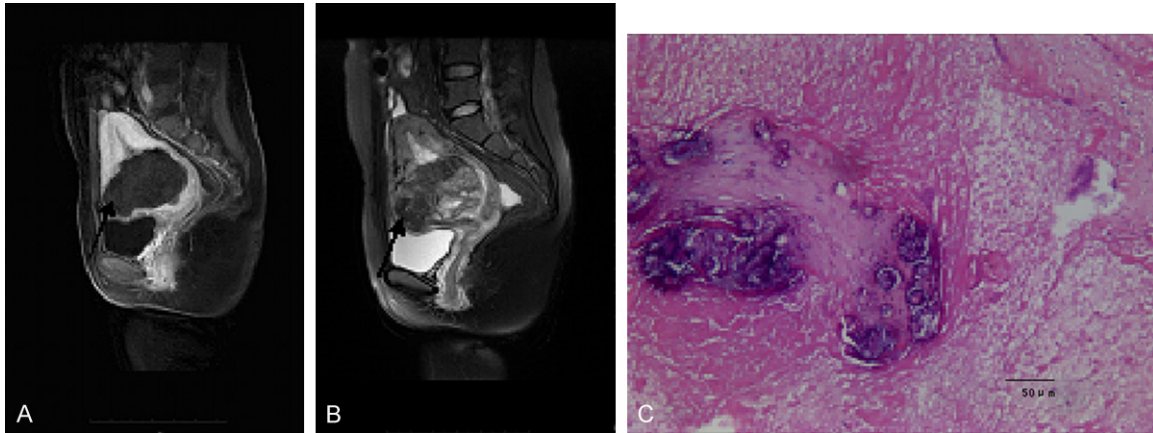


Figure 4. A. A patient with cesarean scar pregnancy at gestation age 14+3 weeks after uterine curettage, sagittal magnetic resonance images showed placenta imbedded in the front wall of uterine cavity close to the cervix (long arrow, enhancement scan). B. The same patient, sagittal magnetic resonance images showed placenta implanted in uterine cavity adjacent to the cervix (arrow indicated, T2-weighted Imaging). C. The same patient resected the uterine scar and its pregnant tissue, postoperative pathology showed degenerative necrosis chorionic villi, trophoblastic tissue and blood clot with calcification, 100 \times .

sion 2 unit of red blood cell suspension, the hemorrhage amount reached 800 ml.

13 women in group 2 received uterine artery embolization followed by uterine curettage 2 days later. Postoperative pathology of uterine curettage showed degenerative chorionic villi tissue (**Figure 2B**).

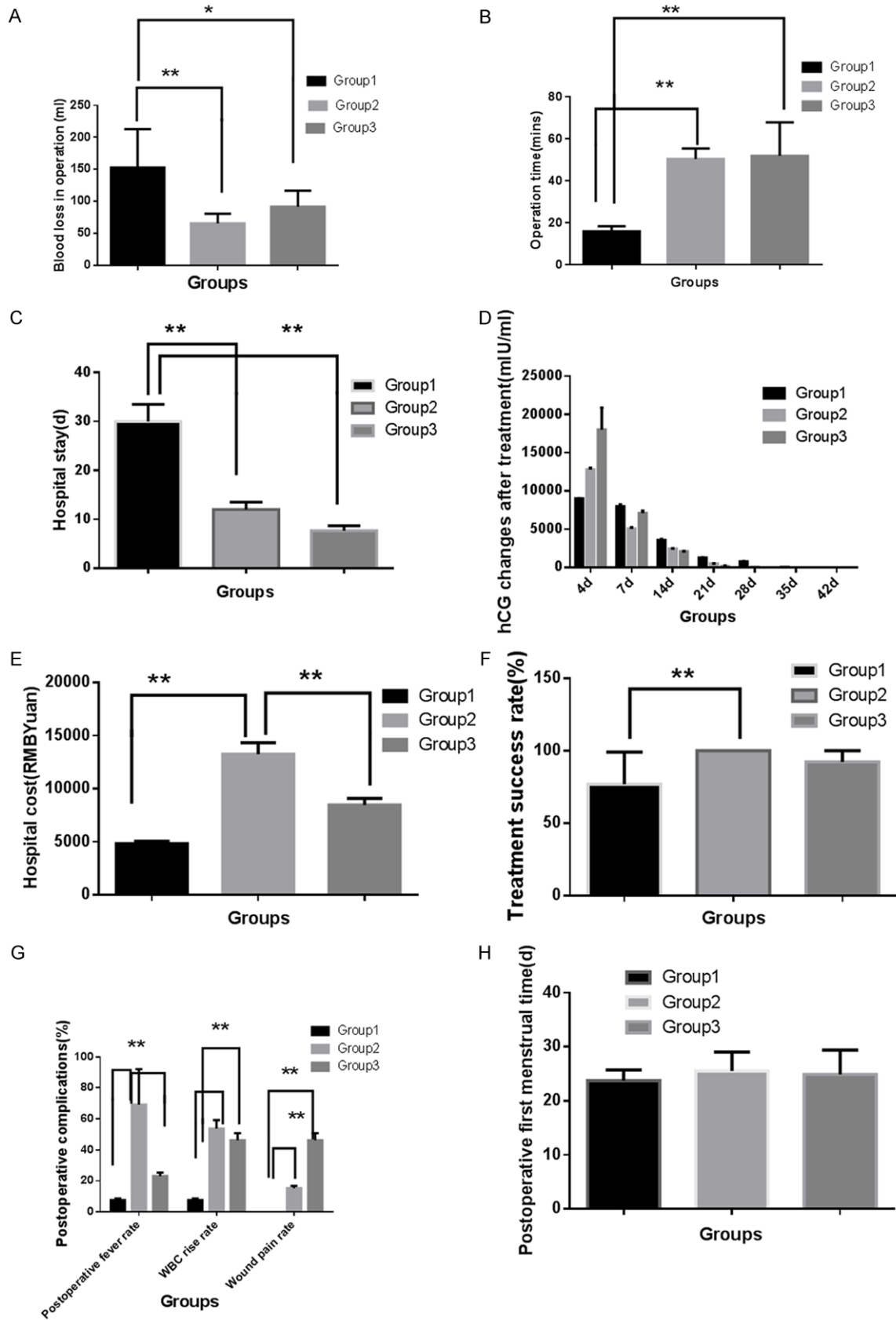
Dynamic digital subtraction angiography (DSA) images of patients can fully display the uterine feeding blood vessels of three phases: artery phase, venous phase, capillary phase. DSA arterial phase found enlarging filling artery by gelfoam particles. DSA venous phase presented 'veins show early signs' causing by arteriove-

nous shunt. DSA capillary phase presented typical tumor-like staining. After uterine artery embolized by absorbable gelfoam particles, DSA visualized that uterine vascular shadow was dismissed (**Figure 3A, 3B**).

The average blood loss amount of these 13 patients was 66 ml (range: 51-95 ml).

13 patients were included in group 3, 12 patients were performed laparotomic excision of gestational sac in scar and repaired uterine defect. The mean hemorrhage amount of these 12 patients reached 92 ml (range: 75 to 125 ml). One patient was performed hysterectomy.

Different methods for CSP treatment



Different methods for CSP treatment

Figure 5. Treatment outcomes of patients with cesarean scar pregnancy. A. Patients in group 2 had the least intraoperative blood loss in three groups. B. Patients in group 1 had the least operation time in three groups. C. Hospital stay time was the longest in group 1. D. hCG fall normal level time in group 1 was more slower than other two groups. E. Hospital cost was higher in group 2 than that of other two groups. F. Treatment success rate was higher in group 2 than that of other two groups. G. Postoperative complications (fever, WBC rise and wound pain rate) were higher in group 2, 3 than that of group 1. H. Postoperative first menstrual time was found no different in three groups. Group 1 received medical treatment + uterine curettage (n=13), Group 2 received uterine artery embolization + uterine curettage (n=13), group 3 received laparotomic resection (n=13), Data represent means \pm SEM, *P<0.05, **P<0.001.

11 patients in first trimester underwent laparotomic excision as above stated.

One patient in second trimester, ultrasonic examination revealed that singleton fetus was at 14+3 weeks gestational age. The fetus was with abnormalities (anencephaly, cardiac abnormalities, pleural effusion, abdominal cavity effusion), placenta covered over the uterine isthmus. The patient received medical abortion by oral administration of mifepristone and misoprostol. It was incomplete abortion, while vaginal bleeding of the patient was abundant, so forcep curettage was performed for the patient at once. The curettage cleared out the fetus and part of the placenta tissue, intraoperative bleeding reached 500 ml. Sonography revealed high echo range 53×85×88 mm in the front wall of uterine cavity near the cervix, closely to uterine scar with rich blood flow. Sagittal magnetic resonance images showed placenta implanted in the front wall of uterine cavity close to cervix (**Figure 4A, 4B**). Diagnosed as “cesarean scar pregnancy, placenta previa/accrete”, the patient was given oral mifepristone 50 mg per day for two months. Sonography, serum β -hCG and the amount of the vagina bleeding were followed up. Because of heavy vaginal bleeding two month later, the patient underwent laparotomic excision of the whole pregnant tissue in scar and repaired uterine defect.

Postoperative pathology of laparotomy showed degenerative necrosis chorionic villi, trophoblastic tissue and blood clot with calcification (**Figure 4C**).

One patient received an urgent laparotomy for massive blood loss during uterine evacuation. The patient was wrongly diagnosed as an intrauterine missed abortion at 9 weeks gestational age. Due to conservative therapy failure, an emergency surgical exploration was performed, the operation found a perforation at the uterine

adjacent to the cervix caused by vacuum aspiration. Because of the seriously injured uterus, the trial to suture the perforation failed, the woman underwent extrafascial hysterectomy. The amount of blood loss reached 1200 ml, the woman was received blood transfusion of 4 unit of red blood cell suspension.

The main outcomes of patients in 3 groups were shown as (**Table 2; Figure 5**).

Intraoperative blood loss was 153.27 \pm 60.24, 66.44 \pm 15.97 versus 92.11 \pm 25.40 (ml) in group 1, group 2 and group 3 respectively. Patients in group 2 had the least intraoperative blood loss in three groups (**Figure 5A**, P<0.001).

Operation time was 15.77 \pm 0.93 (Min), 52.15 \pm 1.29 (Min) and 50.31 \pm 2.09 (Min) respectively in group 1, group 2 and group 3. Patients in group 1 had shortest operation time among three groups, there was statistically significant difference (**Figure 5B**, P<0.001).

Patients in group 1 had the lowest hospital cost among all three groups, but the duration of serum β -hCG reached negative value and hospital stay time were the longest among all three groups. There was statistical significant difference (**Figure 5B-D**, P<0.001).

Patients in group 2 had the least intraoperative blood loss but the highest hospitalization cost among three groups (**Figure 5A, 5E**). There was statistically significant difference (P<0.001).

12 patients in group 3 had all been cured and preserved fertility, one patient underwent hysterectomy and lost fertility. Hospital stay time, duration of serum β -hCG reach negative value were the shortest among all three groups. There were statistical significant difference. (**Figure 5C, 5D**, P<0.001).

Treatment success rates were 76.9% (10/13), 100% (13/13) and 92.3% (12/13) in group 1,

Different methods for CSP treatment

group 2 and group 3 respectively. The highest success rate was group 2. There was statistical significant difference (**Figure 5F**, $P < 0.001$).

The most common side effects patients in group 1 after administration of methotrexate were anorexia or mild nausea. No abnormal liver function such as serum transaminase level elevation or jaundice happened. No abnormal renal function such as serum creatinine or urea nitrogen level rising was detected. No myelosuppression phenomena such as red blood cells, white blood cells or platelets decline were detected.

The most common postoperative complication in group 2, 3 included fever (human body temperature $\geq 38.0^{\circ}\text{C}$), the puncture wound of uterine artery embolization pain, or abdominal pain which were successfully controlled by oral administering ibuprofen. When blood white cell ($\text{WBC} > 10 \times 10^9/\text{L}$) and/or neutrophil ($N > 65\%$) rose, cefotiam combining with metronidazole was administrated intravenous to prevent infection (**Figure 5G**, $P < 0.05$).

No patients in the research died from massive haemorrhage. Bladder injury and pulmonary embolism did not found among 39 women with cesarean scar pregnancy.

All patients were discharged by satisfied with serum β -HCG decreased and wound recovery. Serum β -hCG and transvaginal ultrasound were reviewed weekly after patients were discharged. Postoperative first menstrual time was found no different in three groups (**Figure 5H**, $P > 0.05$). Three months later, all patients were cured.

Discussion

The therapeutic objective for cesarean scar pregnancies (CSP) is to remove pregnant tissue, reduce the incidence of hemorrhage, and preserve the patient's fertility before uterine rupture and massive hemorrhage. The currently available therapeutic methods reported in the literature include medical therapy such as injecting kalium chloratum into embryo, and systematic or regional administration of methotrexate (MTX), uterine artery embolization (UAE), hysteroscopic resection, laparotomic resection, or laparoscopic resection. Individual treatment for cesarean scar pregnancy is neces-

sary; adequate preoperative assessment of the gestational age, fetal viability, myometrial defects, and clinical symptoms become the basis for selecting the most appropriate treatment plan [7-10].

MTX is a very familiar agent preventing embryo from growth. MTX is a competitive antagonist of folinic acid related to DNA synthesis. MTX can inhibit the proliferative gestational trophoblastic cell activity. So MTX is one of medical option for ectopic pregnancy and choriocarcinoma treatment. MTX can be given one course or many courses. Pharmacologic delivery route is from systematic to regional. Systematic given MTX is regarded as a standard option for heterotopic pregnancy, as one of heterotopic pregnancy, MTX is therapeutic approach for patients with CSP treatment when their vital signs are stable. According to literature reports and our clinical experiences, the CSP can be successful treated with systematic administration of MTX followed by uterine curettage or uterine artery embolization (UEA) followed by uterine curettage [11-13].

Unfavorable outcomes with administration of MTX may be encountered especially when serum β -HCG concentration rises over 5000 mU/ml, or fetal cardiac activity appears. This does not mean if serum β -HCG value over 5000 mU/ml, MTX can not inhibit trophoblastic cell activity in scar, this only mean if serum β -HCG concentration is too high, it will need many courses of medical treatment, and it will take long time for a patient to wait serum β -HCG to reach negative value.

Kutuk MS et al, reported the CSP treated with systematic MTX successful. The average blood β -HCG value was $11,240.31 \pm 9812.68$ IU/L (range 2565 to 36,111 IU/L). The mean MTX courses were 5.7 (range 2 to 9), No MTX dose per course was available in their abstract [14].

According to pharmacokinetic mechanism, the effect of MTX relies on local drug concentration in scar, pharmacologic distribution and metabolism. If effective drug concentration is higher, drug delivery duration is shorter, then systematic MTX administration may appear more favorable outcomes for a patient with the same serum β -HCG value. It can increase local MTX concentration by gestation sac in scar injection

Different methods for CSP treatment

or uterine artery perfusion to improve the therapeutic effects [15].

According to our previous clinical experiences, the patient was administered MTX 50 mg/m² in per course in the treatment, if β -HCG value did not decline, the patient would be administered second course MTX 50 mg/m² a week later, the outcomes were often unfavorable, less than half cases β -HCG value decline after the first course treatment. So in this research, the patients were adopted administration of MTX 50 mg every other day at total dose 150 mg per course. Treatment success rate in group 1 was 76.9% (10/13). The average blood β -HCG value was 8,153.26 \pm 2115.33 IU/L. The number of treatment courses was greatly reduced.

So appropriate increasing dosage of MTX per course may be another way to improve curative effect. The most common side effects after patients administration of MTX were anorexia or mild nausea. No other serious complications occurred in our above clinical observation.

Mifepristone is a competitive antagonist of progesterone receptor. Mifepristone combining with misoprostol usually is used for medical abortion in first trimester. In our above study, MTX combining with mifepristone was used to reduce intraoperative blood loss; mifepristone was given preoperatively to enhance apoptosis and necrosis of the trophocytes [16, 17].

Traditionally, uterine curettage was regarded unfit for the principal therapeutic choice due to the danger of causing uterine perforation and heavy haemorrhage, because the characteristics of uterine scar tissues are different from uterine smooth muscles with fragile thin layers, easily bleeding and weak contraction function [3].

Even after serum β -HCG decline to negative values, some authors still worry about uterine curettage may induce massive bleeding. But without uterine curettage, the rates of necrosis pregnant tissues spontaneous abortion are very low. After medical treatment, the CSP become missed abortion or incomplete abortion. In this condition, it is very likely to encounter late postpartum hemorrhage and irregular menstruation.

But MTX combining with mifepristone was used in our above study, when serum β -HCG values

declined to less than 100 U/L, uterine curettage underwent hysteroscope guidance was performed in group 1, uterine curettage blood loss was greatly reduced. Postoperative pathology confirmed after enough dose of medical treatment, pregnant trophoblastic tissues became degenerative necrosis tissues, which completely eliminated trophoblastic tissue invasive ability, This may explain why uterine curettage blood loss was greatly reduced.

Uterine artery embolization (UAE) can reduce blood loss in uterine curettage. UAE must be combined with uterine curettage to get rid of the necrotic pregnant tissues in uterine cavity [18]. In our above study, uterine curettage underwent under hysteroscope guidance 2 days after UAE, blood loss during operation was greatly reduced. No patient was found uterine penetrated and massive bleed loss in group 2. Postoperative pathology of curettage confirmed that pregnant trophoblastic tissues became degenerative chorionic villi tissue and lost invasive ability after UAE.

Caesarean incision repair process forms fibrotic defect scar, the scar is easily invaded by pregnant tissue and induced bleeding. The cause of massive bleeding risk factors mainly determined by myometrium thickness (or defect tissue size) in scar, pregnant tissue activity and gestational sac location. Blood β -hCG value stands for pregnant trophoblastic tissues invasive activity. In our above study, when serum β -HCG declined to negative values, Patient in group 1 underwent medical treatment followed by uterine curettage, patients in group 2 underwent UEA followed by uterine curettage, blood loss was greatly reduced during uterine curettage. Postoperative pathology of curettage confirmed pregnant trophoblastic tissues became degenerative necrosis tissues and lost invasive ability.

The gestational sac that grows toward the urinary bladder is easier encountered heavy bleeding than the gestational sac that grows toward the uterine cavity. So most patients the gestational sac that grows toward the urinary bladder in above research underwent laparotomy.

Surgical optional management can eliminate the pregnant tissues by hysteroscopy, laparoscopy, laparotomy. Surgical operation can also

Different methods for CSP treatment

repair uterine defect in scar and reduce blood loss when medical treatment fails.

Our above study indicated uterine curettage under hysteroscopy guidance could directly determine the pregnancy tissue location and visualize whole procedure of separating the pregnant tissues from uterine wall. It reported that hysteroscopic resection combining uterine artery embolization can obtain satisfactory outcomes. However, the uterine defect in scar has not been repaired by hysteroscopic resection. Hysteroscopic opinion should be used for the pregnant tissue that grows toward the uterine cavity. When the thickness of residual myometrium is less than 3 mm; the gestational sac protrudes toward the abdominal cavity or even invades the urinary bladder, a hysteroscopic resection should not be performed [3, 5, 18].

Laparoscopic resection can remove the pregnant tissue in scar and suture the uterine incision at the same time. The operation is achieved under visualization. The operation can ligate bilateral uterine arteries to reduce blood loss. So the operation may have favorable outcomes. However, laparoscopic opinion should be used for the gestation sac that grows toward the urinary bladder-uterine cesarean defect. The operation require good control of the laparoscopic instruments and excellent orientation of the abdominal cavity. For an inexperienced laparoscopists, laparoscopic treatment of CSP could become a difficult task and may lead to failure. So experienced and skilled gynecologic laparoscopists are also needed. When operation face difficulties, the patient should convert to laparotomy. When operation encounter heavy bleeding, hysterectomy may be required immediately. This may reduce clinical application indications of laparoscopic resection [5].

Laparotomic resection can remove the imbedded gestation sac, therefore no residual trophoblasts are left in situ. Laparotomic option can resect uterine old scar, the uterine microtubular tracts are removed. So laparotomic resection reduce the risk of recurrence and preserve the patients fertility. When medical treatment for CSP has no response, or women with CSP are in dangerous situation such as massive bleeding, uterine rupture, laparotomic resection is the preferred approach [5, 19].

It is assumed laparotomic resection has certain disadvantages such as large surgical wo-

unds, a longer hospital stay, and slower recovery [5]. However, according to above study, 12 patients in group 3, the most common postoperative complication of laparotomic resection included fever, abdominal wound pain, white blood cell rose that could be successfully controlled, hospital stay time was shorter than medical conservative treatment. Patients completely healed when patients discharged from hospital.

According to our clinical experience, during laparotomic resection, special attention should be paid to the relationship between the uterine scar and the bladder. If there are local adhesions, adhesiolysis should be performed; the bladder should be pushed downward appropriately to avoid both bladder injury during the surgical procedure and subsequent difficulties when suturing the uterine incision. These measures make possible not only faster and more effective hemostasis and suturing but also significant shortening of the operation time and reduction of intraoperative bleeding [5, 20].

During laparotomic operation, the myometrium sutures should not penetrate the endometrium. The serosa and myometrium tissues should be sutured exactly to enhance tissue healing and scar repair [5].

Laparotomy in group 3 showed former cesarean incision surface rough, brittle and adhered with bladder firmly. The residual myometrium were weak or interruptive, even only with serosal layer covered. Laparotomy confirmed that the properties of the uterine scar tissues were thoroughly different from that of common myometrium, and with the characteristics of easy bleeding and rupture. So it was necessary to perform laparotomy to resect uterine scar and repair uterine defects. None of the 12 patients in group 3 receiving laparotomy experienced collateral injuries.

Cesarean scar pregnancy is a serious complication caused by caesarean section and other through the uterine cavity operation. Comparing to hysteroscopy or laparoscopic resection, laparotomic resection is in fact a minitype caesarean section, it is relatively simple, basic operation model. No special conditions of patients such as the pregnant tissue implantation site are demanded. No special technologies and equipments are required. Laparotomy opera-

tion cost is lower than that of laparoscopy, its effect is reliable. All patients in group 3 were discharged satisfied with serum β -HCG declining to normal level, wound recovery.

The current research had certain insufficient. Only 39 patients in this study may lead to selective deviation. In this research, regular menorrhoea came back in 38 patients, except one patient received hysterectomy, no long-range following up was carried out. We will accumulate more cases of cesarean scar pregnancy, carry out a random contrasting trial next.

Taken together, among the three methods for cesarean scar pregnancy treatment, uterine artery embolization combining with uterine curettage is securer and more effective therapy, the cost of hospital stay is relatively higher. If β -hCG value not too high, the patients can choose conservative medical treatment followed by uterine curettage under firmly monitored, methotrexate should be given enough dose per course, Chemotherapy can make pregnant trophoblastic tissues become necrosis tissues and lost invasive ability, which can greatly reduced uterine curettage blood loss. In this method, the hospitalization expenses is relatively lower, but a patient stays in hospital stay time longer and faces some risk of treatment failure. Pregnant tissues in scar are with characteristics of easy bleeding and uterine rupture, laparotomic resection can remove the scar tissues and repair the uterine defect, which is last choice when other treatment fails. The harm impact of operation on patients is limited.

Acknowledgements

The author accepted no funding for the study. The study obtained consent of all patients, passed through the hospital ethics committee approval.

Disclosure of conflict of interest

None.

Address correspondence to: Liming Guan, Department of Obstetrics and Gynaecology, Zhabei District Central Hospital, No. 619, Zhonghuaxin Road, Zhabei District, Shanghai 200000, China. E-mail: guanliming1@126.com

References

- [1] Maymon R, Svirsky R, Smorgick N, Mendlovic S, Halperin R, Gilad K, Tovbin J. Fertility performance and obstetric outcomes among women with previous cesarean scar pregnancy. *J Ultrasound Med* 2011; 30: 1179-84.
- [2] Najj O, Wynants L, Smith A, Abdallah Y, Saso S, Stalder C, Van Huffel S, Ghaem-Maghani S, Van Calster B, Timmerman D, Bourne T. Does the presence of a Caesarean section scar affect implantation site and early pregnancy outcome in women attending an early pregnancy assessment unit? *Hum Reprod* 2013; 28: 1489-1496.
- [3] Wu X, Xue X, Wu X, Lin R, Yuan Y, Wang Q, Xu C, He Y, Hu W. Combined laparoscopy and hysteroscopy vs. uterine curettage in the uterine artery embolization-based management of cesarean scar pregnancy: a cohort study. *Int J Clin Exp Med* 2014; 7: 2793-803.
- [4] Li YR, Xiao SS, Wan YJ, Xue M. Analysis of the efficacy of three treatment options for cesarean scar pregnancy management. *J Obstet Gynaecol Res* 2014; 40: 2146-51.
- [5] Wang G, Liu X, Bi F, Yin L, Sa R, Wang D, Yang Q. Evaluation of the efficacy of laparoscopic resection for the management of exogenous cesarean scar pregnancy. *Fertil Steril* 2014; 101: 1501-7.
- [6] Osborn DA, Williams TR, Craig BM. Cesarean scar pregnancy: sonographic and magnetic resonance imaging findings, complications, and treatment. *J Ultrasound Med* 2012; 31: 1449-1456.
- [7] Zhang XB, Zhong YC, Chi JC, Shen JL, Qiu XX, Xu JR, Zhao AM, Di W. Cesarean scar pregnancy: treatment with bilateral uterine artery chemoembolization combined with dilation and curettage. *J Int Med Res* 2012; 40: 1919-1930.
- [8] Yin XH, Yang SZ, Wang ZQ, Jia HY, Shi M. Injection of MTX for the treatment of cesarean scar pregnancy: comparison between different methods. *Int J Clin Exp Med* 2014; 7: 1867-72.
- [9] OuYang Z, Yin Q, Xu Y, Ma Y, Zhang Q, Yu Y. Heterotopic cesarean scar pregnancy: diagnosis, treatment, and prognosis. *J Ultrasound Med* 2014; 33: 1533-1537.
- [10] Kelekçi S, Aydoğmuş S, Aydoğmuş H, Eriş S, Demirel E, Şen Selim H. Ineffectual medical treatment of cesarean scar ectopic pregnancy with systemic methotrexate: a report of two cases. *J Investig Med High Impact Case Rep* 2014; 2: 1-4.
- [11] Sieczko D, Edwards H, Heggs K, White D. Cesarean scar ectopic pregnancy: a case report. *Ultrasound* 2014; 22: 126-128.

Different methods for CSP treatment

- [12] Moschos E, Wells CE, Twickler DM. Biometric sonographic findings of abnormally adherent trophoblastic implantations on cesarean delivery scars. *J Ultrasound Med* 2014; 33: 475-481.
- [13] Brasic N, Warden M, Vargas JE. Conservative management of cesarean scar pregnancy with sonographically guided transvaginal methotrexate injection. *J Ultrasound Med* 2013; 32: 1061-1063.
- [14] Kutuk MS, Uysal G, Dolanbay M, Ozgun MT. Successful medical treatment of cesarean scar ectopic pregnancies with systemic multidose methotrexate: single-center experience. *J Obstet Gynaecol Res* 2014; 40: 1700-6.
- [15] Gupta S, Pineda G, Rubin S, Timor-Tritsch IE. Four consecutive recurrent cesarean scar pregnancies in a single patient. *J Ultrasound Med* 2013; 32: 1878-1880.
- [16] Lam PM, Lo KW, Lau TK. Unsuccessful medical treatment of cesarean scar ectopic pregnancy with systemic methotrexate: a report of two cases. *Acta Obstet Gynecol Scand* 2004; 83: 108-11.
- [17] Horne AW, Skubisz MM, Tong S, Duncan WC, Neil P, Wallace EM, Johns TG. Combination gefitinib and methotrexate treatment for non-tubal ectopic pregnancies: a case series. *Hum Reprod* 2014; 29: 1375-1379.
- [18] Gómez García MT, Ruiz Sánchez E, Aguarón Benítez G, Nogueira García J, Callejón Rodríguez C, González Merlo G. Cesarean scar ectopic pregnancy successfully treated with methotrexate and mifepristone. *J Obstet Gynaecol* 2015; 35: 105-6.
- [19] Timor-Tritsch IE, Monteagudo A, Cali G, Vintzileos A, Viscarello R, Al-Khan A, Zamudio S, Mayberry P, Cordoba MM, Dar P. Cesarean scar pregnancy is a precursor of morbidly adherent placenta. *Ultrasound Obstet Gynecol* 2014; 44: 346-53.
- [20] Qian ZD, Guo QY, Huang LL. Identifying risk factors for recurrent cesarean scar pregnancy: a case-control study. *Fertil Steril* 2014; 102: 129-134.