

## Original Article

# Role of canstatin in early fibrotic lesions of idiopathic interstitial pneumonias and migration of lung fibroblasts

Hirokazu Urushiyama<sup>1,2</sup>, Yasuhiro Terasaki<sup>2</sup>, Shinya Nagasaka<sup>2</sup>, Nariaki Kokuho<sup>2</sup>, Mika Terasaki<sup>2</sup>, Shinobu Kunugi<sup>2</sup>, Yu Mikami<sup>1</sup>, Satoshi Noguchi<sup>1</sup>, Masafumi Horie<sup>1</sup>, Kiyotaka Nagahama<sup>2</sup>, Yasuhiro Yamauchi<sup>1</sup>, Akira Shimizu<sup>2</sup>, Takahide Nagase<sup>1</sup>

<sup>1</sup>Department of Respiratory Medicine, Graduate School of Medicine, University of Tokyo, Tokyo, Japan;

<sup>2</sup>Department of Analytic Human Pathology, Nippon Medical School, Tokyo, Japan

Received July 24, 2016; Accepted July 25, 2016; Epub December 1, 2016; Published December 15, 2016

**Abstract:** Early fibrotic lesions are thought to be one of the initial findings of lung fibrogenesis in idiopathic interstitial pneumonias, but little is known about their properties. Canstatin is an endogenous angiogenesis inhibitor derived from the C-terminal globular non-collagenous domain of the  $\alpha 2$  chain of type IV collagen, and type IV collagen is deposited in early fibrotic lesions without neovascularization in usual interstitial pneumonia (UIP). We used immunohistochemical methods to study expression of canstatin in lung specimens from patients with UIP or organizing pneumonia (OP). We analyzed the expression and function of canstatin in cultured lung fibroblasts by Western blotting and a Boyden chamber migration assay. We found expression of canstatin in early fibrotic lesions of UIP but not OP. Lung fibroblasts showed enhanced expression of canstatin after being stimulated with transforming growth factor- $\beta 1$ . Recombinant canstatin inhibited migration of not only endothelial cells but also lung fibroblasts. These results suggest that fibroblasts in early fibrotic lesions of UIP, which express canstatin, have less ability to migrate than fibroblasts in OP lesions, which do not express canstatin. Thus, canstatin in early fibrotic lesions of UIP contributes to persistent fibrogenesis and is likely involved in its refractory nature, including migration of intralésional fibroblasts.

**Keywords:** Canstatin, usual interstitial pneumonia, organizing pneumonia, immunohistochemistry, fibroblast, migration

## Introduction

Idiopathic interstitial pneumonias (IIPs) consist of a heterogeneous group of non-neoplastic disorders caused by damage to the lung parenchyma. The etiology remains unknown. IIPs exhibit various patterns of inflammation and fibrosis, and the clinical-radiologic-pathologic features form the basis of clinical diagnosis of IIPs. Idiopathic pulmonary fibrosis (IPF)/usual interstitial pneumonia (UIP) is considered to be a subgroup of IIPs that has a poor prognosis due to poor responses to treatment, whereas cryptogenic organizing pneumonia (COP)/organizing pneumonia (OP) is a subgroup that responds better to treatment and has a good prognosis [1, 2]. In IIPs, early fibrotic lesions are comprised of small aggregates of fibroblasts and myofibroblasts with the abnormal extracellular

matrix (ECM) deposition and are considered initial findings of lung fibrogenesis [3]. The fibroblastic foci of UIP and intraluminal buds of OP are representative early fibrotic lesions.

The lesions show variation among IIPs, not only in tissue morphology but also in the properties affecting lung fibrogenesis. For example, the intraluminal buds of OP are characterized by deposition of matrix metalloproteinase-2, which plays a key role in ECM degradation, whereas the fibroblastic foci of UIP are characterized by deposition of tissue inhibitors of that enzyme [4].

The ECM provides structural support, but many ECM components also provide important signals to fibroblasts and other cells with which they come into contact [5-7]. For example, sev-

# Canstatin in idiopathic interstitial pneumonia

**Table 1.** Baseline characteristics of patients with UIP and OP at the time of lung biopsy

|   | UIP (n = 12)        | OP (n = 11)         |
|---|---------------------|---------------------|
| Age, years (range)                          | 62.9 (49-79)        | 60.6 (43-75)        |
| Gender, male/female                         | 10/2                | 4/7                 |
| Smoking status, ever/never                  | 11/1                | 7/4                 |
| Interval between onset and biopsy, months   | 18.3 ± 16.6         | 3.05 ± 1.54         |
| VC, liters                                  | 2.50 ± 1.03         | 2.71 ± 0.60         |
| VC% predicted, %                            | 77.1 ± 28.7         | 96.5 ± 18.3         |
| DLC0% predicted, % (total number with data) | 42.8 ± 11.0 (n = 5) | 68.4 ± 8.74 (n = 3) |
| KL-6, U/ml (total number with data)         | 1555 ± 1402 (n = 5) | 349 ± 141 (n = 4)   |

Data are expressed as means ± s.d.

eral basement membrane (BM) components, and even fragments of them, were discovered to regulate cell functions. Endostatin [8], a 20-kDa C-terminal fragment of type XVIII collagen contained in vascular and epithelial BMs, inhibits endothelial cell migration [9] and angiogenesis. Endostatin has been detected in several human tissue samples *in vivo*, such as on fibroblasts in human fetal tendons [10].

Type IV collagen is another important structural component of the BM [11] and is composed of six different  $\alpha$  chains:  $\alpha 1$ - $\alpha 6$  chains of type IV collagen ( $\alpha 1$ (IV) through  $\alpha 6$ (IV) chains) [12]. We previously reported that the  $\alpha 2$ (IV) chain is deposited in the fibroblastic foci of UIP, but not in the intraluminal buds of OP, and that it inhibits migration of lung fibroblasts by reducing the phosphorylation level of focal adhesion kinase (FAK) [13]. However, little is known about which part of the  $\alpha 2$ (IV) chain affects the physiological function of lung fibroblasts. On the other hand, canstatin [14], which is a part of the C-terminal globular non-collagenous (NC1) domain of that chain, inhibits angiogenesis by suppressing endothelial cell migration. Thus, we hypothesized that canstatin may affect the physiological function of lung fibroblasts of IIPs as well as endothelial cells. To elucidate those points, we studied the expression, localization and possible function of canstatin in human lung tissue sections diagnosed as UIP and OP, as well as in cultured human lung fibroblasts.

## Materials and methods

### Patients

Lung specimens were gained by performing surgical lung biopsies (12 UIP and 11 OP cases) at the Nippon Medical School Hospital from 1992 to 2011. All specimens were diagnosed

in accordance with the American Thoracic Society/European Respiratory Society International Multidisciplinary Consensus Classification of Idiopathic Interstitial Pneumonias [1, 2]. The study design was approved by the Human Ethics Review Committee of Nippon Medical School. Written informed consent was obtained from all patients. **Table 1** shows the demographic characteristics and pulmonary function data for the patients at the time of lung biopsy.

### Analysis for early fibrotic lesions of UIP and OP

For patients with UIP, surgical lung biopsy specimens were obtained from the upper and lower lobes of 8 patients, from three lobes of one patient, and from the lower lobes of 3 patients. For patients with OP, specimens were obtained from two diseased lung lobes in 5 patients and from a single diseased lobe in 6 patients. Two authors (HU, YT), without knowing the clinical information, examined all fibroblastic foci in UIP and intraluminal buds in OP on all available slides prepared from surgical lung biopsies. The average observed number of early fibrotic lesions was 7.34 per lung lobe for the UIP patients and 46.0 per lung lobe for the OP patients.

### Cell culture

Human diploid fetal lung fibroblasts of the TIG-1-20 cell line [15] were purchased from Health Science Research Resources Bank. TIG-1-20 cells were cultured in Dulbecco's modified Eagle's medium (DMEM; Wako Pure Chemical Industries, Osaka, Japan) supplemented with 10% fetal bovine serum (FBS), 50- $\mu$ g/ml streptomycin, and 50-U/ml penicillin at 37°C under humidified 5% CO<sub>2</sub>/95% air.

# Canstatin in idiopathic interstitial pneumonia

## *Immunohistochemistry*

Immunohistochemistry was performed as described in detail previously [13]. In short, to unmask antigenic epitopes, sections were heated at 120°C for 20 min with 0.01 M citrate buffer (pH 6.0). Primary antibodies were rabbit polyclonal anti-canstatin (5 µg/ml; Boster Biological Technology, Fremont, CA), mouse monoclonal anti-human  $\alpha$ -smooth muscle actin ( $\alpha$ -SMA) (1:300; Dako, Glostrup, Denmark) and mouse monoclonal anti-CD34 (1:100; Nichirei Biosciences, Tokyo, Japan).

## *Western blotting*

To examine the production of canstatin by TIG-1-20 cells, culture medium with FBS was replaced with serum-free DMEM on day 1 after passage. The cells were then cultured with various concentrations of recombinant human TGF- $\beta$ 1. After 72-h culture with TGF- $\beta$ 1, the medium was collected and the cells were homogenized in M-PER (Mammalian Protein Extraction Reagent; Thermo Scientific, Rockford, IL) containing a protein-stabilizing cocktail (Halt Protease Inhibitor Cocktail; Thermo Scientific), 150 mM NaCl, and 1 mM EDTA. Homogenized samples were centrifuged (15,000 rpm, 25 min), and the supernatant was called the cell lysate. Western blotting was performed as described in detail previously [13]. Briefly, reduced samples were transferred to polyvinylidene difluoride membranes. The membranes were incubated at 4°C overnight with primary antibody against canstatin at a dilution of 1:300, or antibodies against  $\alpha$ -SMA and  $\alpha$ -tubulin (Epitomics, Burlingame, CA) at a dilution of 1:3000, and then with the appropriate horseradish peroxidase-conjugated secondary antibody (Promega, Madison, WI) for 60 min. Production of each protein was determined as a ratio to the amount of  $\alpha$ -tubulin protein, and results were reported relative to culture without TGF- $\beta$ 1 = 1.0.

## *Preparation of purified recombinant canstatin*

The sequence encoding canstatin was obtained using primer information from a prior study [14] and amplified by PCR. The resulting cDNA fragments were digested with Sall and HindIII and ligated into pEcoli-Nterm 6xHN Linear Vector (Clontech Laboratories, Mountain View, CA). Plasmid constructs encoding canstatin were first transformed into JM109 *E. coli* cells (Clo-

ntech Laboratories) and then transformed into BL21 *E. coli* cells for expression (Novagen, Madison, WI). Recombinant canstatin from stably transformed BL21 cells was purified using a HisTALON Gravity Columns Purification Kit (Clontech Laboratories) according to the manufacturer's instructions.

## *Migration assay*

To examine the effects of canstatin on fibroblast migration, TIG-1-20 cells at a density of  $1.0 \times 10^6$  cells/ml in 300 µl of serum-free DMEM with either 50 ng canstatin (conc. 1 ng/µl) or 50 µl of sterile PBS were placed in the inserts of a Boyden chamber having an 8-µm-pore membrane (BD Biosciences, Durham, NC). DMEM supplemented with 10% FBS was placed as a chemoattractant in the wells in the bottom compartment. The chamber was incubated for 12 h at 37°C under humidified 5% CO<sub>2</sub>/95% air, and non-migrating cells on the upper surface of the 8-µm-pore membrane of the insert were removed by scraping. The membrane was fixed and stained using a Diff-Quik Kit (Sysmex, Hyogo, Japan). Migration was assessed using a light microscope (IX71; Olympus, Tokyo, Japan) to count the number of cells in 5 random high-power fields on the bottom surface of the insert membrane.

## *Statistical analysis*

One-way analysis of variance and unpaired t-tests were used for statistical analysis by using GraphPad Prism6 (GraphPad Software, San Diego, CA).  $P < 0.05$  values were considered to be statistically significant.

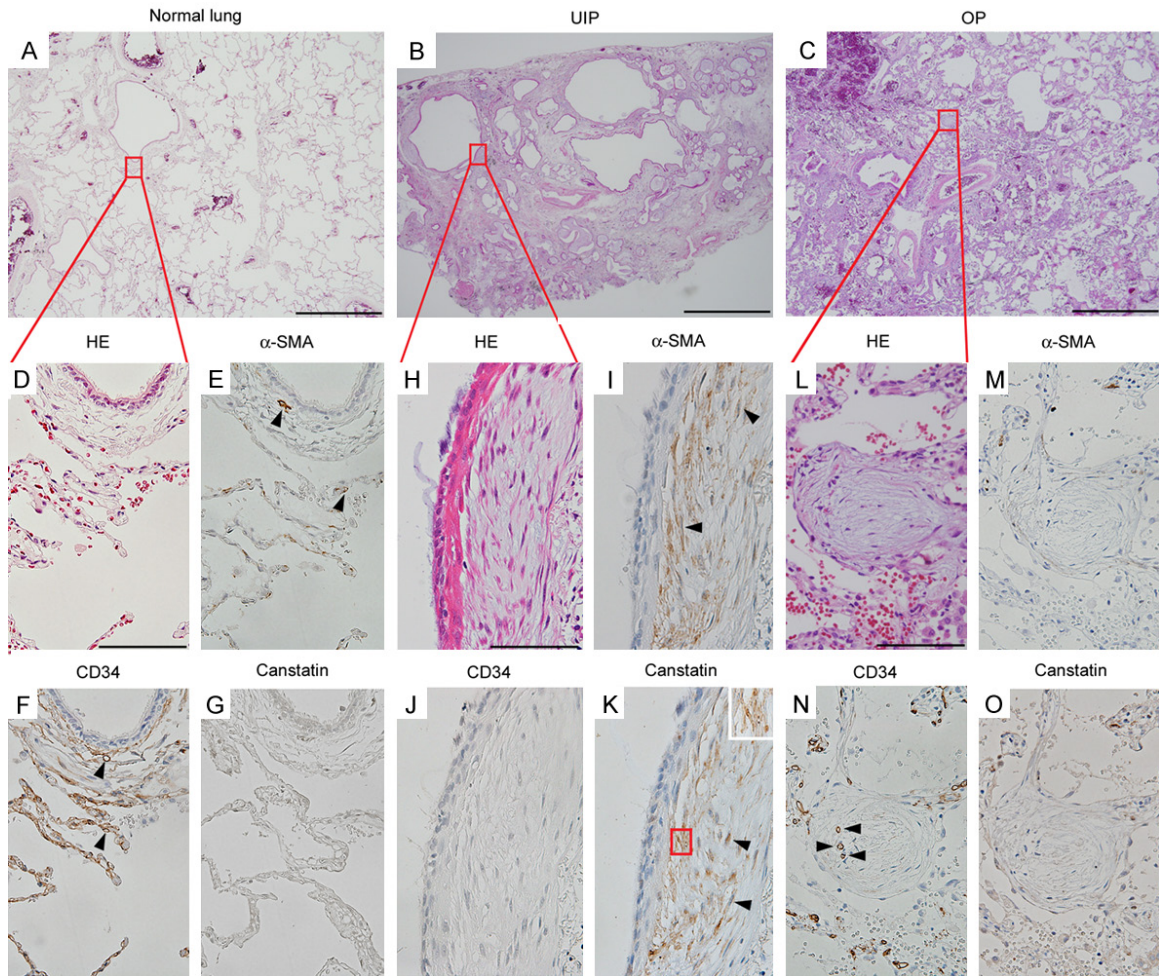
## **Results**

### *Expression of canstatin in early fibrotic lesions of UIP and OP*

To elucidate the expression and precise role(s) of canstatin in IIPs, we used immunohistochemical methods to study the immunoreactivity for canstatin and compared it with the expression of  $\alpha$ -SMA by using tissue sections diagnosed as UIP and OP in addition to normal lung specimens (**Figure 1A-C**). In the fibroblastic foci of UIP, fibroblasts showed strong positive staining for  $\alpha$ -SMA representing myofibroblasts (**Figure 1I**, arrowheads) in the foci without



## Canstatin in idiopathic interstitial pneumonia



**Figure 1.** Canstatin,  $\alpha$ -smooth muscle actin ( $\alpha$ -SMA), and CD34 in normal control lung and early fibrotic lesions of usual interstitial pneumonia (UIP) and organizing pneumonia (OP). Representative hematoxylin-eosin (HE)-stained specimens of normal control lung (A), UIP (B) and OP (C). Scale bars = 1000  $\mu$ m. High-magnification views of the red rectangular area in (A-C), respectively: normal alveoli and a bronchial wall (D), a fibroblastic focus (H) and an intraluminal polyp (L). Scale bars = 50  $\mu$ m. The normal lung had cells that were clearly positive for  $\alpha$ -SMA (E, Arrowheads), i.e., mainly smooth muscle cells of CD34-positive capillary vessels (F, Arrowheads), whereas there was no immunoreactivity for canstatin (G). In UIP, fibroblasts showed  $\alpha$ -SMA-positive immunoreactivity as they differentiated into myofibroblasts (I, Arrowheads) in a fibroblastic focus that had no CD34-positive neovessels (J). In contrast, in OP, fibroblasts in an intraluminal bud showed no  $\alpha$ -SMA-positive immunoreactivity (M), but the bud clearly contained CD34-positive neovessels (N, Arrowheads). Immunoreactivity for canstatin was clearly observed on myofibroblasts in a fibroblastic focus without neovessels (K, Arrowheads and inset), but not in an intraluminal bud with neovessels (O). The inset shows a high-magnification view of the red rectangular area in (K).

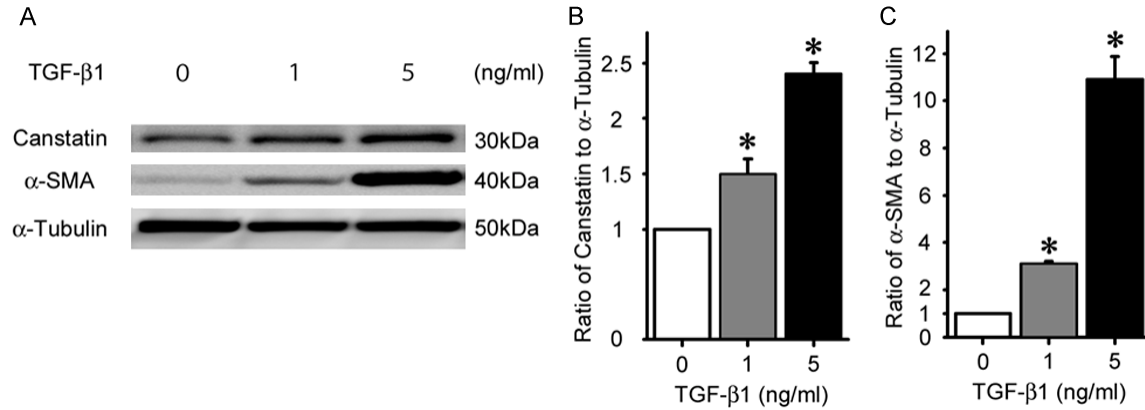
neovessels (**Figure 1J**), while in the intraluminal buds of OP, fibroblasts were negative for  $\alpha$ -SMA (**Figures 1M**) in the buds with neovessels (**Figure 1N**, arrowheads). Immunoreactivity for canstatin was clearly observed on myofibroblasts in the fibroblastic foci of UIP (**Figure 1K**, arrowheads and inset), but not in the intraluminal buds of OP (**Figure 1O**). Immunoreactivity for canstatin, however, was not observed in normal lung (**Figure 1G**). Thus, the immunoreactivity for canstatin was clearly observed on

myofibroblasts in fibroblastic foci without neovessels in UIP, but not in intraluminal buds with neovessels in OP.

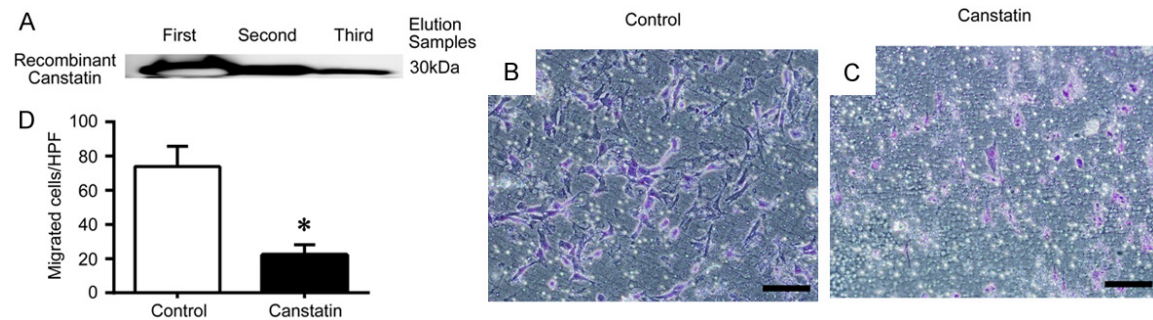
### *Expression of canstatin in cultured lung fibroblasts*

We investigated whether lung myofibroblasts produce canstatin by studying the functional response of TIG-1-20 cells, a well-characterized cultured human lung fibroblast cell line, to TGF-

## Canstatin in idiopathic interstitial pneumonia



**Figure 2.** Dose-dependent up-regulation of canstatin by transforming growth factor (TGF)-β1. Representative Western blots showing the amounts of canstatin in culture medium and the amounts of α-SMA and α-tubulin in TIG-1-20 cell lysates after treatment with different concentrations of TGF-β1 (A). The ratios of canstatin (B) and α-SMA (C) to α-tubulin in the same sample were expressed relative to the results for the control cells cultured without TGF-β1 (= 1.0) in the same experiments. Data from each experiment were quantified by means of densitometry. Data are means ± s.d.m. from three experiments. \* $P < 0.05$  for differences between the indicated means.



**Figure 3.** Effects of canstatin on migration of TIG-1-20 cells. (A) Representative Western blots show strong positive anti-canstatin immunoreactivity of the recombinant protein in the eluate obtained with a purification kit. Each eluate sample (first, second, third) was obtained by passing three times through the purification column. TIG-1-20 cells in serum-free DMEM medium with either canstatin or sterile PBS were seeded into the inserts of a Boyden chamber. DMEM supplemented with 10% FBS was placed as a chemoattractant in the wells in the bottom compartment. Migrated cells were counted after culturing for 12 h at 37 °C. Representative images are shown of migrated TIG-1-20 cells treated with sterile PBS as the control (B) or canstatin (C). Five random high-power fields (HPF) were counted to determine the number of migrated cells (D). Data are means ± s.d.m. from three experiments. Scale bars = 100 μm. \* $P < 0.05$  for differences between the indicated means.

β1 stimulation. TGF-β1 is present in fibroblastic foci of UIP [16], and we found that TGF-β1 stimulation for 72 h induced strong α-SMA expression in TIG-1-20 cells as they differentiated into myfibroblasts [13]. Thus, we measured canstatin expression in TIG-1-20 cells stimulated with various concentrations of TGF-β1 for 72 h. Western blotting showed that the cells released canstatin into the culture medium in a TGF-β1 dose-dependent manner, similar to production of α-SMA (Figure 2A-C). This result is consistent with our finding of immunoreactivity for canstatin on α-SMA-positive myfibroblasts in fibroblastic foci of UIP.

### Effects of canstatin on migration of cultured lung fibroblasts

It is known that canstatin inhibits endothelial cell migration [14], and we reported that the α2(IV) chain produced by fibroblasts inhibited migration of fibroblasts [13]. Therefore, to investigate whether canstatin affects migration of lung fibroblasts, we conducted a migration assay of TIG-1-20 cells using recombinant canstatin. We first confirmed that our recombinant canstatin showed strong positive reactivity with anti-canstatin antibody as a 30-kDa band in Western blotting, similar to that report-

ed by Kamphaus et al. [14] (**Figure 3A**). A Boyden chamber assay then found that the recombinant canstatin inhibited TIG-1-20 cell migration (**Figure 3B-D**), comparable to the inhibition shown by the  $\alpha 2(\text{IV})$  chain, which we reported previously [13]. Thus, our results showed that recombinant canstatin inhibits lung fibroblast migration, as well as migration of endothelial cells, as previously reported [14].

### Discussion

Here, we report for the first time that immunoreactivity for canstatin was observed in fibroblastic foci without neovascularization in UIP, but not in intraluminal buds with sufficient neovascularization in OP. These results are similar to those for  $\alpha$ -SMA expression in the same lesions. TGF- $\beta 1$  enhanced myofibroblastic changes in cultured human lung fibroblasts, with increased production of canstatin *in vitro*. We also found that recombinant canstatin inhibited migration of lung fibroblasts, as well as that of endothelial cells. Therefore, our results suggested that fibroblasts in the foci of UIP produce canstatin and that canstatin deposited in the foci of UIP inhibits migration of intralesional fibroblasts as well as cultured lung fibroblasts *in vitro*. Thus, we suggest that deposition of canstatin in early fibrotic lesions is involved in the refractory fibrogenesis of IIPs through this inhibition of migration of intralesional fibroblasts and endothelial cells.

Canstatin, a 24-kDa peptide derived from the C-terminal fragment of the NC1 domain of the  $\alpha 2(\text{IV})$  chain, inhibits angiogenesis *in vivo* [14] and is grouped together with such endogenous angiogenesis inhibitors as endostatin. Because canstatin is an  $\alpha 2(\text{IV})$  chain fragment, our findings are in line with our previous report that the  $\alpha 2(\text{IV})$  chain was deposited in fibroblastic foci but not in intraluminal buds [13]. To our knowledge, this is the first evidence of canstatin immunoreactivity on myofibroblasts in human tissue *in vivo*, i.e., in the fibroblastic foci of UIP. However, these findings are similar to those for immunoreactivity for endostatin, one of the most important endogenous angiogenesis inhibitors, observed in several human tissue samples *in vivo*: on the internal limiting membrane in age-related macular degeneration [17] and on fibroblasts in human fetal tendons [10]. Moreover, because canstatin is an endogenous

angiogenesis inhibitor, our findings of canstatin expression in fibroblastic foci of UIP agree well with earlier findings that those foci are devoid of neovessels [18].

Our Western blot analysis revealed that lung fibroblasts produced canstatin when stimulated with TGF- $\beta 1$ , and that production increased in proportion to  $\alpha$ -SMA expression following differentiation of fibroblasts into myofibroblasts. These results are consistent with our *in vivo* result that canstatin immunoreactivity is observed on myofibroblasts in the fibroblastic foci of UIP, which were also reported to express TGF- $\beta 1$  [16]. Moreover, these results are similar to earlier *in vitro* findings that endostatin was produced by hemangioendothelioma cells [8] and released from platelets [19].

Canstatin inhibits phosphorylation of FAK by binding to integrins [20, 21], thereby inhibiting endothelial cell migration and tube formation [14]. Canstatin suppressed tumor growth by inhibiting angiogenesis in human xenograft mouse models of prostate cancer [14], breast cancer [22], pancreatic cancer [23] and lung cancer [24]. To our knowledge, except for endothelial cells, only colorectal cancer cell migration had been shown to be inhibited by canstatin [25]. Here, we have, for the first time, provided evidence that recombinant canstatin inhibits migration of lung fibroblasts. Our present results are consistent with our previous data showing that knockdown of the  $\alpha 2(\text{IV})$  chain in human lung fibroblasts increased their migration, while  $\alpha 2(\text{IV})$  chain produced by lung fibroblasts negated that effect by lowering FAK phosphorylation levels [13]. Because that earlier study also clearly showed the presence of phosphorylated FAK in fibroblasts in the intraluminal buds of OP, but not in the fibroblastic foci of UIP [13], we speculate that increased deposition of the  $\alpha 2(\text{IV})$  chain, especially canstatin, produced by lung fibroblasts in early fibrotic lesions of UIP inhibits migration of intralesional fibroblasts via inactivation of FAK, similar to its effect on endothelial cells.

Aberrant fibrosis typically results from chronic inflammation-defined as a persistent immune response due to inadequate regulation of growth factors, proteolytic enzymes, fibrogenic cytokines and angiogenesis factors-that leads to deposition of ECM that progressively remodels



and destroys normal tissue architecture [26]. Although it is unclear whether inhibition of angiogenesis worsens fibrosis in IIPs [27], several studies support that thesis. For example, pigment epithelium-derived factor, which has angiostatic activity, is increased in the lung tissue of patients with IPF [28]; administration of vascular endothelial growth factor attenuated renal fibrosis [29]; and vascular endothelial growth factor expression is greater in the intraluminal buds of OP than the fibroblastic foci of UIP [30]. Moreover, endostatin was elevated in the bronchoalveolar lavage fluid and plasma of patients with IPF [31]. And our current detection of canstatin immunoreactivity only in fibroblastic foci without neovascularization in UIP supports the theory that inhibition of angiogenesis exacerbates lung fibrosis.

Matrix metalloproteinase-2 catalyzes ECM degradation and supports cell migration [32], while tissue inhibitors of metalloproteinase-2 inhibit both cell migration and angiogenesis [33]. Our colleagues previously reported that deposition of matrix metalloproteinase-2 was greater in the intraluminal buds of OP, whereas deposition of its inhibitors was greater in the fibroblastic foci of UIP [4]. We also previously reported that fibroblasts in the intraluminal buds of OP, which have high FAK phosphorylation levels, may have higher migration activity compared with fibroblasts in the fibroblastic foci of UIP, which have low levels of FAK phosphorylation [13]. In our present study, canstatin immunoreactivity was observed only in the fibroblastic foci of UIP, but not in the intraluminal buds of OP, and recombinant canstatin inhibited migration of lung fibroblasts. Therefore, our results showing high levels of canstatin deposition with low FAK phosphorylation levels of fibroblasts in the fibroblastic foci of UIP are consistent with the characteristic features of UIP, such as chronic, slowly progressive fibrosis due to low migration activity of fibroblasts and endothelial cells. On the other hand, low levels of canstatin deposition and high levels of FAK phosphorylation of fibroblasts in the intraluminal buds of OP agree with the characteristic features of OP, such as acute to subacute progressive and migratory lung fibrosis due to high migration activity of fibroblasts and endothelial cells. Thus, our data may help to explain why the characteristic, irreversible lung fibrosis of UIP differs from reversible lung fibrosis as a general process of wound healing, such as in OP.

The precise role of canstatin in the early fibrotic lesions of IIPs in relation to the prognosis of each IIP remains unclear. However, because El-Zammar et al. [34] and we [35] showed that some fibroblasts in early fibrotic lesions of UIP and OP were stained positively for Ki-67, we speculate that some fibroblasts in those lesions proliferate and differentiate into myofibroblasts that produce canstatin. Canstatin then inhibits migration of intralesional fibroblasts, which tend to remain and continue to generate ECM in the lesions, thereby leading to refractory chronic fibrosis in IIPs that have a poor prognosis, such as UIP.

In conclusion, our present study findings provide evidence that canstatin is deposited around myofibroblasts in the early fibrotic lesions of IIPs having a poor prognosis. They also suggest that canstatin produced by myofibroblasts is involved in the refractory fibrogenesis of IIPs, including migration of intralesional fibroblasts and inhibition of angiogenesis in early fibrotic lesions. We anticipate that continued investigation of the canstatin-mediated mechanisms regulating fibroblast migration and angiogenesis in early fibrotic lesions of IIPs will contribute to a better understanding of the pathogenesis of IIPs and development of targeted therapies for IIPs.

### Acknowledgements

This work was partly supported by JSPS KAKENHI Grant Numbers JP15K19434 (HU) and JP16H02653 (TN), and by grants-in-aid for scientific research from the Diffuse Lung Diseases Research Group (YT) and the Respiratory Failure Research Group (TN) from the Ministry of Health, Labor and Welfare of Japan.

### Disclosure of conflict of interest

None.

**Address correspondence to:** Dr. Yasuhiro Terasaki, Department of Analytic Human Pathology, Graduate School of Medicine, Nippon Medical School, 1-1-5 Sendagi, Bunkyo-ku, Tokyo 113-8602, Japan. Tel: +81-3-3822-2131; E-mail: terasaki@nms.ac.jp

### References

- [1] Travis WD, Costabel U, Hansell DM, King TE Jr, Lynch DA, Nicholson AG, Ryerson CJ, Ryu JH, Selman M, Wells AU, Behr J, Bouros D, Brown KK, Colby TV, Collard HR, Cordeiro CR, Cottin V,

## Canstatin in idiopathic interstitial pneumonia

- Crestani B, Drent M, Dudden RF, Egan J, Flaherty K, Hogaboam C, Inoue Y, Johkoh T, Kim DS, Kitaichi M, Loyd J, Martinez FJ, Myers J, Protzko S, Raghu G, Richeldi L, Sverzellati N, Swigris J, Valeyre D; ATS/ERS Committee on Idiopathic Interstitial Pneumonias. An official American Thoracic Society/European Respiratory Society statement: Update of the international multidisciplinary classification of the idiopathic interstitial pneumonias. *Am J Respir Crit Care Med* 2013; 188: 733-748.
- [2] American Thoracic Society; European Respiratory Society. American Thoracic Society/European Respiratory Society international multidisciplinary consensus classification of idiopathic interstitial pneumonias. *Am J Respir Crit Care Med* 2002; 165: 277-304.
- [3] Crystal RG, Bitterman PB, Mossman B, Schwarz MI, Sheppard D, Almsy L, Chapman HA, Friedman SL, King TE Jr, Leinwand LA, Liotta L, Martin GR, Schwartz DA, Schultz GS, Wagner CR, Musson RA, Ronald G Crystal, Peter B. Bitterman, Brooke Mossman, Marvin I. Schwarz, Dean Sheppard, Laura Almsy, Harold A Chapman, Scott L Friedman, Talmadge E King Jr, Leslie A Leinwand, Lance Liotta, George R Martin, David A Schwartz, Gregory S Schultz, Carston R Wagner and Robert A. Future research directions in idiopathic pulmonary fibrosis. *Am J Respir Crit Care Med* 2002; 166: 236-246.
- [4] Fukuda Y, Ishizaki M, Kudoh S, Kitaichi M, Yamanaka N. Localization of matrix metalloproteinases-1, -2, and -9 and tissue inhibitor of metalloproteinase-2 in interstitial lung diseases. *Lab Invest* 1998; 78: 687-698.
- [5] Serini G, Bochaton-Piallat ML, Ropraz P, Geinoz A, Borsi L, Zardi L, Gabbiani G. The fibronectin domain ED-A is crucial for myofibroblastic phenotype induction by transforming growth factor- $\beta$ 1. *J Cell Biol* 1998; 142: 873-881.
- [6] Kliment CR, Englert JM, Gochuico BR, Yu G, Kaminski N, Rosas I, Oury TD. Oxidative stress alters syndecan-1 distribution lungs with pulmonary fibrosis. *J Biol Chem* 2009; 284: 3537-3545.
- [7] Naik PK, Bozyk PD, Bentley JK, Popova AP, Birch CM, Wilke CA, Fry CD, White ES, Sisson TH, Tayob N, Carnemolla B, Orecchia P, Flaherty KR, Hershenson MB, Murray S, Martinez FJ, Moore BB; COMET Investigators. Periostin promotes fibrosis and predicts progression in patients with idiopathic pulmonary fibrosis. *Am J Physiol Lung Cell Mol Physiol* 2012; 303: L1046-56.
- [8] O'Reilly MS, Boehm T, Shing Y, Fukai N, Vasios G, Lane WS, Flynn E, Birkhead JR, Olsen BR, Folkman J. Endostatin: an endogenous inhibitor of angiogenesis and tumor growth. *Cell* 1997; 88: 277-285.
- [9] Dhanabal M, Ramchandran R, Volk R, Stillman IE, Lombardo M, Iruela-Arispe ML, Simons M, Sukhatme VP. Endostatin: yeast production, mutant, and antitumor effect in renal cell carcinoma. *Cancer Res* 1999; 59: 189-197.
- [10] Pufe T, Petersen W, Kurz B, Tsokos M, Tillmann B, Mentlein R. Mechanical factors influence the expression of endostatin-an inhibitor of angiogenesis-in tendons. *J Orthop Res* 2003; 21: 610-616.
- [11] Timpl R. Structure and biological activity of basement membrane proteins. *Eur J Biochem* 1989; 180: 487-502.
- [12] Prockop DJ, Kivirikko KI. Collagens: molecular biology, diseases, and potentials for therapy. *Annu Rev Biochem* 1995; 64: 403-434.
- [13] Urushiyama H, Terasaki Y, Nagasaka S, Terasaki M, Kunugi S, Nagase T, Fukuda Y, Shimizu A. Role of  $\alpha$ 1 and  $\alpha$ 2 chains of type IV collagen in early fibrotic lesions of idiopathic interstitial pneumonias and migration of lung fibroblasts. *Lab Invest* 2015; 95: 872-885.
- [14] Kamphaus GD, Colorado PC, Panka DJ, Hopfer H, Ramchandran R, Torre A, Maeshima Y, Mier JW, Sukhatme VP, Kalluri R. Canstatin, a novel matrix-derived inhibitor of angiogenesis and tumor growth. *J Biol Chem* 2000; 275: 1209-1215.
- [15] Ohashi M, Aizawa S, Ooka H, Ohsawa T, Kaji K, Kondo H, Kobayashi T, Noumura T, Matsuo M, Mitsui Y, Murota S, Yamamoto K, Ito H, Shimada H, Utakoji T. A new human diploid cell strain, TIG-1, for the research on cellular aging. *Exp Gerontol* 1980; 15: 121-33.
- [16] Khalil N, O'Connor RN, Flanders KC, Unruh H. TGF-beta 1, but not TGF-beta 2 or TGF-beta 3, is differentially present in epithelial cells of advanced pulmonary fibrosis: an immunohistochemical study. *Am J Respir Cell Mol Biol* 1996; 14: 131-138.
- [17] Bhutto IA. Localization of collagen XVIII and the endostatin portion of collagen XVIII in aged human control eyes and eyes with age-related macular degeneration. *Invest Ophthalmol Vis Sci* 2004; 45: 1544-1552.
- [18] Ebina M, Shimizukawa M, Shibata N, Kimura Y, Suzuki T, Endo M, Sasano H, Kondo T, Nukiwa T. Heterogeneous increase in CD34-positive alveolar capillaries in idiopathic pulmonary fibrosis. *Am J Respir Crit Care Med* 2004; 169: 1203-1208.
- [19] Ma L, Hollenberg MD, Wallace JL. Thrombin-induced platelet endostatin release is blocked by a proteinase activated receptor-4 (PAR4) antagonist. *Br J Pharmacol* 2001; 134: 701-704.



## Canstatin in idiopathic interstitial pneumonia

- [20] Panka DJ, Mier JW. Canstatin inhibits Akt activation and induces Fas-dependent apoptosis in endothelial cells. *J Biol Chem* 2003; 278: 37632-37636.
- [21] Magnon C, Galaup A, Mullan B, Rouffiac V, Bouquet C, Bidart JM, Griscelli F, Opolon P, Perricaudet M. Canstatin acts on endothelial and tumor cells via mitochondrial damage initiated through interaction with  $\alpha v\beta 3$  and  $\alpha v\beta 5$  integrins. *Cancer Res* 2005; 65: 4353-4361.
- [22] Magnon C, Opolon P, Connault E, Mir LM, Perricaudet M, Martel-Renoir D. Canstatin gene electrotransfer combined with radiotherapy: preclinical trials for cancer treatment. *Gene Ther* 2008; 15: 1436-1445.
- [23] He XP, Su CQ, Wang XH, Pan X, Tu ZX, Gong YF, Gao J, Liao Z, Jin J, Wu HY, Man XH, Li ZS. E1B-55kD-deleted oncolytic adenovirus armed with canstatin gene yields an enhanced anti-tumor efficacy on pancreatic cancer. *Cancer Lett* 2009; 285: 89-98.
- [24] Li YY, Qian GS, Huang GJ, Chen F, Qian P, Yu SC, Wang CZ, Li Q, Wang JC, Wu GM. Enhancement of antiangiogenic effects of human canstatin with a hypoxia-regulated transgene vector in lung cancer model. *Cancer J* 2006; 12: 136-146.
- [25] Xing Y, Liang H, Zhao L, Xu H. The antitumor activity of exogenous and endogenous canstatin on colorectal cancer cells. *Asian Pac J Cancer Prev* 2011; 12: 2713-2716.
- [26] Wynn TA. Cellular and molecular mechanisms of fibrosis. *J Pathol* 2008; 214: 199-210.
- [27] Hanumegowda C, Farkas L, Kolb M. Angiogenesis in pulmonary fibrosis: Too much or not enough? *Chest* 2012; 142: 200-207.
- [28] Cosgrove GP, Brown KK, Schiemann WP, Serls AE, Parr JE, Geraci MW, Schwarz MI, Cool CD, Worthen GS. Pigment epithelium-derived factor in idiopathic pulmonary fibrosis: a role in aberrant angiogenesis. *Am J Respir Crit Care Med* 2004; 170: 242-251.
- [29] Kang DH, Hughes J, Mazzali M, Schreiner GF, Johnson RJ. Impaired angiogenesis in the remnant kidney model: II. Vascular endothelial growth factor administration reduces renal fibrosis and stabilizes renal function. *J Am Soc Nephrol* 2001; 12: 1448-57.
- [30] Lappi-Blanco E, Soini Y, Kinnula V, Pääkkö P. VEGF and bFGF are highly expressed in intraluminal fibromyxoid lesions in bronchiolitis obliterans organizing pneumonia. *J Pathol* 2002; 196: 220-7.
- [31] Richter AG, McKeown S, Rathinam S, Harper L, Rajesh P, McAuley DF, Heljasvaara R, Thickett DR. Soluble endostatin is a novel inhibitor of epithelial repair in idiopathic pulmonary fibrosis. *Thorax* 2009; 64: 156-161.
- [32] Björklund M, Koivunen E. Gelatinase-mediated migration and invasion of cancer cells. *Biochim Biophys Acta* 2005; 1755: 37-69.
- [33] Brew K, Nagase H. The tissue inhibitors of metalloproteinases (TIMPs): An ancient family with structural and functional diversity. *BBA-Mol Cell Res* 2010; 1803: 55-71.
- [34] El-Zammar O, Rosenbaum P, Katzenstein AL. Proliferative activity in fibrosing lung diseases: a comparative study of Ki-67 immunoreactivity in diffuse alveolar damage, bronchiolitis obliterans-organizing pneumonia, and usual interstitial pneumonia. *Hum Pathol* 2009; 40: 1182-8.
- [35] Kang D, Nakayama T, Togashi M, Yamamoto M, Takahashi M, Kunugi S, Ishizaki M, Fukuda Y. Two forms of diffuse alveolar damage in the lungs of patients with acute respiratory distress syndrome. *Hum Pathol* 2009; 40: 1618-1627.