

Original Article

Clinical and muscular pathological characteristics of hypomyopathic dermatomyositis: an analysis of six cases

Xiao-Lei Zhang^{1,2}, Dao-Jun Hong³, Yun Yuan¹

¹Department of Neurology, No.1 Hospital of Peking University, Beijing 100034, China; ²Department of Neurology, Shanxi People's Hospital, Taiyuan 030012, China; ³Department of Neurology, 1st Affiliated Hospital of Nanchang University, Nanchang 330006, China

Received July 28, 2016; Accepted August 21, 2016; Epub October 1, 2016; Published October 15, 2016

Abstract: Objective: This study aims to investigate the clinical manifestations and muscular pathological changes of hypomyopathic dermatomyositis (HDM). Methods: A total of 62 patients with dermatomyositis, were enrolled into this study, who underwent muscle biopsy in our hospital between January 2008 and June 2010. Six patients with HDM were screened in accordance with the diagnostic criteria for HDM, in which myogenic damage was found in four patients by EMG. At the same time, biceps brachii biopsies were performed in these six patients; and histological and enzymatic histochemical and immunohistochemical staining were performed for these specimens. The first antibodies for the latter were CD8, CD20 and CD68 mouse anti-human monoclonal antibody and mouse anti-human monoclonal antibody labeled with major histocompatibility complex type-I antigen (MHC-I). Results: Slight to moderate degrees of fat droplets increased in muscular fibers in all six patients, and individual macrophage infiltration and B lymphocytes infiltration appeared in the perimysium. Perifascicular distribution characteristics of individual small round atrophic muscle fibers were found in three patients, accompanied by individual muscle fiber necrosis and regeneration. MHC-I was hyperchromatic in the perifascicular distributed muscle fiber membranes in all patients, and non-specific esterase were hyperchromatic in perifascicular distributed inter-muscular capillaries. Conclusion: Skeletal muscle pathological changes in some patients with HDM were similar to classic dermatomyositis, suggesting that the disease is an intermediate type between amyopathic dermatomyositis and classic dermatomyositis.

Keywords: Dermatomyositis, pathology, clinical, hypomyopathic dermatomyositis

Introduction

Dermatomyositis is a kind of autoimmune connective tissue disease that mainly involves striated muscles and the skin, and is also a kind of immune microvascular disease [1-3]. On the basis of the clinical symptoms, dermatomyositis can be classified into typical dermatomyositis and clinical amyopathic dermatomyositis [4, 5]. Clinical manifestations of typical dermatomyositis include weakness and pain of the proximal extremities, accompanied by characteristic skin damages [6]. Furthermore, clinical amyopathic dermatomyositis accounts for approximately 20% of dermatomyositis [7], including simple amyopathic dermatomyositis (ADM) and hypomyopathic dermatomyositis (HDM) [4, 8, 9]. The former refers to patients

who have typical skin damage of dermatomyositis, but have no myopathy evidence within two years or for a long period of time. The latter refers to patients who have characteristic cutaneous manifestations of dermatomyositis with no clinical symptoms of muscle involvement, normal or elevated serum creatase levels, sub-clinical evidence of muscle involvement determined by electromyogram (EMG), muscle biopsy and imaging examinations, and a medical history of more than six months [4, 10].

Clinical ADM is considered to be a disease type that is different from classic dermatomyositis, since it can occur with the rapid development of interstitial lung disease [11, 12]. However, there are certain degrees of muscular fiber damages in HDM subtypes. Furthermore, the characteris-

Hypomyopathic dermatomyositis

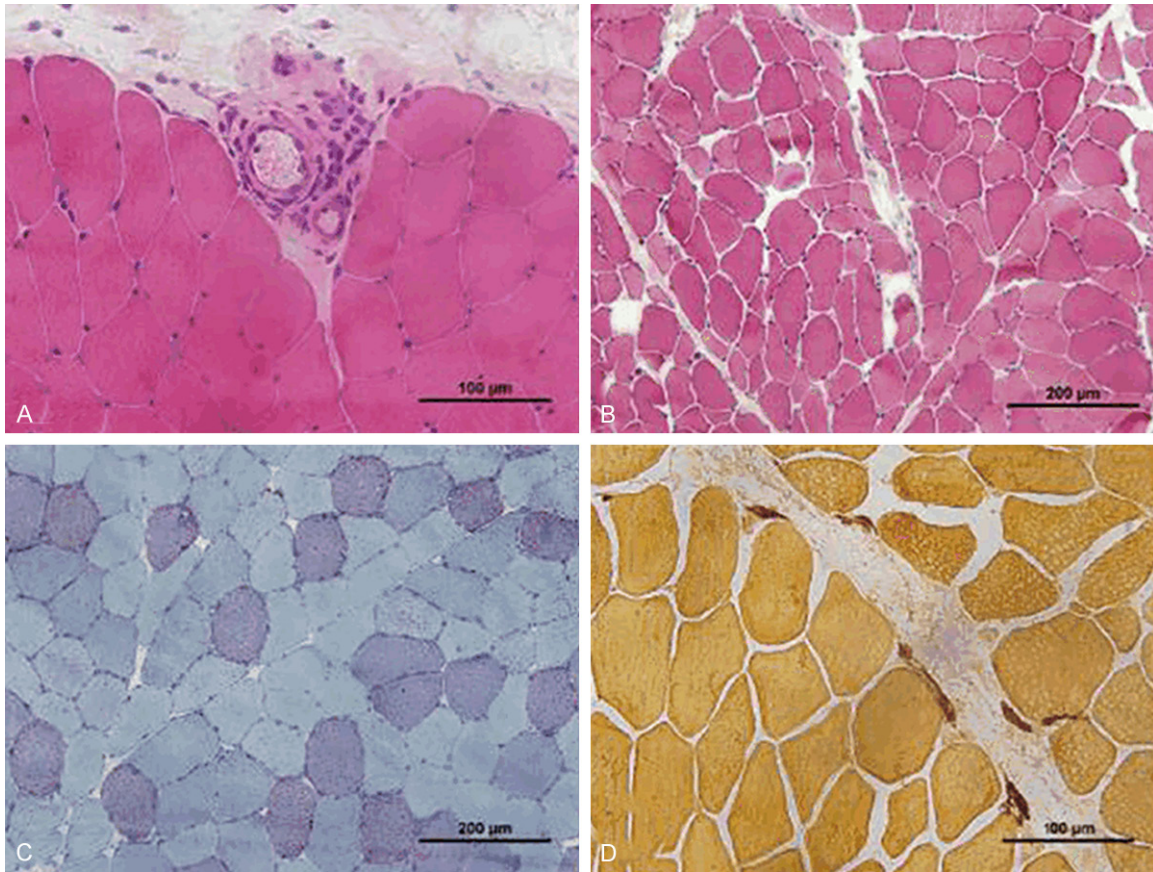


Figure 1. The results of the perimysium connective tissue in the H&E staining of muscle biopsies. A: Different numbers of inflammatory cell infiltrations were found around partial of the small blood vessels in five patients, which were mainly lymphocytic infiltrations accompanied by plasma cells and macrophages; and the structure of the vascular wall was normal. B: A small distribution of perifascicular small round atrophic muscle fibers was found in three patients. C: Individual muscular fiber necrosis and regeneration changes were found in five patients, which were mostly distributed around the perimysium. ORO staining results revealed a slight increase in fat droplets in partial muscular fibers in six patients. D: NSE staining results revealed that no obvious hyperchromatic muscular fibers in four patients, small blood vessels in the perimysium and inter-muscular capillaries near the perimysium were hyperchromatic, the infiltrated inflammatory cells were hyperchromatic.

tics of its pathological changes and whether it has a relationship with classic dermatomyositis remains to be determined. In this study, six patients with HDM were summarized and analyzed; and the clinical manifestations and characteristics of the muscular pathological changes of HDM in Chinese people were discussed.

Materials and methods

Clinical data

A retrospective analysis and follow-ups were performed on 62 patients with dermatomyositis, who underwent muscle biopsy in the Department of Neurology of Peking University First Hospital between January 2008 and June

2010. The diagnostic criteria for HDM is described as follows: Patients who have characteristic cutaneous manifestations of dermatomyositis without clinical symptoms of muscle involvement, normal serum creatase levels, sub-clinical evidences of muscle involvement determined by EMG, muscle biopsy or image examination, and a medical history of more than six months. At the same time, the following conditions are excluded: (1) patients who received immunosuppressive therapy for more than two months during the six month-course of skin damage, and (2) patients who used medicine that is known to produce rash with dermatomyositic characteristics (such as hydroxyurea) [7]. Finally, six patients with HDM who met the diagnosis criteria were enrolled

Hypomyopathic dermatomyositis

into this study. All data were personally examined and reviewed by neurologists with a title above sub-advanced, and informed consents were obtained from all patients. All patients were identified with typical skin changes of dermatomyositis by rheumatologists.

Six patients were enrolled, which accounted for 9.68% of patients with dermatomyositis. Among these patients, two patients were male and four patients were female. Furthermore, the onset age was 46-65 years old, and all patients had no family history. The course lasted for over six months, and clinical manifestations were typical skin changes of dermatomyositis. Edematous purple red spots around the eyelids were found in five patients during the course of the disease (**Figure 1A**). Poikiloderma-like erythema was found at the neck, shoulder, upper chest, forearm, and upper arm in six patients. A V-shaped skin heliotrope rash at the chest was found in two patients. Symmetrically distributed purplish red papules at the back of metacarpophalangeal joints and the elbow extensor side were found in three patients, in which some papules revealed atrophic purple red patches or fused into plaques, and formed a Gottron sign (**Figure 1B**). There was no muscle weakness in all six patients. However, three patients had slight muscle pain during the course of the disease. Creatine kinase (CK) was normal in five cases in the examination, and the CK value in one case was elevated to 582 IU/L (normal value: 25-195 IU/L). Jo-1 antibodies were positive in three patients and PM-Scl 100 was positive in one patient. The antibody spectrums of the other patients with myositis were as follows: Mi-2, Ku, PM-Scl 100, PM-Scl 175, Jo-1, SRP, PL-7 and PL-12. EJ, OJ and Ro-52 were all negative. The ENA polypeptide spectrum and ANCA antibody were negative. Paraneoplastic syndrome associated antibodies such as amphipycin, CV2, PNMA2 (Ma2/Ta), Hu, Yo and Ri were all negative. EMG examination results revealed that four patients had myogenic damage, while no significant abnormalities were found in the other two patients. ECG results of these six patients were generally normal. Pulmonary inflammatory changes were found in four patients, and one of them died due to the rapid development of interstitial lung disease. Among these six patients, four were treated with glucocorticoids at different time points before the diagnosis; and medicines were all administered orally, but the way was

not standard. Glucocorticoid pulse therapy was performed on six patients after diagnosis, in which skin symptoms in five patients and pulmonary symptoms in three patients disappeared. Furthermore, no evidence of further muscular damage was found in clinic; and skin damage reappeared in one patient when the dose of hormone was reduced, CK value increased and weakness symptoms appeared in the proximal limb, and dermatomyositis changes were found in clinic.

Methods

Histological and enzymatic histochemical staining: Left biceps brachii biopsies were performed in six patients with informed consent. Frozen sections were prepared after the specimens were frozen-fixed in liquid nitrogen. Slice thickness was 8 μ m, and the sections were routinely stained using the histological and enzymatic histochemical method: stained with hematoxylin and eosin (H&E), modified Gomori trichrome (MGT), periodate Schiff reaction (PAS), oil red O (ORO) and adenosine triphosphatase (ATPase), reduced form of nicotinamide-adenine dinucleotide hydrogen tetrazolium reductase (NADH-RT), succinate dehydrogenase (SDH) and cytochrome c oxidase (COX), and non-specific esterase (NSE). Then, the sections were observed under light microscopy.

Immunohistochemical staining: The frozen sections were stained with Envision two-step immunohistochemistry, and the thickness of the sections was 6 μ m. The first antibodies were CD4, CD8, CD20, CD68 and MHC-1, respectively; and these were all instant mouse anti-human monoclonal antibodies (DAKO). The second antibody was the EnVision + DAB kit (DAKO). The diagnosed inflammatory muscle samples and normal muscle samples were selected as positive and negative controls, respectively. Criteria for positive results: for positive CD68: the presence of brown-yellow particles in the cytoplasm; for positive CD4, CD8, CD20 and MHC-I: the presents of brown-yellow particles in cell membranes.

Results

No obvious hyperplasia was found in the perimysium connective tissue in the H&E staining of muscle biopsies of the six patients. However, slight edema was found in part of the regional

Hypomyopathic dermatomyositis

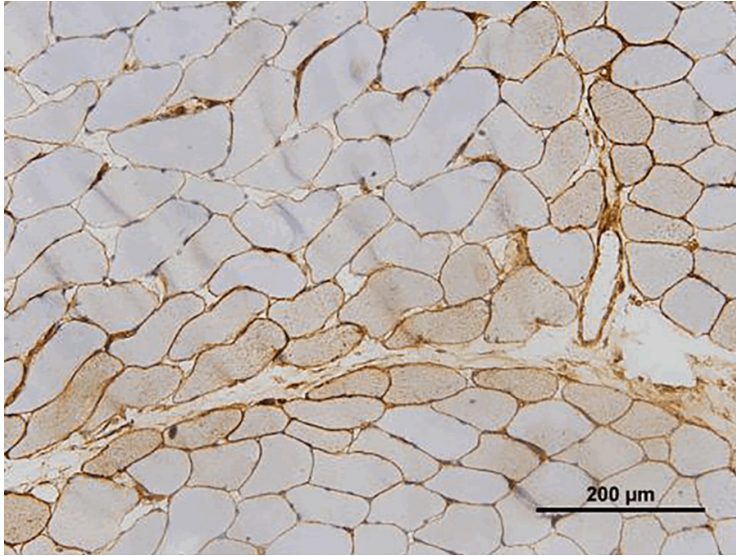


Figure 2. Immunohistochemical staining demonstrated that the expression of MHC-I in the muscular fibrous membrane was positive.

perimysium connective tissues in four patients. Furthermore, partial capillary intima edema in the perimysium was found in six patients. Different numbers of inflammatory cell infiltrations were found around partial of the small blood vessels in five patients, which were mainly lymphocytic infiltrations accompanied by plasma cells and macrophages; and the structure of the vascular wall was normal (**Figure 1A**). A small distribution of perifascicular small round atrophic muscle fibers was found in three patients (**Figure 1B**). Individual muscular fiber necrosis and regeneration changes were found in five patients, which were mostly distributed around the perimysium. ORO staining results revealed a slight increase in fat droplets in partial muscular fibers in six patients (**Figure 1C**). NSE staining results revealed that no obvious hyperchromatic muscular fibers in four patients, small blood vessels in the perimysium and inter-muscular capillaries near the perimysium were hyperchromatic, the infiltrated inflammatory cells were hyperchromatic (**Figure 1D**).

Immunohistochemical staining demonstrated that the expression of MHC-I in the muscular fibrous membrane was positive in six patients, which were mainly the muscular fibers distributed along the perimysium, accompanied by slight cytoplasmic staining (**Figure 2**). A number of CD68 positive macrophages infiltrations were found in the endomysium and perimysium. Focal CD20 positive B-lymphocytes were

found around the individual small vessels. No infiltration of CD4 and CD8 positive T-lymphocytes were found.

Discussion

Purple erythema papula appeared in the facial region, trunk, and limb joint extensor sides in six patients, with characteristics of typical skin changes of dermatomyositis. However, all patients had no myasthenic symptoms of dermatomyositis [11, 12], which was consistent with the clinical myopathic dermatomyositis diagnostic criteria [6]. However, the subclinical evidence of muscular lesions was found through EMG or muscle pathological examinations; and

the disease course was more than half a year. Therefore, they could be diagnosed with hypomyopathic dermatomyositis [4, 8]. At present, the diagnosis of inflammatory muscle disease mainly depends on the clinical manifestations of patients, laboratory indicators, and muscle pathology. Although typical skin rashes were observed in patients enrolled into this study, their weakness was not obvious and the pathological changes characterized by perifascicular degeneration were not detected in muscle biopsy. Therefore, the diagnosis of classic dermatomyositis was not supported. Furthermore, patients had no obvious neck and proximal limb weakness, the creatase value was not high, and muscular fibrous lesions were not found in muscle biopsy. All these do not support the diagnosis of polymyositis. Furthermore, for the inclusion body myositis, which commonly involved in elderly patients manifested with weak forces of the quadriceps femoris and extensor of the hand, this diagnosis could not be apparently supported either.

We found that HDM appeared in approximately 10% of patients with dermatomyositis, this is more common in women, and a similar proportion of incidence could also be found in other reports [9]. The patients in this study had skin changes of dermatomyositis characteristics. However, the V-shape rash and Gottron signs at the chest region were only found in some of our patients, while the proportion of the foreign

Hypomyopathic dermatomyositis

patients with these two signs was over 80% [13]. Although clinical amyasthenia was not significant, muscle pains were found in three cases of patients in this study; and fibromyalgia syndrome was also reported in literature [14]. In addition, the performances of other system damages could be very significant, especially for severe interstitial lung disease, which was also reported in HDM [15-17]; and the proportion of its onset was up to 24% (9/37) [9]. We found that HDM patients can be combined with pulmonary inflammatory changes, and this proportion was higher. Other combined diseases including malignant tumors [14], and the incidence rates, were very similar to that of the adult classic dermatomyositis combined with malignant tumors. In this study, no clinical evidence of patients with malignant tumors was found during the short-term follow-up [10].

Evidence of skeletal muscle abnormalities could be found in auxiliary examinations of HDM. We found that there was a slight increase in CK value in individual patients [9]. Furthermore, myogenic changes were found in the majority of patients in the EMG examination. For patients with myogenic damages could not be detected, abnormal inflammatory changes of the perimysium and muscle fascia could be found by MRI detection [18]. Although anti-synthetase antibodies were found in part of the patients, there was no statistical significance in the difference between autoantibodies and classic dermatomyositis.

There were slight skeletal myositis changes in skeletal muscular pathology in HDM patients in this study, which were similar to the pathological changes of dermatomyositis [10]; and we have previously described these as performances of early stage of dermatomyositis [19]. Generally, this was different from amyopathic dermatomyositis; and there were no abnormalities in the skeletal muscle in the latter [20]. Furthermore, we found that HDM skeletal muscular pathological changes were significant perimysium inflammatory edema changes and fractures. These lesions usually had already existed in circumstances that limb weakness did not appear in dermatomyositis [18]; that, is HDM. In addition, we found that MHC in perifascicular fibers of the skeletal muscle were hyperchromatic in patients and non-specific esterase in the capillaries at this part was also hyperchromatic. A small distribution of perifascicular small round shaped muscle fibers were

also found in few patients, with changes in muscle fibers and blood vessels similar to that in classic dermatomyositis [21, 22]. In the patients in this study, the increase in fat droplets in muscle fibers was related to the ischemic damage of muscle fibers. Although four patients received irregular hormone therapy before diagnosis, there was no improvement in rash symptoms in clinic. This indicates that the effect of hormone therapy on muscular pathological changes was slight. In addition, although hormone therapy can relieve the infiltration degree and reduce the number of inflammatory cells in inflammatory myopathy, the main pathological changes of HDM are microvascular lesions and perifascicular muscular fibrous degeneration; and the significance of inflammatory cell infiltration is small. Therefore, we considered that the short-term application of hormone had no significant effect on HDM muscular pathological changes.

In summary, HDM may not be rare in dermatomyositis, although limb weakness may not be found in HDM, the evidence of skeletal muscular damage found in auxiliary examinations could be the basis for diagnosis. Pathological examination results suggest that HDM is probably the transitional type between classic dermatomyositis and ADM, which can be developed into classic dermatomyositis.

Acknowledgements

Thank technicians Qiu-Rong Zhang and Yue-Huan Zuo from Peking university first hospital for their help.

Disclosure of conflict of interest

None.

Address correspondence to: Yun Yuan, Department of Neurology, No. 1 Hospital of Peking University, 8 Xishiku Street, Xicheng District, Beijing 100034, China. Tel: +86 10-83572588; Fax: +86 10-6655-1057; E-mail: yunyuandoc@163.com

References

- [1] Lahoria R, Selcen D and Engel AG. Microvascular alterations and the role of complement in dermatomyositis. *Brain* 2016; 139: 1891-903.
- [2] McBride JD and Sontheimer RD. Proximal nail-fold microhemorrhage events are manifested as distal cuticular (eponychial) hemosiderin-

Hypomyopathic dermatomyositis

- containing deposits (CEHD) (syn.Maricq sign) and can aid in the diagnosis of dermatomyositis and systemic sclerosis. *Dermatol Online J* 2016; 22.
- [3] Yokoyama Y, Furuta S, Ikeda K, Hirose K and Nakajima H. Corticosteroid-sparing effect of tacrolimus in the initial treatment of dermatomyositis and polymyositis. *Mod Rheumatol* 2015; 25: 888-892.
- [4] El-Dokla AM, Aggarwal R, Oddis CV, Ali ST and Lacomis D. Histopathologic Findings in 5 patients With Hypomyopathic Dermatomyositis: The Importance of MHC-1 Expression on myofibers. *J Clin Neuromuscul Dis* 2015; 17: 52-58.
- [5] Moghadam-Kia S, Oddis CV, Sato S, Kuwana M and Aggarwal R. Anti-Melanoma Differentiation-Associated Gene 5 Is Associated With Rapidly Progressive Lung Disease and Poor Survival in US Patients With Amyopathic and Myopathic Dermatomyositis. *Arthritis Care Res (Hoboken)* 2016; 68: 689-694.
- [6] Udkoff J and Cohen PR. Amyopathic Dermatomyositis: A Concise Review of Clinical Manifestations and Associated Malignancies. *Am J Clin Dermatol* 2016; 17: 509-518.
- [7] Ugan Y, Sahin M, Dogru A, Bayram D, Ceyhan AM and Tunc SE. A case of Amyopathic Dermatomyositis associated with Interstitial Pulmonary Disease. *La Clinica Terapeutica* 2015; 166: 253-255.
- [8] Sontheimer RD. Would a new name hasten the acceptance of amyopathic dermatomyositis (dermatomyositis sine myositis) as a distinctive subset within the idiopathic inflammatory dermatomyopathies spectrum of clinical illness? *J Am Acad Dermatol* 2002; 46: 626-636.
- [9] Gerami P, Schope JM, McDonald L, Walling HW and Sontheimer RD. A systematic review of adult-onset clinically amyopathic dermatomyositis (dermatomyositis sine' myositis): A missing link within the spectrum of the idiopathic inflammatory myopathies. *J Am Acad Dermatol* 2006; 54: 597-613.
- [10] Farrell A, Burnett M and Bohjanen K. hypomyopathic dermatomyositis associated with lentigo maligna melanoma. *J Am Acad Dermatol* 2006; 55: 164-165.
- [11] Wu Y, Chhava S, Hurowitz B, Ardiles T and Carlson R. Clinically Amyopathic Dermatomyositis Complicated by pleural Effusion Case Report, Literature review, and Proposed Mechanism. *Bull Hosp Jt Dis* 2015; 73: 217-220.
- [12] Klein RQ, Teal V, Taylor L, Troxel AB and Werth VP. Number, characteristics, and classification of patients with dermatomyositis seen by dermatology and rheumatology departments at a large tertiary medical center. *J Am Acad Dermatol* 2007; 57: 937-943.
- [13] Caproni M, Cardinali C, Parodi A, Giomi B, Papini M, Vaccaro M, Marzano A, De Simone C, Fazio M, Rebora A and Fabbri P. Amyopathic dermatomyositis: a review by the Italian Group of Immunodermatology. *Arch Dermatol* 2002; 138: 23-27.
- [14] Tsuda T, Asanuma Y, Koyama S, Kawabata Y and Moriguchi M. A case of hypomyopathic dermatomyositis associated with rapid progressive interstitial pneumonia resistant to multi-immunosuppressive therapy. *Am J Med Sci* 2007; 333: 185-190.
- [15] Sato S and Kuwana M. Clinically amyopathic dermatomyositis. *Curr Opin Rheumatol* 2010; 22: 639-643.
- [16] Yokoyama T, Sakamoto T, Shida N, Kinoshita M, Karukava R, Takamatsu M and Aizawa H. Fatal rapidly progressive interstitial pneumonitis associated with amyopathic dermatomyositis and CD8 T lymphocytes. *J Intensive Care Med* 2005; 20: 160-163.
- [17] Mukae H, Ishimoto H, Sakamoto N, Hara S, Kakugawa S, Ishimatsu Y, Kawakami A, Eguchi K and Kohno S. Clinical differences between interstitial lung disease associated with clinically amyopathic dermatomyositis and classic dermatomyositis. *Chest* 2009; 136: 1341-1347.
- [18] Yoshida K, Kurosaka D, Joh K, Matsushima S, Takahashi E, Hirai K, Noda K, Ukichi T, Furuya K, Kingetsu I, Fukuda K, Yamada A and Yanagimachi M. Fasciitis as a common lesion of dermatomyositis, demonstrated early after disease onset by en bloc biopsy combined with magnetic resonance imaging. *Arthritis Rheum* 2010; 62: 3751-3759.
- [19] Yuan Y, Wang ZX and Chen QT. Pathological changes of adult dermatomyositis in early stage. *Chinese Journal of Neurology* 2000; 33: 36-38.
- [20] McCann LJ, Li CK, Varsani H, Wedderburn LR and Pilkington CA. Failure to over express MHC-CLASS-1 on muscle biopsy in a case of amyopathic juvenile dermatomyositis. *Clin Exp Rheumatol* 2007; 25: 96-98.
- [21] Pestronk A, Schmidt RE and Choksi R. Vascular pathology in dermatomyositis and anatomic relations to myopathology. *Muscle Nerve* 2010; 42: 53-61.
- [22] Mammen AL. Dermatomyositis and polymyositis: Clinical presentation, autoantibodies, and pathogenesis. *Ann N Y Acad Sci* 2010; 1184: 134-153.