

Original Article

Chronic inflammation injury promotes hepatocellular carcinoma development via up-regulation of γ -H2AX

Wen Li^{1*}, Jing-Yuan Zhao^{2*}, Xiao-Yun Li³, Yun-Hua Mao², Hao Zhang¹, Ming-Xing Xu¹, Chu-Zhi Pan¹, Shu-Xian Chen¹, Wei-Dong Pan¹

¹Department of Hepatobiliary Surgery, The Third Affiliated Hospital of Sun Yat-sen University, Guangzhou, China; ²Guangdong Provincial Key Laboratory of Liver Disease Research, Sun Yat-sen University, Guangzhou, China; ³Department of Medical Oncology, The First Affiliated Hospital, He-Nan University, Kaifeng, China. *Equal contributors.

Received January 8, 2017; Accepted March 15, 2017; Epub April 1, 2017; Published April 15, 2017

Abstract: Hepatocellular carcinoma (HCC) is one of the most deadly cancers associated with chronic hepatitis. Inflammatory injury plays a key role in the development of HCC. To investigate the risk of HCC in patients with varying degrees of inflammation, we followed up a total of 2087 patients in this study and found that the incidence of hepatocarcinogenesis progressively increased as the stages increased sequentially from G1 to G4 ($P<0.001$). The risk of hepatocarcinogenesis was also associated with the age of the patient; the albumin (ALB), glutamyltranspeptidase (GGT), and platelet (PLT) levels; and the prothrombin time (PT). Immunohistochemical analysis demonstrated that the DNA damage response progressively increased as the inflammation degree progressed (G1-G4) ($P<0.05$). Furthermore our results showed γ -H2AX was dramatically up-regulated in HCC tissues compared with adjacent normal tissues ($P<0.001$) and was closely correlated with poor outcomes ($P<0.001$). These findings provide pathological evidence that a persistent chronic inflammation-related DNA damage response might be a driving force of HCC. Based on these findings, the DNA damage response might be considered a promising diagnostic marker for identifying potential malignant transformation in Hepatitis B at the early stage. Patients with poor liver function parameters should receive active anti-viral and liver-protective therapy and be closely monitored.

Keywords: DNA damage response (DDR), γ -H2AX, hepatocellular carcinoma (HCC), inflammatory, hepatocarcinogenesis

Introduction

Hepatocellular carcinoma (HCC) is one of the most common malignant tumors with the worst outcomes [1]. Epidemiological studies have shown that 90% of HCC patients in China are infected with hepatitis B virus (HBV) [2, 3], and the incidence of HCC is 100-fold higher in persistent hepatitis B surface antigen (HBs-Ag)-positive carriers than in non-carriers. Furthermore, the geographic distribution of HBV carriers is concordant with the prevalence of HCC [4, 5], indicating a close relationship between HCC and hepatitis B [6].

HBV infection may cause chronic liver injury and necrotic inflammation [7], wherein persistent chronic injury contributes to repeated liver cell proliferation and repair and ultimately HCC [8]. Inflammatory injury is one of the important components of the tumor microenvironment, which plays an oncogenic role in HCC [9, 10].

The inflammatory injury of HBV can be divided into four grades (G1-G4) (The guideline of prevention and treatment for chronic hepatitis B) [11]. Investigation of the relevant mechanisms of chronic inflammation injury-related tumor development is needed. However, it is unknown how the risks of HCC vary with grades of inflammation injury, and the mechanisms are unclear.

Persistent chronic inflammatory injury can cause DNA damage [12]. DNA damage has different representations, of which DNA double-strand breaks (DSBs) are considered the most severe [13]. DSBs induce a series of stress responses, of which the primary response is the ataxia telangiectasia mutated (ATM)-initiated signaling cascade that causes cell cycle arrest until DSB repair. H2AX, a key protein involved in the ATM-initiated signaling cascade, can be phosphorylated to γ -H2AX by ATM [14]. γ -H2AX is the key factor that initiates DSB repair; it secures broken DNA, rapidly recruits a

Chronic inflammation injury promotes HCC development

large number of repair-related proteins and signaling molecules involved in DNA repair, and plays an important role in initial injury identification, signal transduction, and DNA repair [15]. An elegant study revealed that changes in γ -H2AX expression reflect DNA damage [16]. However, it is not certain whether HBV-induced chronic liver inflammatory injury can cause changes in γ -H2AX and whether the severity of chronic inflammatory injury is related to the γ -H2AX expression level.

Today, the causal relationship between HBV and HCC is more widely accepted [17, 18]. However, the underlying molecular mechanisms mediating the HBV promotion of HCC remain to be elucidated [19]. In this study, we explore the relationship between different grades of inflammation and the risk of HCC. We also determined the expression of γ -H2AX in chronic injury tissues and HCC tissues to evaluate the DNA damage response status. The present study revealed that the DNA damage response correlated with the severity of chronic inflammation and may be a driving force in the development of HCC, suggesting a pivotal role of the chronic inflammation-related DNA damage response in hepatocarcinogenesis.

Materials and methods

Clinical data and specimens

We followed up patients with chronic hepatitis B infection confirmed and treated at the Third Affiliated Hospital of Sun Yat-sen University between January 2004 and October 2014. Each patient underwent a liver tissue biopsy during hospitalization. The biopsy specimens were subjected to hematoxylin and eosin (HE) staining, and the severity of inflammation was evaluated by a pathologist. We followed up the patients via a phone call, outpatient visit, or a search of the medical records for readmission information. Information such as patient treatment and HCC was collected and recorded. The follow-up start time was the time of liver biopsy after admission, and the end time was the occurrence of HCC or the study end date. "Lost to follow-up" was defined as an inability to follow-up due to changes in contact information or patient death as a result of other illnesses. The patients were followed up through March 26, 2015. The inclusion criterion was patients with chronic hepatitis B confirmed by a liver biopsy

(HBsAg and/or HBV DNA-positive patients with a history of hepatitis B or HBsAg positivity for more than 6 months were considered to have a chronic HBV infection). The exclusion criteria were as follows: patients infected with a hepatitis virus infection other than HBV, patients with alcoholic liver disease, or patients with autoimmune liver disease. The study was approved by the Medical Ethics Committee, and each patient signed the informed consent form prior to inclusion in the study.

Group assignment: The patients were assigned into one of four groups (G1, G2, G3, or G4) based on the severity of the liver inflammatory injury.

Pathological specimens were collected from patients undergoing radical resection of HCC at the Third Affiliated Hospital of Sun Yat-sen University between February 2008 and December 2010, including HCC tissue, corresponding paracancerous tissue (≤ 2 cm away from the HCC tissue), and normal tissue specimens (>5 cm away from the HCC tissue). This study was approved by the Medical Ethics Committee, and each patient signed the informed consent form prior to the study. The pathological specimens were subjected to HE staining, and the severity of inflammation of the non-cancerous liver tissues (including the normal and paracancerous tissues) was evaluated by a pathologist.

Liver biopsy

Under the guidance of ultrasound B, a Bard biopsy needle (HS 18G) was used to perform the percutaneous biopsy and remove 1.0 to 2.5 cm of liver tissue. The liver tissue was fixed in 10% neutral formalin, routinely dehydrated and embedded in paraffin, sectioned, HE stained, and then evaluated by a pathologist to classify the severity of liver inflammation according to the Guidelines for the Prevention and Treatment of Chronic Hepatitis B [11].

HE staining

Paraffin-embedded human liver tissue specimens were serially sectioned into 4- μ m-thick sections, which were attached to slides in cold water and placed in a 60°C oven for 3 hours. Next, the slides were dewaxed in xylene and hydrated in a continuous ethanol gradient (100%, 95%, 80%, and 65% ethanol, suc-

Chronic inflammation injury promotes HCC development

Table 1. Clinical characteristics of patients in different group

Variable	No HCC	HCC	P value
Age (years) ¹	35.3±9.2	40.0±8.8	0.002
ALB (g/L) ¹	43.7±4.0	41.6±4.8	0.002
GGT (IU/L) ¹	68.3±99.1	144.4±174.2	0.011
ALP (IU/L) ¹	75.5±26.9	106.3±99.4	0.064
AST (IU/L) (%) ¹	93.3±173.4	77.4±79.2	0.575
ALT (IU/L) (%) ¹	140.8±282.3	107.0±115.8	0.461
WBC (10 ⁹ /L) ¹	5.8±1.7	5.6±2.3	0.415
Hb (g/L) ¹	143.9±15.4	140.3±24.3	0.369
PLT (10 ⁹ /L) ¹	185.8±51.9	156.2±63.2	0.001
PT (sec) ¹	13.4±1.2	14.0±1.9	0.003
HBeAg (%) ²			0.087
Negative	730 (46.5%)	23 (60.5%)	
Positive	840 (53.5%)	15 (39.5%)	
HBVDNA (%) ²			0.369
<2000 IU/mL	389 (24.8%)	7 (18.4%)	
≥2000 IU/mL	1181 (75.2%)	31 (81.6%)	
The degree of inflammation (%) ²			<0.001
G1	592 (37.7%)	2 (5.3%)	
G2	504 (32.1%)	12 (31.6%)	
G3	346 (22.0%)	21 (55.3%)	
G4	128 (8.2%)	3 (7.9%)	
Gender (%) ²			0.065
Male	1257 (80.1%)	35 (92.1%)	
Female	313 (19.9%)	3 (7.9%)	

¹Continuous variables are presented as mean and standard deviation as examined by Independent Samples t-test. ²Categorical variables are expressed as counts and percentages as examined by Chi-square test. P value <0.05 was considered to indicate statistical significance.

cessively). After a rinse with tap water, the slides were stained with hematoxylin for 4 minutes and then with eosin for 90 seconds, dehydrated in a continuous ethanol gradient (65%, 80%, 95%, and 100% ethanol, successively), rendered transparent with xylene, and mounted with neutral resin. The finished slides were observed and photographed under a microscope. The nuclei were stained bright blue by hematoxylin, and the cytoplasm was stained varying shades of pink to peach red by eosin.

Western blotting

Liver tissues were lysed in RIPA buffer in the presence of 10 µg/mL protease inhibitors, 1 µg/mL aprotinin, 1 µg/mL leupeptin, and 1 µg/mL pepstatin. Lysates were cleared by centrifugation, and the supernatants containing 35 µg of protein were electrophoresed on 15% sodium dodecyl sulfate (SDS)-polyacrylamide

gels. Proteins were separated using SDS-polyacrylamide gel electrophoresis and transferred to polyvinylidene difluoride (PVDF) membranes. This membrane was immunoblotted with antibodies against γ-H2AX (1:1000, Cell Signaling) and GAPDH (1:1000, Sigma-Aldrich). Immunoreactive proteins were visualized using ECL reagents (Roche) following the manufacturer's instructions.

Immunohistochemistry

Paraffin-embedded human liver tissue specimens were serially sectioned into 4-µm-thick sections, which were attached to slides in cold water and then placed in a 60°C oven for 3 hours. Next, the slides were dewaxed in xylene, hydrated in a continuous ethanol gradient, and placed in 3% hydrogen peroxide to deactivate endogenous peroxidase. The slides were transferred to 10 mmol citrate buffer (pH=6.0) and placed in a microwave for antigen retrieval at low heat

for 20 minutes. After the slides were cooled for 30 minutes, rabbit anti-human γ-H2AX monoclonal antibody (ab81299, 1:150) was added to the slides for incubation at 4°C overnight. The next day, the slides were placed at room temperature for approximately 1 hour, followed by a phosphate-buffered saline with Tween 20 (PBST) wash (three washes, 5 minutes each). Next, a horseradish peroxidase (HRP)-labeled secondary antibody (Dako) was added, and the slides were incubated at 37°C for 30 minutes. After a PBS wash, 3,3'-diaminobenzidine (DAB) was added for staining (8-12 minutes). Finally, after hematoxylin restaining for 1 minute and PBS destaining, the slides were dried, mounted with neutral resin, and observed and photographed under a microscope. The brown cells observed under the microscope were considered positive. The Image-Pro Plus 6.0 software was used to calculate the number of positive cells and the total number of nuclei (cells) in the

Chronic inflammation injury promotes HCC development

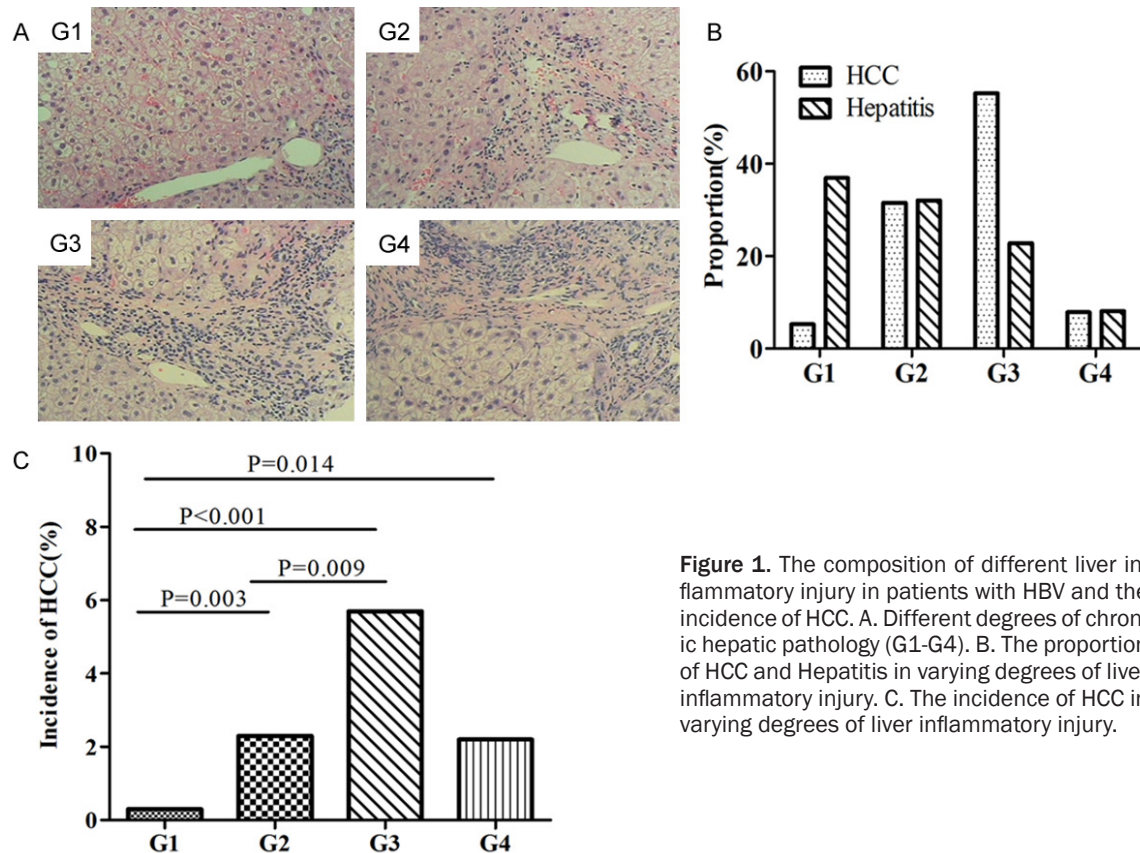


Figure 1. The composition of different liver inflammatory injury in patients with HBV and the incidence of HCC. A. Different degrees of chronic hepatic pathology (G1-G4). B. The proportion of HCC and Hepatitis in varying degrees of liver inflammatory injury. C. The incidence of HCC in varying degrees of liver inflammatory injury.

image. Positive percentage = the number of positive cells/total number of cells $\times 100\%$.

Statistical analysis

The SPSS 20.0 statistical package was used for the statistical analysis. Continuous variables are expressed as the mean \pm standard deviation and were analyzed with one-way analysis of variance (ANOVA), the Kruskal-Wallis rank sum test, and the Bonferroni method (for multiple comparisons). Categorical variables were analyzed with the Chi-square test. Multivariate analysis was performed using Cox's proportional hazard model. Survival curves were estimated by applying the Kaplan-Meier analysis, and the log-rank test was used to compare survival between the two groups. $P < 0.05$ was considered statistically significant. All P values were two-sided.

Results

Risk of HCC is associated with the severity of chronic inflammation

We followed up 2,087 patients with chronic hepatitis B for 4 to 135 months (median 52

months), of whom 479 patients were lost to follow-up or had an unknown diagnosis. Thus, complete follow-up data were available for 1,608 patients (**Table 1**). Representative images of varying degrees of liver inflammatory injury diagnosed by liver biopsy are shown in **Figure 1A**. At the end of follow-up, a total of 38 patients (2.4%) developed HCC. The degree of inflammatory damage in liver cancer and hepatitis causes a substantial difference in this percent (**Figure 1B**). A significant difference in the HCC incidence was observed among the four groups ($P < 0.05$) (**Figure 1C**), suggesting that more severe liver inflammatory injury was associated with a higher risk of HCC.

Clinical characteristics in patients with varying degrees of liver inflammatory injury

The patients' characteristics are shown in **Table 2**. More severe liver inflammatory injury was associated with higher gamma-glutamyl transferase (GGT), alkaline phosphatase (ALP), aspartate aminotransferase (AST), and alanine aminotransferase (ALT) levels (indicators of liver injury); a lower albumin (ALB) level and

Chronic inflammation injury promotes HCC development

Table 2. Clinical characteristics of varying degrees of liver inflammatory injury in all patients

Variable	G1	G2	G3	G4	P value
Age (years) ¹	34.8±9.2	35.2±9.3	36.1±9.1	37.3±9.8	0.017
ALB (g/L) ¹	45.4±3.1	43.9±3.8	42.1±4.3	40.1±4.6	<0.001
GGT (IU/L) ¹	37.6±82.3	57.0±79.1	116.0±130.3	140.3±95.3	<0.001
ALP (IU/L) ²	68.3±22.2	71.6±21.6	88.1±44.8	96.9±29.6	<0.001
AST (IU/L) (%) ¹	39.0±58.1	74.0±136.1	160.8±237.9	221.4±268.8	<0.001
ALT (IU/L) (%) ¹	60.0±137.3	117.8±239.5	244.0±381.6	299.2±395.1	<0.001
WBC (10 ⁹ /L) ¹	6.0±1.6	5.9±1.6	5.6±1.7	5.7±2.1	0.002
Hb (g/L) ¹	145.5±15.0	144.3±15.0	142.3±17.3	138.7±15.4	<0.001
PLT (10 ⁹ /L) ¹	202.4±48.3	186.9±50.4	167.2±51.5	149.3±46.3	<0.001
PT (sec) ¹	13.0±0.8	13.3±1.0	13.8±1.4	14.6±1.6	<0.001
Gender (%) ²					0.001
Male	460 (77.4%)	402 (77.9%)	314 (85.6%)	116 (88.5%)	
Female	134 (22.6%)	114 (22.1%)	53 (14.4%)	15 (11.5%)	
HBeAg (%) ²					0.001
Negative	316 (53.2%)	220 (42.6%)	160 (43.6%)	57 (43.5%)	
Positive	278 (46.8%)	296 (57.4%)	207 (56.4%)	74 (56.5%)	
HBV (%) ²					<0.001
<2000 IU/mL	220 (37.0%)	106 (20.5%)	50 (13.6%)	20 (15.3%)	
≥2000 IU/mL	374 (63.0%)	410 (79.5%)	317 (86.4%)	111 (84.7%)	

¹Continuous variables are presented as mean and standard deviation as examined by Independent Samples t-test. ²Categorical variables are expressed as counts and percentages as examined by Chi-square test. P value <0.05 was considered to indicate statistical significance.

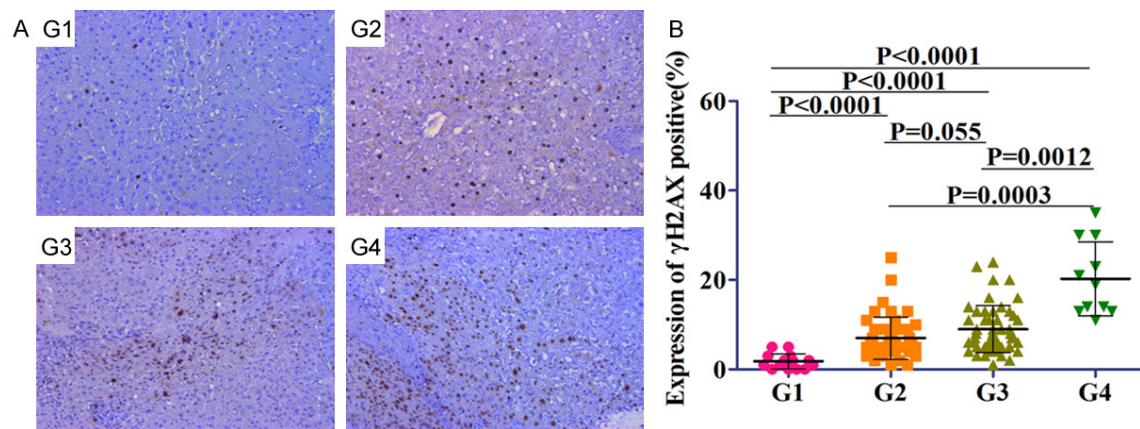


Figure 2. The expression of γ -H2AX in varying degrees of liver inflammatory injury. A. Representative images of γ -H2AX staining in tissues with different stage of inflammation (G1-G4). B. Quantification of γ -H2AX positive cells in tissues with different stage of inflammation (G1-G4) from 60 HCC patients (two non-malignant samples from each patient).

longer prothrombin time (PT) (indicators of the synthesis function of liver cells); and a higher HBV DNA concentration.

γ -H2AX expression is positively correlated with the severity of chronic inflammation

We examined the γ -H2AX expression in chronic hepatitis B liver tissues (including 120 normal

or paracancerous tissue specimens) with varying degrees of inflammatory injury. The strongest and most abundant immunostaining for γ -H2AX was observed in epithelial cells corresponding to high-grade chronic inflammation. A less intense γ -H2AX signal was found in samples with low-grade inflammation (**Figure 2A**). Intriguingly, semiquantification analysis for γ -H2AX revealed a significant increase in γ -H2AX

Chronic inflammation injury promotes HCC development

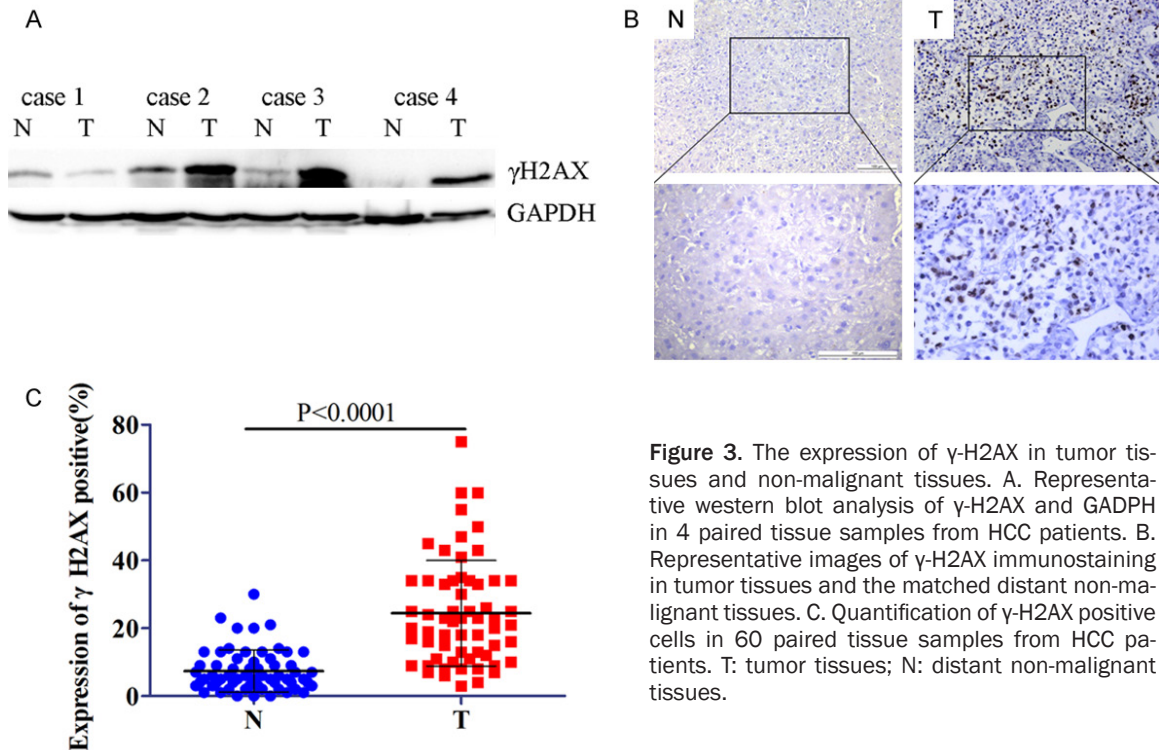


Figure 3. The expression of γ -H2AX in tumor tissues and non-malignant tissues. **A.** Representative western blot analysis of γ -H2AX and GAPDH in 4 paired tissue samples from HCC patients. **B.** Representative images of γ -H2AX immunostaining in tumor tissues and the matched distant non-malignant tissues. **C.** Quantification of γ -H2AX positive cells in 60 paired tissue samples from HCC patients. T: tumor tissues; N: distant non-malignant tissues.

staining in tissues with severe chronic inflammation than in mild inflammation tissues (G1: 1.8 ± 1.7 , G2: 7.0 ± 4.7 , G3: 9.0 ± 5.2 , and G4: 20.3 ± 7.9) (**Figure 2B**), suggesting that elevated DNA damage might be induced by inflammatory injury, which eventually proceeds to carcinogenesis through genomic instability.

γ -H2AX expression is increased in human HCC tissue samples

We examined the γ -H2AX expression in HCC tissues and the matched distant non-malignant tissues taken from 60 HCC patients. Both Western blotting and immunohistochemical staining showed significantly higher γ -H2AX expression in the HCC tissues than in the distant non-malignant tissues (**Figure 3A, 3B**). The relative expression levels were 24.7 ± 15.6 in the HCC tissues and 7.4 ± 6.2 in the distant non-malignant tissues, which were standardized by endogenous GAPDH ($P < 0.0001$) (**Figure 3C**).

Relationship between γ -H2AX expression and clinicopathological factors in patients with HCC

The histological findings for the HCC samples in the 60 studied patients are shown in **Table 3**. The patients were classified into two groups

according to the ratio of the mean levels of γ -H2AX expression in tumor tissues compared with the matched distant non-malignant tissues: a high γ -H2AX group ($n=30$) and a low γ -H2AX group ($n=30$) (**Figure 4A**). Clinicopathological features were compared between the two groups (**Table 3**). Compared to the low- γ -H2AX group, the high γ -H2AX group had a significantly larger tumor size ($P=0.001$), a higher Child-Pugh class ($P=0.008$), more macrovascular invasion ($P=0.015$), and poorer differentiation ($P=0.042$). However, the γ -H2AX expression levels were not associated with other clinical parameters such as gender ($P=0.421$) and age ($P=0.795$) (**Table 3**).

γ -H2AX expression is an independent risk factor for patient survival

Univariate analysis for Overall survival (OS) was performed with the following factors: γ -H2AX, age, sex, alpha-fetoprotein (AFP) level, Child-Pugh class, number of nodules, largest tumor size, histological differentiation, and macrovascular invasion. The survival features are summarized in **Table 4**. Patients with high γ -H2AX expression levels had a shorter OS than those with low γ -H2AX expression ($P=0.001$). OS cur-

Chronic inflammation injury promotes HCC development

Table 3. Correlation between γ -H2AX expression and clinicopathological characteristics in patients with HCC

Parameter clinica	Number of cases (%)	γ -H2AX		P value
		High-expression group no. of cases	Low-expression group no. of cases	
Total number	60	30	30	
Age (years)				0.795
<50	33 (55.0)	16	17	
\geq 50	27 (45.0)	14	13	
Gender				0.421
Male	53 (88.3)	25	28	
Female	7 (11.7)	5	2	
HBeAg				0.598
Negative	46 (76.7)	24	22	
Positive	14 (23.3)	6	8	
HBVDNA (IU/mL)				0.292
<2000	36 (58.3)	17	19	
\geq 2000	24 (41.7)	13	11	
Number of nodules				1.000
Single	50 (83.3)	25	25	
\geq 2	10 (16.7)	5	5	
Largest tumor size				0.001
\leq 3 cm	23 (38.3)	6	17	
3-5 cm	19 (31.7)	9	10	
>5 cm	18 (30.0)	15	3	
Macrovascular invasion				0.015
No	46 (76.7)	19	27	
Yes	14 (23.3)	11	3	
Child-Pugh class				0.008
A	52 (86.7)	22	30	
B	8 (13.3)	8	0	
Differentiation				0.042
Well	12 (20.0)	4	8	
Moderately	43 (71.7)	21	22	
Poorly	5 (8.3)	5	0	
AFP				0.260
<400 ng/ml	42 (70.0)	19	23	
\geq 400 ng/ml	18 (30.0)	11	7	

Categorical variables are expressed as counts and percentages as examined by Chi-square test. *P* value <0.05 was considered to indicate statistical significance.

ves were evaluated with the γ -H2AX expression level by the Kaplan-Meier analysis and log-rank test; the results are presented in **Figure 4B**. Multivariate analysis using the Cox proportional-hazards model showed that γ -H2AX expression was an independent prognostic factor associated with OS time after surgery (hazard ratio, 3.674; 95% confidence interval (CI), 1.426-9.471; *P*=0.007; **Table 4**).

Discussion

HCC is one of the most prevalent and lethal cancers with the worst prognosis worldwide [20]. Most HCC patients have persistent HBV infection [21, 22]. Numerous studies have shown that HBV-induced liver inflammatory injury is closely related to HCC [23], but how the HBV-induced damage to liver cells is related to

Chronic inflammation injury promotes HCC development

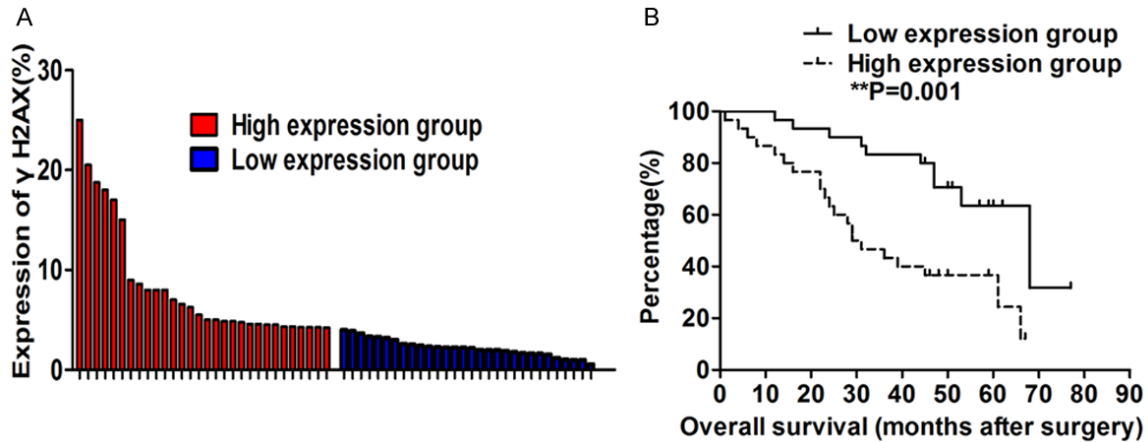


Figure 4. Relative expression of γ -H2AX in human HCC tissues (n=60) compared with corresponding normal adjacent tissues (n=60) and its clinical significance. A. The expression of γ -H2AX was examined by immunostaining. Data are presented as fold change in tumor tissues relative to normal tissues. The blue and red as γ -H2AX expression in 60 tumor tissue samples. According to the median ratio of relative γ -H2AX expression in tumor tissues, γ -H2AX expression was classified into two groups: relatively high- γ -H2AX group (n=30, red column) and relatively low- γ -H2AX group (n=30, blue column). B. Kaplan-Meier disease-free survival and overall survival (OS) curves according to γ -H2AX expression level.

Table 4. Univariate and multivariate analysis of the factors associated with overall survival

Factors	Univariate analysis		Multivariate analysis (Cox)		
	P value	P value	Hazaed ratio	95% CI	
γ -H2AX	0.001	0.007	3.674	1.426	9.471
Age	0.012	0.142	0.507	0.205	1.256
Gender	0.664	0.182	0.330	0.065	1.682
HBeAg	0.439	0.971	1.018	0.390	2.656
HBVDNA	0.621	0.667	1.202	0.520	2.783
Number of nodules	0.616	0.214	2.054	0.660	6.394
Largest tumor size	0.154	0.320	0.747	0.420	1.328
Macrovascular invasion	0.02	0.013	4.450	1.373	14.430
Child-Pugh class	0.005	0.544	1.484	0.414	5.316
Differentiation	0.09	0.281	1.667	0.659	4.219
AFP	0.647	0.818	0.879	0.292	2.645

inflammation damage degree is unclear [24]. Not all HBV infection can cause HCC. In this study, our follow-up data showed a significant difference in the HCC incidence was among the four groups and was significantly higher in HBV patients with severe liver inflammatory injuries than in patients with mild liver inflammatory injuries. The results provide a new avenue for studying HCC. Additionally, we followed up the clinical parameters of patients. The results showed that more severe liver inflammatory injury was associated with higher GGT, ALP, AST, and ALT levels (indicators of liver injury); a lower ALB level and longer PT (indicators of

the synthesis function of liver cells); and a higher HBV DNA concentration. It is suggested that patients with poor liver function parameters should receive active anti-viral and liver-protective therapy and be closely monitored to enable early detection of HCC [25]. The results prompt us to seek the underlying mechanisms connecting chronic inflammation injury and HCC.

We determined the expression of γ -H2AX in chronic injury tissues and HCC tissues to evaluate the DNA damage response status (the emergence of DNA damage response is likely to be induced by chronic inflammation [26]).

Chronic inflammation injury promotes HCC development

This study showed that HBV-induced chronic liver inflammatory injury can cause the DNA damage response. Furthermore, the level of the DNA damage response was associated with the severity of chronic inflammation. These results suggest that DNA damage beyond a certain level of severity may cause cancer. Moreover, the γ -H2AX expression was significantly higher in HCC tissues than in paracancerous tissues, and closely correlated with patient outcomes. The clinical data suggest a significant correlation between γ -H2AX and tumor size, Child-Pugh class, differentiation, and macrovascular invasion. Additionally HCC tissues with high γ -H2AX expression had worse overall or tumor-free survival than those with low expression.

The inflammation-related NF-KB pathway can activate the mTOR pathway and thus regulate the DNA damage response [27], supporting our observations of a higher level of DNA damage response in inflamed tissues [28]. Genetic changes related to DNA damage can promote the DNA repair response [29], but inappropriate injury repair can drive endless cycles of cell apoptosis and regeneration [30]. Our results showed that DNA damage response levels were associated with hepatocarcinogenesis, and the γ -H2AX expression was significantly higher in HCC tissues than in paracancerous tissues, indicating that increased chronic inflammatory injury can cause more certain genetic changes, ultimately leading to abnormal proliferation and the development of nodules and HCC [31]. Furthermore, the result clearly demonstrates the prognostic value of γ -H2AX expression in HCC patients. These results provide the first evidence supporting that γ -H2AX could be a novel marker in the prognosis of HCC after surgery and a potential therapeutic target.

In summary, the DNA damage response correlated with the severity of chronic inflammation and plays a critical role in the development of HCC. Moreover the incidence of HCC progressively increased in the sequential stages. Therefore, we supposed that DNA damage serves as the intermediate to connect chronic inflammation injury and HCC, and it may be a driving force. Therefore, the DNA damage response might be considered a promising diagnostic marker for identifying potential malignant transformation in Hepatitis B at the early stage, and patients with poor liver func-

tion parameters should receive active anti-viral and liver-protective therapy and be closely monitored.

Disclosure of conflict of interest

None.

Address correspondence to: Dr. Wei-Dong Pan, Department of Hepatobiliary Surgery, The Third Affiliated Hospital of Sun Yat-sen University, Guangzhou 510630, China. Tel: +86-13925032539; E-mail: panwd@mail.sysu.edu.cn

References

- [1] Zuo TT, Zheng RS, Zhang SW, Zeng HM and Chen WQ. Incidence and mortality of liver cancer in China in 2011. *Chin J Cancer* 2015; 34: 508-513.
- [2] Turati F, Edefonti V, Talamini R, Ferraroni M, Malvezzi M, Bravi F, Franceschi S, Montella M, Polesel J, Zucchetto A, La Vecchia C, Negri E and Decarli A. Family history of liver cancer and hepatocellular carcinoma. *Hepatology* 2012; 55: 1416-1425.
- [3] Lin XJ, Lao XM, Shi M and Li SP. Changes of HBV DNA after chemoembolization for hepatocellular carcinoma and the efficacy of antiviral treatment. *Dig Dis Sci* 2016; 61: 2465-2476.
- [4] Hanto DW, Curry MP, Sun M and Nasser I. Hepatocellular carcinoma (HCC) in a patient with hepatitis B virus (HBV) infection. *Am J Transplant* 2012; 12: 786-787; quiz 788.
- [5] Coppola N, Onorato L, Iodice V, Starace M, Minichini C, Farella N, Liorre G, Filippini P, Sagnelli E and de Stefano G. Occult HBV infection in HCC and cirrhotic tissue of HBsAg-negative patients: a virological and clinical study. *Oncotarget* 2016; 7: 62706-62714.
- [6] Wen LM, Wu WZ and Peng XC. Identifying significant pathways of hepatitis B virus-related hepatocellular carcinoma based on crosstalk and network pathways. *Genet Mol Res* 2016; 15.
- [7] Wang D and DuBois RN. Immunosuppression associated with chronic inflammation in the tumor microenvironment. *Carcinogenesis* 2015; 36: 1085-1093.
- [8] Guo JT, Zhou H, Liu C, Aldrich C, Saputelli J, Whitaker T, Barrasa MI, Mason WS and Seeger C. Apoptosis and regeneration of hepatocytes during recovery from transient hepadnavirus infections. *J Virol* 2000; 74: 1495-1505.
- [9] Landskron G, De la Fuente M, Thuwajit P, Thuwajit C and Hermoso MA. Chronic inflammation and cytokines in the tumor microenvironment. *J Immunol Res* 2014; 2014: 149185.
- [10] Wu Y, Kuang DM, Pan WD, Wan YL, Lao XM, Wang D, Li XF and Zheng L. Monocyte/macro-

Chronic inflammation injury promotes HCC development

- phage-elicited natural killer cell dysfunction in hepatocellular carcinoma is mediated by CD48/2B4 interactions. *Hepatology* 2013; 57: 1107-1116.
- [11] Chinese Society of Hepatology CMA, Chinese Society of Infectious Diseases CMA, Hou JL and Lai W. [The guideline of prevention and treatment for chronic hepatitis B: a 2015 update]. *Zhonghua Gan Zang Bing Za Zhi* 2015; 23: 888-905.
- [12] Piciocchi M, Cardin R, Cillo U, Vitale A, Cappon A, Mescoli C, Guido M, Rugge M, Burra P, Floreani A and Farinati F. Differential timing of oxidative DNA damage and telomere shortening in hepatitis C and B virus-related liver carcinogenesis. *Transl Res* 2016; 168: 122-133.
- [13] Tian H, Gao Z, Li H, Zhang B, Wang G, Zhang Q, Pei D and Zheng J. DNA damage response—a double-edged sword in cancer prevention and cancer therapy. *Cancer Lett* 2015; 358: 8-16.
- [14] Takahashi A, Mori E and Ohnishi T. The foci of DNA double strand break-recognition proteins localize with gammaH2AX after heat treatment. *J Radiat Res* 2010; 51: 91-95.
- [15] Karanika S, Karantanos T, Li L, Corn PG and Thompson TC. DNA damage response and prostate cancer: defects, regulation and therapeutic implications. *Oncogene* 2015; 34: 2815-2822.
- [16] Lin R, Xiao D, Guo Y, Tian D, Yun H, Chen D and Su M. Chronic inflammation-related DNA damage response: a driving force of gastric cardia carcinogenesis. *Oncotarget* 2015; 6: 2856-2864.
- [17] Sherman M, Kim RW and Dziura J. Risk scores for hepatocellular carcinoma in chronic hepatitis B. *Hepatology* 2015; 61: 1784-1786.
- [18] Papatheodoridis GV, Chan HL, Hansen BE, Janssen HL and Lampertico P. Risk of hepatocellular carcinoma in chronic hepatitis B: assessment and modification with current antiviral therapy. *J Hepatol* 2015; 62: 956-967.
- [19] Sinn DH, Lee J, Goo J, Kim K, Gwak GY, Paik YH, Choi MS, Lee JH, Koh KC, Yoo BC and Paik SW. Hepatocellular carcinoma risk in chronic hepatitis B virus-infected compensated cirrhosis patients with low viral load. *Hepatology* 2015; 62: 694-701.
- [20] Lei Y, Yee LW and Ping ZW. Target patients for partial hepatectomy and relationship between PLT and prognosis in BCLC B HCC. *J Hepatol* 2015; 62: 750.
- [21] Lau CC, Sun T, Ching AK, He M, Li JW, Wong AM, Co NN, Chan AW, Li PS, Lung RW, Tong JH, Lai PB, Chan HL, To KF, Chan TF and Wong N. Viral-human chimeric transcript predisposes risk to liver cancer development and progression. *Cancer Cell* 2014; 25: 335-349.
- [22] Xu J, Ding T, He Q, Yu XJ, Wu WC, Jia WH, Yun JP, Zhang Y, Shi M, Shao CK, Pan WD, Yin XY, Min J, Zhuang SM and Zheng L. An in situ molecular signature to predict early recurrence in hepatitis B virus-related hepatocellular carcinoma. *J Hepatol* 2012; 57: 313-321.
- [23] Schinzari V, Barnaba V and Piconese S. Chronic hepatitis B virus and hepatitis C virus infections and cancer: synergy between viral and host factors. *Clin Microbiol Infect* 2015; 21: 969-974.
- [24] Buitrago-Molina LE, Marhenke S, Longerich T, Sharma AD, Boukouris AE, Geffers R, Guigas B, Manns MP and Vogel A. The degree of liver injury determines the role of p21 in liver regeneration and hepatocarcinogenesis in mice. *Hepatology* 2013; 58: 1143-1152.
- [25] Mazzocchi G, Tarquini R, Valoriani A, Oben J, Vinciguerra M and Marra F. Management strategies for hepatocellular carcinoma: old certainties and new realities. *Clin Exp Med* 2016; 16: 243-256.
- [26] Matsuda Y and Ichida T. Impact of hepatitis B virus X protein on the DNA damage response during hepatocarcinogenesis. *Med Mol Morphol* 2009; 42: 138-142.
- [27] Guo F, Li J, Du W, Zhang S, O'Connor M, Thomas G, Kozma S, Zingarelli B, Pang Q and Zheng Y. mTOR regulates DNA damage response through NF-kappaB-mediated FANCD2 pathway in hematopoietic cells. *Leukemia* 2013; 27: 2040-2046.
- [28] Stefanou DT, Bamias A, Episkopou H, Kyrtopoulos SA, Likka M, Kalampokas T, Photiou S, Gavalas N, Sfikakis PP, Dimopoulos MA and Souliotis VL. Aberrant DNA damage response pathways may predict the outcome of platinum chemotherapy in ovarian cancer. *PLoS One* 2015; 10: e0117654.
- [29] Broustas CG and Lieberman HB. DNA damage response genes and the development of cancer metastasis. *Radiat Res* 2014; 181: 111-130.
- [30] Li X, Shu R, Filippatos G and Uhal BD. Apoptosis in lung injury and remodeling. *J Appl Physiol* (1985) 2004; 97: 1535-1542.
- [31] Antonelli G and Spagnoli GC. Why do infections cause cancer? *Clin Microbiol Infect* 2015; 21: 967-968.