

## Case Report

# Right adrenal lymphoma: a rare case report and review of literature

Weiwei Wang<sup>1</sup>, Xiaocong Zhou<sup>2</sup>, Yi Jiang<sup>3</sup>

<sup>1</sup>Department of Intensive Care Unit, The First Affiliated Hospital of Wenzhou Medical University, Wenzhou, Zhejiang, P. R. China; Departments of <sup>2</sup>Surgery, <sup>3</sup>Pathology, The Dingli Clinical Institute of Wenzhou Medical University (Wenzhou Central Hospital), Wenzhou, Zhejiang, P. R. China

Received March 16, 2017; Accepted April 21, 2017; Epub June 1, 2017; Published June 15, 2017

**Abstract:** Primary adrenal lymphoma (PAL) is rare although secondary involvement of malignant lymphoma into adrenal glands is common. Here, we reported a rare case of a 66-year-old female with unilateral adrenal incidentaloma which was finally diagnosed as primary adrenal non-germinal center B cell (non-GCB) subtype diffuse large B-cell lymphoma (DLBCL) coexisting intravascular involvement. Although the disease indicated poor prognosis, the patient in this case had remained free of disease with an excellent performance status for at least 2 years after received rituximab-containing chemotherapy. We concluded that early awareness of the possibility of PAL in patient with unilateral adrenal lesion that had no complications should be increased and rituximab-containing chemotherapy may be a reasonable treatment option for those patients.

**Keywords:** Adrenal incidentaloma, diffuse large B-cell lymphoma, intravascular lymphoma, non-GCB, primary adrenal lymphoma

### Introduction

Primary adrenal lymphoma (PAL) is rare although secondary involvement of malignant lymphoma into adrenal glands is common [1]. PAL often presents with bilateral tumors and can result in adrenal insufficiency [2, 3]. We reported here a rare case of silent non-germinal center B cell (non-GCB) subtype diffuse large B-cell lymphoma (DLBCL) with intravascular proliferation initially manifesting as a silent adrenal incidentaloma.

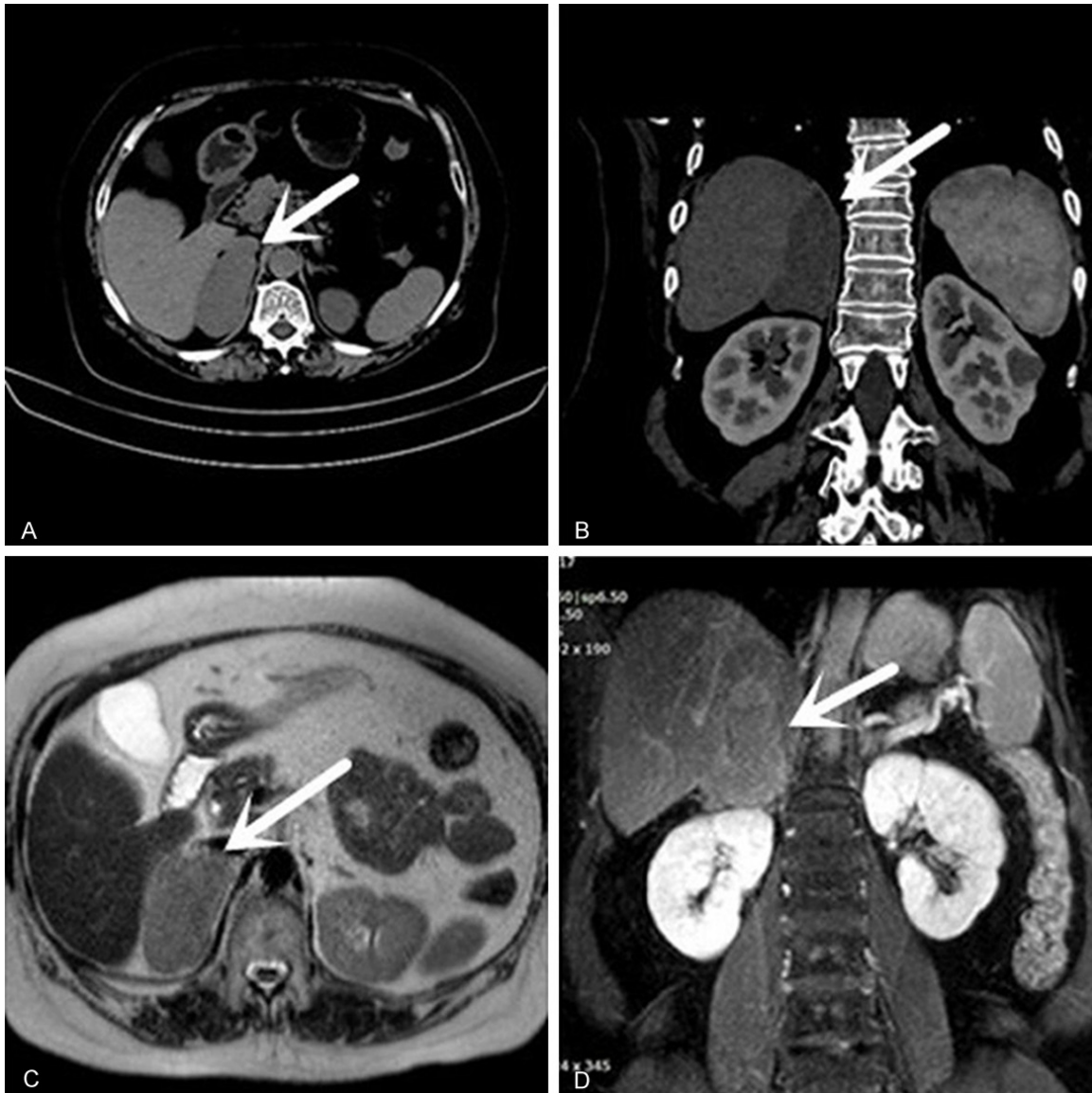
### Case report

A 66-year-old female was admitted to Wenzhou Central Hospital for further examination of right adrenal mass lesion, which was discovered incidentally by abdominal computerized tomography (CT) at a local hospital ten days ago, whereas her left adrenal gland was normal. She had a 2-year history of hypertension and took antihypertensive drugs regularly. Her blood pressure was well controlled during these two years. She denied any systemic symptoms such as fevers, night sweats, fatigue, pain, etc. On

physical examination, she was without cushingoid appearance and palpable lymph node enlargement. Laboratory examination showed no abnormality. Abdominal CT (**Figure 1A** and **1B**) showed an irregular well-defined and low-density mass measured 3.1 × 6.6 cm in the right adrenal gland which presented slightly heterogeneous enhancement after administration of contrast agent. Contrast-enhanced magnetic resonance imaging (MRI) showed the irregular abnormal signal characteristics of a well-defined 4.0 × 6.8 cm mass in the right adrenal gland, with equal or low signal intensity on T1-weighted sequence and slightly high signal intensity on T2-weighted sequence (**Figure 1C**). The mass presented slightly heterogeneous enhancement after administration of contrast agent (**Figure 1D**).

The patient underwent surgical resection of the mass in the right adrenal gland following the initial diagnosis due to the probability of malignancy. Macroscopic assessment of the resected specimen identified the presence of a 12.0 × 7.0 × 3.0 cm sized greyish-white mass with partial capsule. Final postoperative paraffin

## Right adrenal lymphoma

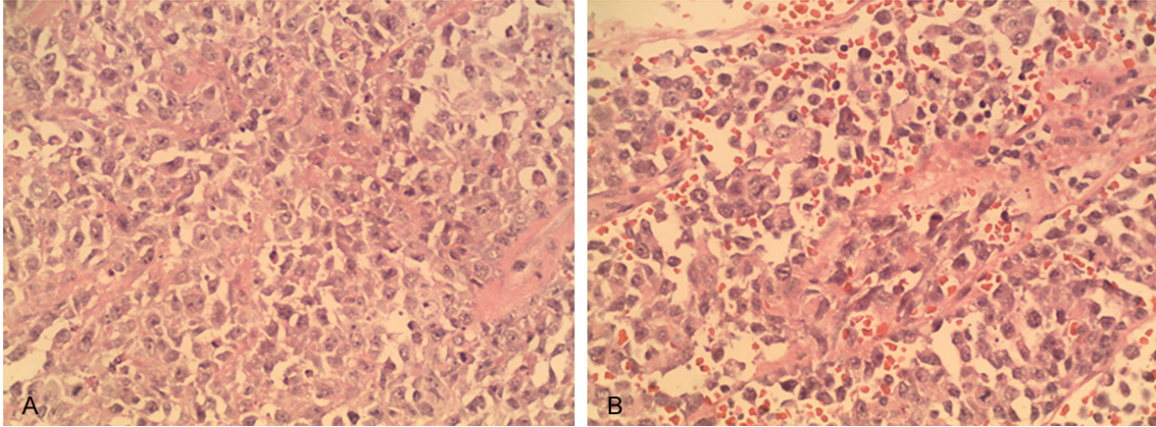


**Figure 1.** The imaging features of the disease. A, B. Abdominal CT showed an irregular well-defined and low-density mass measuring 3.1 × 6.6 cm in the right adrenal gland which presented slightly heterogeneous enhancement after administration of contrast agent. C, D. Contrast-enhanced MRI showed the irregular abnormal signal characteristics of a well-defined 4.0 × 6.8 cm mass in the right adrenal gland, with slightly high signal intensity on T2-weighted sequence. The mass presented slightly heterogeneous enhancement after administration of contrast agent.

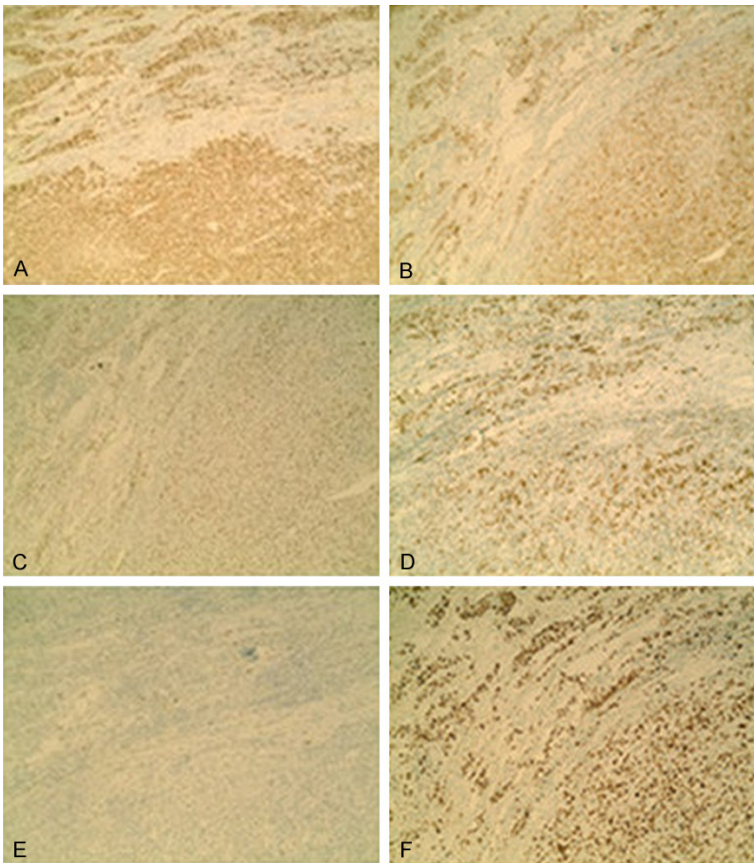
section revealed diffuse infiltration of large-sized neoplastic lymphoid cells not only replacing the normal adrenal structure (Figure 2A) but also partly proliferating into the lumens of small blood vessels (Figure 2B). These findings suggested the diagnosis of right adrenal lymphoma with intravascular proliferation. Immunohistochemistry staining showed that the tumor cells were positive for CD20 (Figure 3A), CD79a (Figure 3B), Bcl-6 (Figure 3C), Mum-1 (Figure 3D) and PAX-5, Vimentin, LCA, partly positive

for CD38 and CD56, but negative for CD3, CD30, CD10 (Figure 3E), CD138, Syn, CgA, S-100, Melan-A, inhibin-a, ALK, EMA, CK and EBER. The involved blood vessels were positive for CD34. As shown in Figure 3F, Ki-67 was strongly positive in tumor cells (Ki-67 index: 70%). B cell makers such as CD20 and CD79a were positive, indicating the diagnosis of DLBCL. The findings of CD10-, Bcl-6+, Mum-1+ could classify the case as non-germinal center B cell (non-GCB) subtype. Because of no other

## Right adrenal lymphoma



**Figure 2.** Microscopic views. On high-power view, (A) the mass was composed of large atypical lymphoid cells and (B) these cells partially spread into the lumens of blood vessels (Hematoxylin-eosin stain; original magnification  $\times 400$ ).



**Figure 3.** Immuno-histochemical examination of the resected specimen. B cell makers: (A) CD20 and (B) CD79a are positive. These staining: (C) Bcl-6(+), (D) Mum-1(+), (E) CD10(-) suggested non-GCB type of DLBCL. (F) Ki-67 was strongly positive in tumor cells (Ki-67 index: 70%).

organ involvement, the case above was diagnosed as primary unilateral adrenal non-GCB subtype diffuse large B-cell lymphoma with intravascular proliferation.

### Discussion

To the best of our knowledge, the case presented here is one very rarely reported in literature, showing silent non-GCB subtype diffuse large B-cell lymphoma coexisting intravascular involvement initially manifesting as a silent adrenal incidentaloma. The definitive diagnosis relies on histopathological examination and immune-histochemical characteristics of the lesion.

Adrenal incidentaloma is a term applied to an accidentally discovered adrenal mass on imaging performed for the investigation of an unrelated complaint [4]. Adrenal incidentalomas are a cluster of different pathologies, about 5% of which are malignant and others are benign ones [5]. The biggest diameter of Adrenal lesion is predictive factor of malignant tumor [6]. The incidence of malignant neoplasms is significantly higher for masses greater than 4 cm in size [5-7]. Surgical resection

should be considered if the diameter of unilateral adrenal mass is greater than 4 cm or is hormone-producing, especially for young patients. Fine needle biopsy or adrenalectomy

is used when a histological diagnosis is needed. In this case, surgical resection of the mass in the right adrenal gland was performed. A firm diagnosis of primary right adrenal non-GCB subtype diffuse large B-cell lymphoma coexisting intravascular involvement was established.

Intravascular lymphoma (IVL) is defined as an extra-nodal large B-cell lymphoma, characterized by the proliferation of atypical lymphoid cells in the lumens of small blood vessels in various organs without tendency to form tumors [8]. For this case, it couldn't be strictly defined as IVL. Thus, it was just diagnosed as DLBCL with intravascular proliferation.

The pathological subtype of DLBCL indicated poor prognosis [9]. Chemotherapy had been administered under the diagnosis above. The rituximab-containing chemotherapy, such as cyclophosphamide, doxorubicin, vincristine, prednisolone and rituximab (R-CHOP), has been found to be more efficacious than CHOP alone in DLBCL [10]. The patient received 6 cycles of R-CHOP regimen plus 3 additional rituximab only. She had remained free of disease with an excellent performance status for at least 2 years. Until we submitted this manuscript, the patient was still alive.

Due to the poor prognosis, early awareness of the possibility of PAL in patient with unilateral adrenal lesion that has no complications should be increased. R-CHOP chemotherapy regimen is a reasonable treatment option in DLBCL.

### Acknowledgements

This study was supported by grants from Medical and Health Technology Planning Project of Zhejiang Province (No. 2017KY622) and Technology Planning Projects of Wenzhou Science & Technology Bureau (No. Y20130383 and No. Y20150251).

### Disclosure of conflict of interest

None.

**Address correspondence to:** Dr. Xiaocong Zhou, Department of Surgery, The Dingli Clinical Institute of Wenzhou Medical University (Wenzhou Central Hospital), No. 32, Da Jian Lane, Wenzhou 325000, Zhejiang, P. R. China. Tel: 86-577-88053100; Fax: 86-577-88070100; E-mail: bobzxccc@163.com

### References

- [1] Horiguchi K, Hashimoto K, Hashizume M, Masuo T, Suto M, Okajo J, Handa H, Kaneko Y, Yokoo H, Sasaki A, Okada S, Yamada M, Tsukamoto N, Nojima Y, Nakazato Y, Mori M. Primary bilateral adrenal diffuse large B-cell lymphoma demonstrating adrenal failure. *Intern Med* 2010; 49: 2241-2246.
- [2] Grigg AP and Connors JM. Primary adrenal lymphoma. *Clin lymphoma* 2003; 4: 154-160.
- [3] Wang J, Sun NC, Renslo R, Chuang CC, Tabbarah HJ, Barajas L and French SW. Clinically silent primary adrenal lymphoma: a case report and review of the literature. *Am J Hematol* 1998; 58: 130-136.
- [4] Anagnostis P, Karagiannis A, Tziomalos K, Kakafika AI, Athyros VG, Mikhailidis DP. Adrenal incidentaloma: a diagnostic challenge. *Hormones (Athens)* 2009; 8: 163-184.
- [5] Barzon L, Sonino N, Fallo F, Palu G, Boscaro M. Prevalence and natural history of adrenal incidentalomas. *Eur J Endocrinol* 2003; 149: 273-285.
- [6] Angeli A, Osella G, Ali A, Terzolo M. Adrenal incidentaloma: an overview of clinical and epidemiological data from the National Italian Study Group. *Horm Res* 1997; 47: 279-283.
- [7] Mantero F, Terzolo M, Amaldi G, Osella G, Masini M, Ali A, Giovagnetti M, Opocher G and Angeli A. A survey on adrenal incidentaloma in Italy. Study group on adrenal tumors of the Italian society of endocrinology. *J Clin Endocrinol Metab* 2000; 85: 637-644.
- [8] Nakamura S, Ponzoni M and Campo E. Intravascular large B-cell lymphoma. Lyon, Franc: JARA Press; 2008.
- [9] Batlle A, González de Villambrosía S, Francisco M, Malatxeberria S, Sáez A, Montalbán C, Sanchez Verde L, García JF, González-Barca E and López A. Stratifying diffuse large B-cell lymphoma patients treated with chemoimmunotherapy: GCB/non-GCB by immunohistochemistry is still a robust and feasible marker. *Oncotarget* 2016; 7: 18036-18049.
- [10] Coiffier B, Lepage E, Briere J, Herbrecht R, Tilly H, Bouabdallah R, Morel P, Van Den Neste E, Salles G, Gaulard P, Reyes F, Lederlin P, Gisselbrecht C. CHOP chemotherapy plus rituximab compared with CHOP alone in elderly patients with diffuse large-B-cell lymphoma. *N Engl J Med* 2002; 346: 235-242.