

Original Article

The pathological appearance of hyaline droplets in Kupffer cells is not specific to patients with autoimmune hepatitis

Takashi Himoto¹, Kyuichi Kadota², Koji Fujita³, Takako Nomura³, Asahiro Morishita³, Hirohito Yoneyama³, Tsutomu Masaki³

¹Department of Medical Technology, Kagawa Prefectural University of Health Sciences, Kagawa, Japan; Departments of ²Diagnosis Pathology, ³Gastroenterology and Neurology, Kagawa University School of Medicine, Kagawa, Japan

Received April 19, 2017; Accepted June 21, 2017; Epub August 1, 2017; Published August 15, 2017

Abstract: The roles of Kupffer cells in the pathogenesis of autoimmune hepatitis (AIH) remain uncertain. In this study, pathological significance of hyaline droplets in Kupffer cells was investigated in patients with AIH, primary biliary cholangitis (PBC), AIH/PBC overlap syndrome, chronic hepatitis C (CH-C) and nonalcoholic steatohepatitis (NASH). Hyaline droplets in Kupffer cells were commonly observed in 14 of 22 (64%) patients with AIH and 4 of 4 (100%) patients with AIH/PBC overlap syndrome. However, the emergence of hyaline droplets in Kupffer cells was not associated with the severity of histological fibrosis or activity in patients with AIH. Serum immunoglobulin G (IgG) levels and titers of antinuclear antibodies (ANAs) did not affect the presence of hyaline droplets in Kupffer cells among AIH patients. Moreover, hyaline droplets in Kupffer cells were also present in eleven of 20 (55%) patients with PBC, four of 24 (17%) patients with CH-C and six of 15 (40%) patients with NASH. The existence of hyaline droplets in Kupffer cells was independent of serum IgG levels and seropositivity for ANAs in those subjects. These results suggest that the pathological appearance of hyaline droplets in Kupffer cells may not be specific to AIH, and that the emergence of hyaline droplets in Kupffer cells may be independent of autoimmune responses, including serum IgG levels and titers of ANAs, and hepatic fibrosis and activity in AIH patients. Further studies will be required to clarify the pathological relevance of hyaline droplets in Kupffer cells.

Keywords: Autoimmune hepatitis, hyaline droplet, Kupffer cells

Introduction

AIH, a chronic necro-inflammatory disease of the liver, is characterized by hypergammaglobulinemia, circulating autoantibodies including non-organ-specific and liver-specific autoantibodies, association with human leukocyte antigen (HLA)-DR3 or HLA-DR4, and a favorable response to immunosuppressive treatments [1]. A typical histological feature of AIH is piecemeal necrosis called "interface hepatitis". Lymphoplasmacytic infiltrates, hepatocyte rosette formation and emperipolesis are also considered histological characteristics of AIH [2]. However, the presence of interface hepatitis alone does not always lead to a clinical diagnosis of AIH. We often treat patients with non-autoimmune chronic liver disease that is

histologically associated with interface hepatitis, including chronic viral hepatitis and nonalcoholic steatohepatitis (NASH). Interface hepatitis is commonly observed in liver specimens of patients with primary biliary cholangitis (PBC). Moreover, non-organ-specific autoantibodies, including antinuclear antibody (ANA) and smooth muscle antibody (SMA), are frequently detected in the sera of patients with viral hepatitis, drug-induced hepatitis, nonalcoholic fatty liver disease (NAFLD), and alcoholic liver disease as well as autoimmune liver diseases [3].

Kupffer cells are the resident macrophages that localized in the hepatic sinusoid. They play a crucial role in innate and acquired immune responses [4]. Their localization in the hepatic

Hyaline droplets in Kupffer cells

sinusoid allows them to efficiently phagocytize a variety of pathogens entering from the portal vein or arterial circulations. They serve as a defense against particulates and immunoreactive materials passing from the gastrointestinal tract via portal circulation. Accordingly, modification or alteration of Kupffer cell function is closely associated with the pathogenesis of various kinds of liver diseases, including viral hepatitis, nonalcoholic fatty liver disease, alcoholic liver injury, intrahepatic cholestasis, and liver fibrosis [4].

Hyperplasia of Kupffer cells was primarily observed in patients with chronic hepatitis [5], although the role of Kupffer cells in the specific pathogenesis of AIH is not well understood. A previous report demonstrated immunoglobulin deposition within the cytoplasm of Kupffer cells in patients with AIH [6]. However, that study did not reveal the clinical relevance of immunoglobulin deposition in Kupffer cells of patients with chronic hepatitis as a whole.

Recently, Tucker and colleagues [7] described their observation of hyaline droplets within Kupffer cells of liver specimens in pediatric or juvenile patients with AIH. They emphasized that the hyaline droplets in Kupffer cells might become a novel pathological hallmark for distinguishing patients with AIH from those with other types of chronic hepatitis. Moreover, the authors revealed that AIH patients with hyaline droplets in Kupffer cells had significantly higher serum IgG levels than AIH patients without hyaline droplets.

However, hyaline droplets in Kupffer cells need to be confirmed in adult patients with AIH, because Tucker and colleagues [7] focused primarily on pediatric or juvenile patients with AIH in the article. Moreover, there is still some question whether or not the pathological appearance of hyaline droplets in Kupffer cells is specific to patients with AIH, although the authors assigned patients with chronic hepatitis B (CH-B) and patients with chronic hepatitis C (CH-C) to the comparison groups.

Kupffer cells have been shown to be necessary for the activation of hepatic stellate cells, which are the most important source of transforming growth factor- β (TGF- β) and platelet-derived growth factor (PDGF) [7]. Therefore, the association between the emergence of hyaline droplets in Kupffer cells and the severity

of hepatic fibrosis needs to be analyzed in patients with AIH.

The primary purposes of this study were to (i) confirm the prevalence of hyaline droplets in Kupffer cells of liver specimens in adult patients with AIH, (ii) to investigate the specificity for hyaline droplets in Kupffer cells of liver specimens in patients with AIH, and (iii) to identify clinico-pathological factors related to the emergence of hyaline droplets within Kupffer cells of liver specimens in patients with AIH.

Materials and methods

Study population

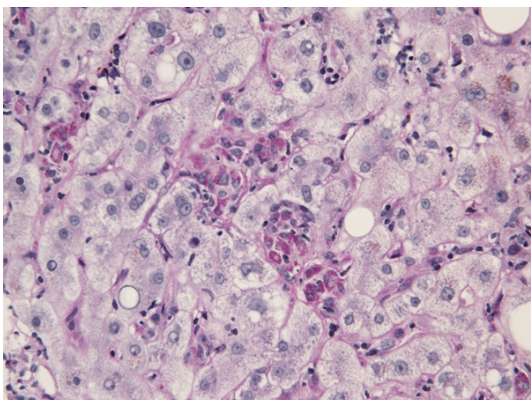
Twenty-two patients with type 1 AIH were randomly selected from the patients who admitted to the Hospital of Kagawa University School of Medicine, ranging in age from 30 to 84 years old. The enrolled AIH patients fulfilled the criteria for "definite" AIH in the revised scoring system [9] proposed by the International Autoimmune Hepatitis Group. Four patients with AIH/PBC overlap syndrome (AIH/PBC) were also enrolled in this study. Meanwhile, 20 patients with PBC, 24 patients with chronic CH-C and 15 patients with NASH were assigned to the comparison groups.

Clinical diagnosis of PBC was primarily based on the guideline for the management of PBC proposed by the Japan Society of Hepatology (JSH) [10], while patients who met the Paris Criteria were identified as AIH/PBC [11]. CH-C patients were diagnosed as having detectable serum HCV-RNA as determined by polymerase chain reaction (PCR) [12] and showing histological findings compatible with chronic hepatitis [13]. Pathological diagnosis of NASH was made using Matteoni's Classification [14]. The study protocol complied with all of the provisions of the Declaration of Helsinki. The design of this study was approved by the Ethical Committees of Kagawa Prefectural University of Health Sciences, and informed consent was obtained from each individual at entry.

Laboratory assessments

Serum alanine aminotransferase (ALT), total bilirubin (T-Bil), and immunoglobulin G (IgG) levels were determined by standard laboratory techniques. ANAs were determined by an indi-

Hyaline droplets in Kupffer cells



(PAS-Dstain, original magnification×400)

Figure 1. Detection of hyaline droplets in Kupffer cells by d-PAS staining.

rect immunofluorescent method, using HEp-2 cells as a substrate. Seropositivity for ANAs was defined as a titer of 1:40 or higher.

Histological assessments

Liver tissue specimens were obtained by liver biopsy under the guidance of ultrasound, using 16-gauge needles, before treatment. The tissue samples were fixed in 10% formalin and embedded in paraffin. The tissue sections were then stained with hematoxylin and eosin (H&E) and periodic acid Schiff (PAS) post-diastase (d-PAS) for the morphological evaluation. The severity of fibrosis and necroinflammation in the liver were graded in accordance with the New Inuyama Classification, a set of standard criteria for the histological assessment of chronic hepatitis in Japan [13] and the histological activity index (HAI) score designed by Knodell [15], respectively.

Statistical analysis

Data values are shown as means \pm standard deviations (SDs). The Mann-Whitney U-test was applied for comparisons of two groups. Fisher's exact probability test was used to compare differences in frequencies. *P* values of less than 0.05 were considered significant.

Results

The prevalence of hyaline droplets in Kupffer cells in patients with AIH

Hyaline droplets were present in the cytoplasm of Kupffer cells throughout the lobules. As

shown in **Figure 1**, hyaline droplets stained with d-PAS had a granular appearance in Kupffer cells. Hyaline droplets were identified in Kupffer cells of 14 of 22 (64%) liver specimens from patients with AIH. All four (100%) patients with AIH/PBC had hyaline droplets in their Kupffer cells. Therefore, overall prevalence of hyaline droplets within Kupffer cells in patients with AIH and AIH/PBC was 69%.

The prevalence of hyaline droplets in Kupffer cells in other subjects

The prevalence of hyaline droplets in Kupffer cells was also investigated in each of comparison group. Four of 24 (17%) patients with CH-C had hyaline droplets in Kupffer cells, indicating that the prevalence was lower in patients with CH-C than that in patients with AIH. In contrast, hyaline droplets in Kupffer cells were also found in eleven of 20 (55%) patients with PBC, and six of 15 (40%) patients with NASH (**Table 1**). These prevalences were not significantly different from that in AIH.

No correlations between the appearance of hyaline droplets in Kupffer cells and laboratory parameters in patients with AIH

Next, we investigated the correlation between the appearance of hyaline droplets in Kupffer cells and biochemical and immunological parameters in patients with AIH. As shown in **Table 2**, no significant differences in serum IgG levels or ANA titers were found between AIH patients with and without hyaline droplets in Kupffer cells. The presence of hyaline droplets in Kupffer cells was also independent of serum ALT and T-Bil levels in those patients (**Table 2**).

No correlation between the appearance of hyaline droplets in Kupffer cells and severity of hepatic fibrosis or histological activity in patients with AIH

The association between the emergence of hyaline droplets in Kupffer cells and the degree of hepatic fibrosis was analyzed in patients with AIH. The severity of hepatic fibrosis was approximately equivalent between the AIH patient groups with and without hyaline droplets in Kupffer cells (**Table 2**). With regard to histological activity, the difference in HAI score between the two groups was not significant (**Table 2**).

Hyaline droplets in Kupffer cells

Table 1. Prevalence of hyaline droplets in Kupffer cells in each subject

AIH (n=22)	AIH/PBC (n=4)	PBC (n=20)	CH-C (n=24)	NASH (n=15)
14 (64%)	4 (100%)	11 (55%)	4 (17%)	6 (40%)

AIH, autoimmune hepatitis; PBC, primary biliary cholangitis; AIH/PBS, AIH/PBC overlap syndrome; CH-C, chronic hepatitis C; NASH, nonalcoholic steatohepatitis.

Table 2. Comparisons of clinical parameters between groups of AIH patients with and without hyaline droplets in Kupffer cells

	Hyaline droplet-positive (n=14)	Hyaline droplet-negative (n=8)	p-value
IgG(mg/dl)	3,073±1,005	3,012±695	0.6822
ALT (U/l)	402±428	315±235	0.8378
T-Bil (mg/dl)	2.5±3.4	1.4±0.7	0.7579
Titer of ANA	1:20×2 ^{2.9±2.2}	1:20×2 ^{3.0±1.9}	0.8606
Fibrosis	2.36±0.75	2.38±0.74	0.7929
HAI score	14.2±2.2	15.4±2.7	0.2374

Table 3. Prevalence of hyaline droplets in Kupffer cells in ANA-positive and ANA-negative subjects

	Seropositive for ANA	Seronegative for ANA	p-value
PBC (n=20)	4/7 (57%)	7/13 (54%)	0.8876
CH-C (n=24)	2/11 (18%)	2/13 (15%)	0.8546
NASH (n=15)	0/6 (0%)	6/9 (68%)	0.0762

No correlation between the appearance of hyaline droplets in Kupffer cells and ANA status in other subjects

We examined the association of the appearance of hyaline droplets in Kupffer cells with autoimmune responses in comparison subjects. First, the relationships between the appearance of hyaline droplets in Kupffer cells and seropositivity for ANA were investigated in patients with PBC, CH-C and NASH. All AIH patients and AIH/PBC patients were seropositive for ANA. In contrast, seven of 20 (35%) patients with PBC, eleven of 24 (46%) patients with CH-C, six of 15 (40%) patients with NASH had ANA. There was no significant difference in the prevalence of hyaline droplets in Kupffer cells between ANA-positive and ANA-negative PBC patients (57% vs. 54%, $P=0.8642$, **Table 3**). The appearance of hyaline droplets in Kupffer cells was also independent of ANA status in patients with CH-C and NASH. Likewise,

no significant differences in serum IgG levels were found between hyaline droplet-positive and-negative groups among those subjects (data not shown).

Discussion

This present study found approximately the same prevalence of hyaline droplets in adult patients with AIH and AIH/PBC that previously found in pediatric or juvenile patients in those disease categories, indicating that hyaline droplets in Kupffer cells was a common feature of adult patients with AIH as well. However, unlike Tucker and colleagues' data, ours fell short of demonstrating that the presence of hyaline droplets in Kupffer cells was associated with serum IgG levels among patients with AIH, although Tucker and colleagues demonstrated that [7]. In addition, the existence of hyaline droplets in Kupffer cells was independent of seropositivity for ANA in patients with PBC, CH-C or NASH. These results may imply that the appearance of hyaline droplets within Kupffer cells does not reflect the extent of autoimmune responses in patients with chronic liver diseases.

Dysfunction of monocytes/macrophages is likely to play crucial roles in the pathogenesis of a variety of autoimmune diseases [16]. However, it is not well understood whether or not Kupffer cells are involved in the pathogenesis of AIH. It is of interest that Lin and colleagues [17] recently elucidated that alteration in the function of Kupffer cells might trigger the pathogenesis of AIH.

We hypothesized hyaline droplets in Kupffer cells would be associated with some kind of activation. Activated Kupffer cells might result in the facilitation of TGF- β and PDGF release which requires the proliferation of hepatic stellate cells and subsequently progresses to hepatic fibrosis. Hence, we speculated that the appearance of hyaline droplets in Kupffer cells might reflect advanced hepatic fibrosis in patients with AIH. Unexpectedly, the existence of hyaline droplets in Kupffer cells was not statistically associated with the progression of hepatic fibrosis in our AIH patients. Moreover, this study revealed that the presence of hyaline droplets in Kupffer cells of AIH patients was not

Hyaline droplets in Kupffer cells

associated with histological activity (grading), either.

To our surprise, hyaline droplets in Kupffer cells were frequently found in liver specimens from patients with PBC or NASH, as well. This result may indicate that the pathological presence of hyaline droplets in Kupffer cells is not specific to patients with AIH. Tucker and colleagues reported that the hyaline droplets in Kupffer cells were frequently observed in young patients with AIH, although they were rarely present in patients with CH-B or CH-C [7]. The authors speculated that the appearance of hyaline droplets in Kupffer cells might become a novel pathological hallmark for AIH. In contrast, our results showed that the prevalences of hyaline droplets in Kupffer cells in patients with PBC or NASH were approximately equivalent to that in adult patients with AIH. It has been widely recognized that ANAs are frequently detected in the sera of patients with PBC, NASH and CH-C [18-20]. Indeed, around 40% of those subjects had ANAs in the current study. However, the emergence of hyaline droplets in Kupffer cells was neither associated with ANA status nor serum IgG levels in those subjects.

Taking these data described above into consideration, we failed to demonstrate any specificity for the appearance of hyaline droplets in Kupffer cells of AIH patients, or any association with particular clinical characteristics of AIH patients. Further examinations will be required to clarify the pathological significance of hyaline droplets in Kupffer cells.

There are a few limitations in this study. Granular staining with d-PAS in Kupffer cells can be observed in lysosomal granules as well as in hyaline droplets. There is a possibility of occasionally misreading lysosomal granules as hyaline droplets in Kupffer cells. An immunohistochemical analysis using anti-CD68, a marker for macrophages, is able to discriminate hyaline droplets from lysosomal granules in Kupffer cells. Hyaline droplets in Kupffer cells are not usually stained with anti-CD68, while lysosomal granules are strongly positive for anti-CD68. Unfortunately, this immunohistochemical procedure was not performed in this study.

Tucker and colleagues revealed that IgG- or IgA-positive cytoplasmic globules which were

identical to hyaline droplets were observed in Kupffer cells [7]. However, we did not perform IgA or IgG immunohistochemistry in the liver specimens. Therefore, the correlation between serum IgG level and the degree of IgG deposits in Kupffer cells was not examined.

In summary, hyaline droplets were commonly observed in Kupffer cells of adult patients with AIH and AIH/PBC. However, the pathological appearance of hyaline droplets in Kupffer cells was not necessarily specific to patients with AIH or AIH/PBC. The presence of hyaline droplets in Kupffer cells was independent of the autoimmune responses and histological fibrosis or activity among patients with AIH. Thus, further studies will be essential to clarify the immunological and pathological significance of hyaline droplets in Kupffer cells of liver specimens from patients with chronic liver diseases.

Disclosure of conflict of interest

None.

Address correspondence to: Takashi Himoto, Department of Medical Technology, Kagawa Prefectural University of Health Sciences, 281-1, Hara, Mure-Cho, Takamatsu 761-0123, Kagawa, Japan. Tel: +81-87-870-1240; Fax: +81-87-870-1202; E-mail: himoto@chs.pref.kagawa.jp

References

- [1] Manns MP, Lohse AW, Vergani D. Autoimmune hepatitis-update 2015. *J Hepatol* 2015; 62: S100-S111.
- [2] Gatselis NK, Zachou K, Koukoulis GK, Dalekos GN. Autoimmune hepatitis, one disease with many faces: etiopathogenetic, clinic-laboratory and histological characteristics. *World J Gastroenterol* 2015; 21: 60-83.
- [3] Czaja AJ, Homburger HA. Autoantibodies in liver disease. *Gastroenterology* 2001; 120: 239-249.
- [4] Tacke F, Zimmermann HW. Macrophage heterogeneity in liver injury and fibrosis. *J Hepatol* 2014; 60: 1090-1096.
- [5] Itoshima T, Kiyotoshi S, Kawaguchi K, Ogawa H, Ohta W, Ito T, Hirakawa H, Shimada Y, Nagashima H. Kupffer cell hyperplasia in liver diseases. Demonstration by scanning electron microscopy of biopsy samples. *Gastroenterol Jpn* 1981; 16: 223-231.
- [6] Hadziyannis S, Feizi T, Scheuer PJ, Sherlock S. Immunoglobulin-containing cells in the liver. *Clin Exp Immunol* 1969; 5: 499-514.

Hyaline droplets in Kupffer cells

- [7] Tucker SM, Jonas MM, Perez-Atayde AR. Hyaline droplets in Kupffer cells. *Am J Surg Pathol* 2015; 39: 772-778.
- [8] Aoyama T, Paik YH, Seki E. Toll-like receptor signaling and liver fibrosis. *Gastroenterol Res Pract* 2010; 2010.
- [9] Alvarez F, Berg PA, Bianchi FB, Bianchi L, Burroughs AK, Cancado EL, Chapman RW, Cooksley WG, Czaja AJ, Desmet VJ, Donaldson PT, Eddleston AL, Fainboim L, Heathcote J, Homberg JC, Hoofnagle JH, Kakumu S, Krawitt EL, Mackay IR, MacSween RN, Maddrey WC, Manns MP, McFarlane IG, Meyer zum Büschenfelde KH, Zeniya M. International Autoimmune Hepatitis Group. Report: review of criteria for diagnosis of autoimmune hepatitis. *J Hepatol* 1999; 31: 929-938.
- [10] The Intractable Hepatobiliary Disease Study Group Supported by the Ministry of Health, Labor and Welfare of Japan. Working subgroup (English version) for clinical practice guidelines for primary biliary cirrhosis. Guidelines for the management of primary biliary cirrhosis. *Hepatol Res* 2014; 44: 71-90.
- [11] Chazouilleres O, Wendum D, Serfaty L, Montebault S, Rosmorduc O, Poupon R. Primary biliary cirrhosis-autoimmune hepatitis overlap syndrome: clinical features and response to therapy. *Hepatology* 1998; 28: 296-301.
- [12] Sandres-Saune K, Abravanel F, Nicot F, Peron JM, Alric L, Boineau J, Pasquier C, Izopet J. Detection and quantitation of HCV RNA using real-time PCR after automated sample processing. *J Med Virol* 2007; 79: 1821-1826.
- [13] Ichida F, Tsuji T, Omata M, Ichida T, Inoue K, Kamimura T, Yamada G, Hino K, Yokosuka O, Suzuki H. New Inuyama classification: new criteria for histological assessment of chronic hepatitis. *Int Hepatol Commun* 1996; 6: 112-119.
- [14] Matteoni CA, Younossi ZM, Gramlich T, Boparai N, Liu YC, McCullough AJ. Nonalcoholic fatty liver disease: a spectrum of clinical and pathological severity. *Gastroenterology* 1999; 16: 1413-1419.
- [15] Knodell RG, Ishak KG, Black WC, Chen TS, Craig R, Kaplowitz N, Kiernan TW, Wollman J. Formulation and application of a numerical scoring system for assessing histological activity in asymptomatic chronic active hepatitis. *Hepatology* 1981; 1:431-435.
- [16] Seki E, Schnabl B. Roles of innate immunity and the microbiota in liver fibrosis: crosstalk between the liver and gut. *J Physiol* 2012; 590: 447-458.
- [17] Lin R, Zhang J, Zhou L, Wang B. Altered function of monocytes/macrophages in patients with autoimmune hepatitis. *Mol Med Rep* 2016; 13: 3874-3880.
- [18] Granito A, Muratori P, Quarneri C, Pappas G, Cicola R, Muratori L. Antinuclear antibodies as ancillary markers in primary biliary cirrhosis. *Expert Rev Mol Diagn* 2012; 12: 65-74.
- [19] Himoto T, Masaki T. Extrahepatic manifestations and autoantibodies in patients with hepatitis C virus infection. *Clin Dev Immunol* 2012; 2012: 871401.
- [20] Vuppalanchi R, Chalasani N. Nonalcoholic fatty liver disease and nonalcoholic steatohepatitis: selected practical issues in their evaluation and management. *Hepatology* 2009; 49: 306-317.