

Original Article

Neurofibromin 1 expression is negatively correlated with malignancy and prognosis of epithelial ovarian cancer

Guyuan Qiao¹, Xuchun Jia², Ying Zhang³, Biliang Chen¹

Departments of ¹Obstetrics and Gynecology, ²Pathology, Xijing Hospital, Fourth Military Medical University, Xi'an, Shaanxi, China; ³Department of Obstetrics and Gynecology, 323 Hospital, People's Liberation Army, Xi'an, Shaanxi, China

Received October 21, 2017; Accepted December 19, 2017; Epub May 1, 2019; Published May 15, 2019

Abstract: Epithelial ovarian cancer ranks as the 5th most deadly female cancer. However, few effective biomarkers have been identified for clinical application. Thus, it is critical to identify differentially expressed genes in epithelial ovarian cancer patient samples. Our work has focused on a tumor suppressor gene Neurofibromin 1 and its role in epithelial ovarian cancer pathology. We examined 124 samples of benign ovarian tissues, borderline ovarian tissues, and epithelial ovarian cancer tissues for NF1 expression by immunohistochemistry and further validated our results using RT-PCR and Western blot. We next analyzed the follow-up information with pathological features using Kaplan-Meier univariate survival analysis and Cox regression multivariate analysis. First, our results show that the mRNA level and protein level of NF1 are significantly decreased in epithelial ovarian cancer patients. Second, NF1 expression is negatively associated with 5-year overall survival, lymph node metastasis, and tumor size. Furthermore, our data also suggests that NF1 expression is a protective factor for epithelial ovarian cancer prognosis. NF1 is negatively regulated in EOC patients and low expression of NF1 is associated with lymph node metastasis. More importantly, patients that have lost NF1 showed poorer prognosis and five-year overall survival.

Keywords: Epithelial ovarian cancer, neurofibromin 1, prognosis, overall survival, malignancy

Introduction

Epithelial ovarian cancer (EOC) is one of the most common cancers and is a huge threat to women. It ranks as fourth for all cancer-related deaths [8]. It has been estimated that the overall 5-year survival of EOC worldwide is only 30% [15] and this poor situation has not been improved for almost 30 years [51]. Although new generation medicines like bevacizumab and olaparib have been applied in treatments of EOC, effective therapies for EOC are still desperately in need [36]. Early diagnosis of EOC is extremely low due to the cryptic nature of EOC and the lack of effective diagnostic markers [42]. Thus, it is of great importance to identify molecular mechanisms that facilitate the prognosis. In addition, EOC is a morphologically and genetically heterogeneous cancer. Morphologically, EOC is classified as a serous cystadenocarcinoma, a mucinous cystadenocarcinoma, a endometrioid tumor, or a clear cell

carcinoma. The heterogeneity increases the difficulty in identifying molecular markers for evaluation of early diagnosis and prognosis. Therefore, identifying new and unified molecular abnormalities of EOC may provide biological markers for diagnosis and prognosis as well as medical targets for treatments.

Neurofibromin 1 (NF1) is a well characterized tumor suppressor initially described in the late 1980's [2, 10]. Mutation of the NF1 gene results in neurofibromatosis type 1, an autosomal dominant tumor predisposition syndrome [16, 17]. Neurofibromatosis type 1 is diagnosed by the presence of dark pigmented patches and inguinal freckling [6]. NF1 is expressed ubiquitously during development but is restricted in neural tissues in mature individuals [12, 13]. According to the expression pattern, NF1 plays critical roles in neural crest differentiation [5, 11, 48, 50]. In addition, NF1 is also a key player in melanocytes. Initial characterization

of NF1 function in melanocytes revealed that NF1 mutation was not responsible for melanoma tumorigenesis [19]. Recent reports showed that miR-514a was specifically expressed in melanoma which reduced expression of NF1 and in turn resulted in drug resistance [45]. Human embryonic stem cell derived melanocytes demonstrated that through ERK signaling NF1 activates MITF, the key transcription factor for melanogenesis [1]. NF1 encodes a protein of 2818 amino acids [28]. This large protein contains GTPase-activating protein domain and has GAP activities [53, 54]. Thus NF1 is able to stimulate RAS activity. With the advancement of gene sequencing, NF1 mutations have been identified in colon cancer, breast cancer, acute myeloid leukemia, lung cancer, liver cancer, urachal adenocarcinoma and gastric cancer [9, 14, 18, 21, 27, 43, 49]. A recent report showed that patients with NF1 mutation developed breast cancer but not neurofibromatosis type 1 and it has been estimated that 3% of breast cancer patients have NF1 mutations [4]. However, it is not clear whether NF1 expression is associated with the pathology or subtype of EOC.

Here, we examined the expression pattern and level of NF1 in benign ovarian tissues, borderline ovarian tissues, and epithelial ovarian cancer tissues and further analyzed the expression differences among these samples. We next analyzed the association of NF1 expression in EOC with pathologic features. By applying Kaplan-Meier univariate survival analysis and Cox regression multivariate analysis, we further examined the role of NF1 in EOC pathology. Our results reveal a protective role of NF1 against EOC pathology.

Materials and methods

Patients and samples

All the patients who were diagnosed with epithelial ovarian carcinoma, borderline ovarian tumors, or benign ovarian neoplasm, underwent surgery at the Department of Obstetrics and Gynecology, Xijing Hospital, the Fourth Military Medical University. None of the patients had any history of chemoradiation, radiation, or hormonal therapy before the surgery and the pathological diagnosis were confirmed by pathology.

Paraffin-embedded specimens of ovarian tissue from one 124 patients who were recruited

between November 2006 and March 2016 were taken and re-checked by light microscopy. All results were in accordance with the original diagnosis. The age of the 124 patients was 14~79 years, with an average age of 45 years. According to pathological examinations, these cases were divided into three groups: (1) 93 cases of epithelial ovarian carcinoma, aged 14-75 years, with an average age of 49.5 years; (2) 14 cases of borderline ovarian tumors, aged 18-79 years, with an average age of 42.4 years, including 7 cases of serous cystadenoma and 7 cases of mucinous cystadenoma; (3) 17 cases of benign ovarian tumor, aged 20-67 years, with an average age of 38.8 years, including 9 cases of serous cystadenoma and 8 cases of mucinous cystadenoma.

The fresh ovarian tissue samples were collected from 48 patients who were recruited between March 2015 and September 2016. These 48 cases including 16 cases of benign epithelial ovarian tumor, with an average age of 54.4 years (aged 50-63 years) and 32 cases of epithelial ovarian carcinoma, with an average age of 55.4 years (aged 30-73 years). All specimens were cut and stored in liquid nitrogen immediately for PCR and Western blot examination. 93 patients who were diagnosed with epithelial ovarian carcinoma with complete clinical data were recruited between November 2006 and March 2016, with an average age of 49.5 years (aged 14-75 years). Among the patients, 74 cases were serous cystadenocarcinoma, 13 cases were mucinous cystadenocarcinoma and 6 cases were clear cell carcinoma and endometrial carcinoma. They were divided into two groups according to cytological classification: 25 cases of high differentiated carcinoma and 68 cases of poorly differentiated carcinoma. According to the FIGO (the International Federation of Gynecology and Obstetrics) system, 18 cases had stage I, 16 had stage II, 46 had stage III, and 13 had stage IV. Among the 93 patients with EOC, 45 patients had lymph nodes metastasis, while 48 had no metastasis. 69 postmenopausal patients were over 50 years old and 24 postmenopausal patients were under 50 years of age. Ascites in 67 patients was greater than 100 ml, and 26 patients were less than 100 ml. The cut-off point of CA125 was 100 U/ml, 75 cases above the point while 18 cases under this point. 32 cases had a tumor diameter larger than 8 cm and 61 cases had a tumor diameter less than 8 cm. Platinum based combination chemothera-

NF1 expression in epithelial ovarian cancer

Table 1. NF1 expression in various tissues

Groups	Cases	NF1 expression			P
		0-1	2-4	5-9	
Malignant (n)	93	34	41	18	0.000
Borderline (n)	14	2	3	9	
Benign (n)	17	0	4	13	
Total	124	36	48	40	

py was performed after the operation, and the patients were followed up for more than 5 years.

Immunohistochemistry

The most representative paraffin block was selected for each lesion and immunohistochemistry was performed in all cases. Briefly, four-micrometer-thick serial paraffin sections were prepared, the sections were then deparaffinized and incubated with peroxidase solution (3% H₂O₂), followed by incubation at room temperature for 30 minutes with nonimmune animal serum. Immune-histochemical reactions using antibodies anti-NF1 (rabbit polyclonal antibody, diluted 1:500, Novus Biologicals) at 4°C overnight, followed by second antibody for 30 minutes, and washed with phosphate-buffered saline. Staining was then detected using the SP immunohistochemistry Kit (rabbit) and DAB Horseradish Peroxidase Color Development Kit.

Quantitative real-time PCR (qPCR)

Total RNA was isolated from patient samples using TRIzol Reagent (TIANGEN) according to the manufacturer's protocol. An equivalent amount of RNA was converted into complementary DNA (cDNA) with PrimeScript™ RT reagent Kit (Takara). qPCR was carried out according using SYBR Premix Ex Taq (Takara) and ABI 7500 Sequencing Detection System. Cycling condition was as follows: 40 cycles at 95°C for 5 seconds and 60°C for 34 seconds. The primer sequences are, for human NF1: forward 5'-TGGGACATTCGCCTCTAAC-3', and reverse 5'-ACACATGCAAAATGGGAACA-3'; for human GAPDH: forward 5'-AGGTCCACCACTGACAGTT-3', and reverse 5'-GCCTCAAGATCATCAGCAAT-3'. The comparative 2- $\Delta\Delta$ CT method was used to calculate the relative expression level of target gene with GAPDH as the housekeeping gene. P values < 0.05 were considered as significant and determined by student's t-tests.

Western blot

Total protein extracts were prepared with lysis buffer containing protease inhibitor. Approximately 50 µg of each protein sample was subjected to sodium dodecyl sulfate-polyacrylamide gel electrophoresis and transferred to PVDF membranes. The membranes were blocked with 5% free fat milk at room temperature for 2 h and then incubated with primary antibodies (antibody against NF1 from Novus Biologicals, 1:1,000 dilution and antibody against GAPDH from Abcam, 1:1000 dilution) overnight at 4°C, after 3 washes in TBST, the membranes were incubated with anti-rabbit or anti-mouse IgG for 1 h at room temperature. After washing, the membranes were incubated with the enhanced chemiluminescence system (ECL) detection kit (Amersham Life Science). Positive immunoreactive bands were quantified by densitometry, and normalized by GAPDH.

Statistical analysis

Statistical analysis was performed using SPSS software (standard version 22.0; SPSS). Independent sample data were analyzed with a Student's t-test and the rate comparison was analyzed with Chi-square test. The non-uniform Mann-Whitney U test was used to analyze the clinical stage (FIGO) and related clinicopathological parameters of ovarian cancer. The Kaplan-Meier method was used to analyze the relationship between the NF1 expression and patient survival. The Cox proportional hazard regression analysis was employed for multivariate survival analysis. A two-sided P-value of 0.05 was considered statistically significant.

Results

Neurofibromin 1 expression in benign ovarian tissues, borderline ovarian tissues, and epithelial ovarian cancer tissues

124 samples of benign ovarian tissues were collected. Borderline ovarian tissues and epithelial ovarian cancer tissues from patients did not receive any radiotherapy, chemotherapy, or hormone therapy before surgery. All the samples were examined and confirmed by pathologists. 93 cases were confirmed as epithelial ovarian cancer, 14 samples were confirmed as borderline ovarian tissues and 17 samples were benign ovarian tissues (Table 1). To explore the role of NF1 in EOC, we stained NF1

NF1 expression in epithelial ovarian cancer

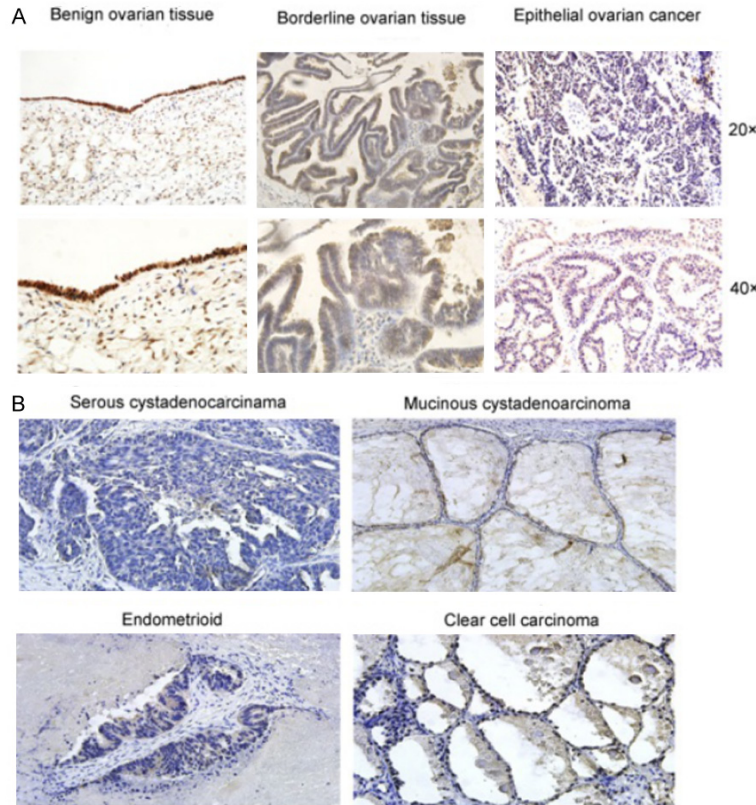


Figure 1. IHC analyses of NF1 protein expression in EOC samples. A. NF1 staining in benign ovarian tissue, borderline ovarian tissue, and epithelial ovarian cancer samples. The power of the objective lens is indicated on the right. B. NF1 staining in serous cystadenocarcinoma, mucinous cystadenocarcinoma, endometrioid tumor and clear cell carcinoma. Scale bar = 20 μ m.

with immunohistochemistry and found that NF1 predominately localized to the cytoplasm and cell membrane. We did not observe alteration of NF1 localization among benign ovarian tissues, borderline ovarian tissues, and epithelial ovarian cancer tissues (**Figure 1A**). In addition, we did not observe significant expression changes among serous cystadenocarcinoma, mucinous cystadenocarcinoma, endometrioid tumor and clear cell carcinoma suggesting that expression of NF1 was identical in different kinds of ovarian cancers (**Figure 1B**). Taken together, 88 out of 124 cases were found to be NF1 positive during immunohistochemistry staining. All 17 cases of benign ovarian tissues were NF1 positive and 85.7% (12 out of 14) cases of borderline ovarian tissue samples were NF1 positive (**Table 1**). However, only 63.4% (59 out of 93) cases of EOC were NF1 positive suggesting that NF1 was decreased in EOC tissues. We further graded expression of

NF1 in all samples and found that 40 out of 124 cases showed high levels of NF1 staining. 76.5% benign ovarian tissues and 64.3% borderline ovarian tissues showed high level NF1 staining respectively. However, only 19.3% of EOC samples showed high level NF1 staining. In fact, most NF1 positive EOC samples displayed weak staining levels (**Table 1**). Expression of NF1 in EOC tissues was significantly different from that in benign ovarian tissues or borderline ovarian tissues indicating that NF1 was statistically decreased in EOC.

We also detected mRNA expression levels of NF1 in these patients with RNA extracted from fresh tissues. Our results showed that NF1 mRNA was significantly down-regulated in EOC patients compared to the non-malignant group (**Figure 2A**). Additionally, we randomly selected 6 benign ovarian tissues and 6 EOC samples to examine NF1 protein level by Western blot. Our results showed that the protein level of NF1 was significantly decreased in EOC patients corresponding to alteration of mRNA level (**Figure 2B and 2C**).

Association of NF1 expression in EOC tissues with pathologic features

We next analyzed the pathologic features of 93 EOC patients by immunohistochemistry together with NF1 expression. This analysis revealed an association between NF1 expression and pathologic features. Our results showed that NF1 expression was negatively associated with lymph node metastasis (**Table 2**). Only 4 (9%) EOC patients with high NF1 expression developed lymph node metastasis while 25 (56%) of EOC patients with low NF1 expression developed lymph node metastasis. On the other hand, in EOC patients with no lymph node metastasis, 29% (14 out of 48) of cases showed high level NF1 expression, which was

NF1 expression in epithelial ovarian cancer

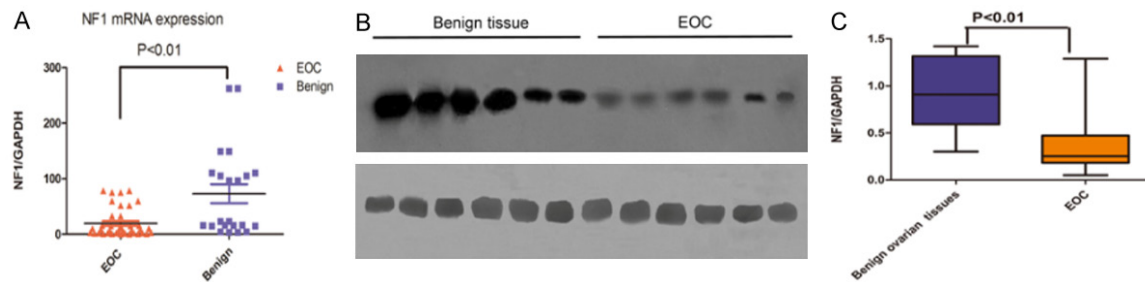


Figure 2. NF1 is down-regulated in EOC patients. A. mRNA level of NF1 in EOC tissues and benign tissues examined by qPCR. B. Protein level of NF1 in EOC tissues and benign tissues examined by Western blot. C. Quantification of Western blot results.

Table 2. Relationship between NF1 expression and clinicopathological features of EOC patients

	Case N=93	NF1 expression			<i>P</i> value	<i>P</i> value
		0-1	2-4	5-9		
Age (years)					1.047	0.592
≤ 50	49	16	24	9		
> 50	44	18	9	9		
FIGO					1.716	0.633
I	18	5	10	3		
II	16	5	6	5		
III	46	20	18	8		
IV	13	4	7	2		
Differentiation					-1.861	0.063
Well	25	7	10	8		
Moderate-poor	68	27	31	10		
Nodal status ^{**}					-2.460	0.014
Negative	48	9	25	14		
Positive	45	25	16	4		
Postmenopausal age					1.039	0.592
≥ 50	24	7	11	6		
< 50	69	27	30	12		
Ascites (≥ 100 ml)					-0.019	0.985
Yes	67	27	27	13		
No	26	7	14	5		
Serum					-1.663	0.096
Ca-125 (U/ml)						
> 100	75	27	36	12		
≤ 100	18	7	5	6		
Tumor size ^{**}					-2.118	0.034
≥ 8 cm	61	27	23	11		
< 8 cm	32	7	18	7		
Tumor type					5.303	0.071 [*]
Serous	74	28	32	14		
Mucinous	13	5	8	0		
Others	6	1	1	4		
Total	93	34	41	18		

^{*}*P* < 0.05.

significantly higher than that in EOC patients with lymph node metastasis (**Table 2**). In addition, NF1 expression was also negatively associated with tumor size. However, there was no significant correlation between NF1 expression and age (*P* value = 0.592), FIGO stages (*P* value = 0.633), tumor differentiation (*P* value = 0.063), ascites (*P* value = 0.985) and serum ca-125 (*P* value = 0.096). Meanwhile, no statistical correlation was found between NF1 expression and tumor type and postmenopausal age (**Table 2**).

Overall survival of patients with EOC

We analyzed follow-up data of 93 EOC patients and found that the average overall survival time of 93 patients was 54.92±3.06 months and the median survival time was 50±9.02 months. Importantly, our results showed that median survival time of EOC patients with high level NF1 expression was 67±14.03 months, while the median survival time of EOC patients with low level NF1 expression was 40±10.83 months. The Kaplan-Meier univariate survival analysis showed that five-year overall survival of EOC patients with a high expression level of NF1 was significantly higher than that of EOC patients with low level NF1 expression (**Figure 3A**). In addition, our data also revealed

NF1 expression in epithelial ovarian cancer

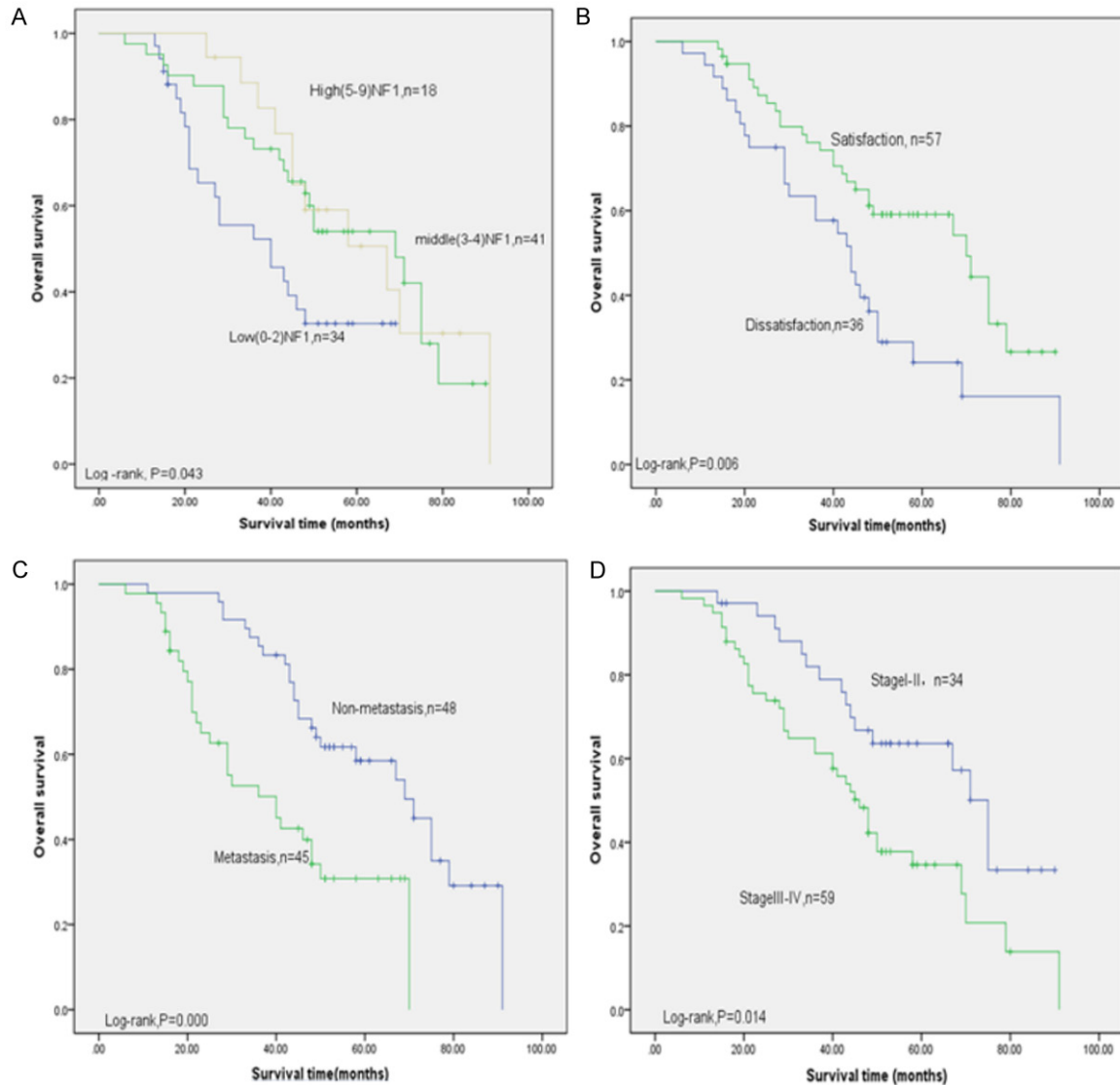


Figure 3. Kaplan-Meier survival analyses of the EOC patients. A. Kaplan-Meier survival curve of three groups of patients divided by NF1 immunostaining score. B. Kaplan-Meier survival curve of two groups of patients divided by surgery satisfaction. C. Kaplan-Meier survival curve of two groups of patients divided by lymph node metastasis. D. Kaplan-Meier survival curve of two groups of patients divided by FIGO stages.

that surgery satisfaction was not associated with prognosis (**Figure 3B**). However, lymph node metastasis and FIGO stages were associated with overall survival (**Figure 3C** and **3D**).

Furthermore, we utilized Cox regression multivariate analysis and our results revealed that four parameters are associated with overall survival. They are FIGO stage, lymph node metastasis, age, and NF1 expression (**Table 3**). Age was not an independent risk factor on prognosis of these 96 EOC patients. Our results showed that the HR (hazard ratio) of NF1 expression was 0.960 with 95% CI (confidence interval) = 0.261-0.901 and P -value = 0.723

suggesting a protective role of NF1 on EOC prognosis. FIGO stage (HR = 2.528, 95% CI = 1.211-5.276 and P -value = 0.014) and lymph node metastasis (HR = 2.926, 95% CI = 1.616-5.301 and P -value = 0.000) were significant risk factors on prognosis of EOC.

Discussion

Ovarian cancer is one of the most deadly malignant tumors. It has been estimated that 22,280 people have developed ovarian cancer and 14,240 of them died from it [4]. Ovarian cancer usually has developed into later stages when patients are diagnosed, resulting in a very low

NF1 expression in epithelial ovarian cancer

Table 3. Cox regression multivariate analysis of OS in EOC

Type	B	SE	Sig	EXP (B)	95% CI	
FIGO stage	0.927	0.375	0.014	2.528	1.211	5.276
Lym-metastasis	1.074	0.303	0.000	2.926	1.616	5.301
NF1	-0.723	0.316	0.022	0.483	0.261	0.901
Age	-0.041	0.384	0.914	0.960	0.452	2.038

rate of overall survival [23]. However, there have been little biomarkers effective for early diagnosis let alone for increasing survival rates. It has been reported that NF1 is associated with numerous types of tumors [39]. Patients bearing NF1 mutations have much higher chances to develop lung, bone, thyroid, breast, and ovarian cancer [3, 14, 25, 37]. Multiple gastrointestinal stromal tumors (MGISTs) is the most common gastrointestinal tumors with NF1 mutation and accumulating evidences suggests that MGIST coexists with other types of tumors [20, 29, 35, 55]. Meanwhile, data have illustrated that NF1 mutation occurs in a large number of lung cancer patients and about 11%-12% of primary lung adenocarcinoma patients bear the NF1 mutation [14, 37]. Since targeted therapy requires details of genetic background, discovery of NF1 mutations in various types of cancer would benefit customized therapy [3, 30, 46, 52]. Drug resistance is another obstacle in cancer treatment, where NF1 mutation is found to participate in multiple kinds of drug resistance in various type of cancers [3, 7, 33, 34, 56]. Importantly, P53 plays critical roles in the development of malignant peripheral nerve sheath tumors (MPNST) and many other NF1 related tumors [22, 24, 38, 41, 57, 58].

In this study, our immunohistochemistry results show that NF1 is highly expressed in benign ovarian tissues and is statistically reduced in EOC tissues. RT-PCR and Western blot both validated that NF1 expression in benign samples is significantly higher than that in EOC tissues which is in line with immunohistochemistry results. Our results further showed that the more malignant the cancer, the lower NF1 was expressed. Importantly, expression of NF1 in different FIGO stages was significantly different, suggesting that loss of NF1 promotes EOC. In 2013, Ross et al. analyzed 48 EOC patients and found that 14.5% of these patients bear NF1 mutation [40]. Our data show that NF1 is

severely down-regulated or even lost in EOC. Thus, NF1 plays a more complicated role in EOC pathology rather than just as a result of epigenetic or protein structure alterations. Just like in breast cancer and non-small cell lung cancer [14, 26, 32], we found that the sequence of NF1 is unaltered, but both the mRNA and the protein expression levels of

NF1 are severely impaired in EOC which directly result in abnormal cell functions. In addition, NF1 expression was associated with tumor size (P -value = 0.034) and lymph node metastasis (P -value = 0.014) further suggesting that loss of NF1 deteriorated the pathology of EOC.

To date, it is not clear how NF1 functions as a tumor suppressor in ovarian cancer. In 2008, Mavneet et al. revealed that NF1 mutations co-occur with TP53 mutations [41] in ovarian serous carcinomas suggesting a crosstalk exist between the two signaling. In ovarian serous carcinomas, 22% patients bear NF1 mutations including homozygous deletions and splicing mutations. It has been suggested that apart from genetic or acquired mutation of NF1, heterogeneous NF1 resulted from loss of allele or somatic genetic recombination. Somatic rearrangement affects wild type NF1 as well as other genes located in chromosome 17 including the P53 on 17p13.2, EGFR2 (epidermal growth factor receptor 2) on 17q21.1, topoisomerase II α on 17q21.1 and BRAC I on 17q21.2 [21, 31, 44, 47].

We followed up these EOC patients and found according to the clinical features that 5-year overall survival of patients with high NF1 expression are significantly higher than those with low NF1 expression. Meanwhile, overall survival is also associated with FIGO stages, surgery satisfaction, and lymph node metastasis. Cox regression multivariate analysis showed that risk factors of the 93 EOC patients include FIGO stage, lymph node metastasis, ages and NF1 expression. Among them, FIGO stage, lymph node metastasis, and NF1 expression are independent risk factors of prognosis. NF1 is a protective factor suggesting that higher NF1 expression expected better prognosis. Worse FIGO stage and lymph node metastasis indicated the worst prognosis. Other pathologic factors such as tumor type, ascites, and serum CA-125 were not associated with prognosis.

These results suggest that NF1 expression is closely related to prognosis of EOC. Thus, our results reveal a potential biomarker to assess malignancy of EOC and design accurate therapy based on the expression level of NF1.

Conclusion

In summary, we collected 124 ovarian tissues during surgical operations and examined expression level of NF1. We found that all 17 benign ovarian tissues exhibited high NF1 staining. Our results further show that NF1 is negatively regulated in EOC patients and low expression level of NF1 is associated with lymph node metastasis. More importantly, patients that lost NF1 expression showed poorer prognosis and five-year overall survival. In addition, we did not observe any difference between NF1 expression and localization in different types of EOCs.

Acknowledgements

We acknowledge support from Collaborative innovation projects of Shaanxi Province no: 2015XT-53.

Disclosure of conflict of interest

None.

Address correspondence to: Biliang Chen, Department of Obstetrics and Gynecology, Xijing Hospital, Fourth Military Medical University, Xi'an, Shaanxi, China. E-mail: cblxh@fmmu.edu.cn

References

- [1] Allouche J, Bellon N, Saidani M, Stanchina-Chatrousse L, Masson Y, Patwardhan A, Gilles-Marsens F, Delevoye C, Domingues S, Nissan X, Martinat C, Lemaitre G, Peschanski M and Baldeschi C. In vitro modeling of hyperpigmentation associated to neurofibromatosis type 1 using melanocytes derived from human embryonic stem cells. *Proc Natl Acad Sci U S A* 2015; 112: 9034-9039.
- [2] Barker D, Wright E, Nguyen K, Cannon L, Fain P, Goldgar D, Bishop DT, Carey J, Baty B, Kivlin J and et al. Gene for von Recklinghausen neurofibromatosis is in the pericentromeric region of chromosome 17. *Science* 1987; 236: 1100-1102.
- [3] Beauchamp EM, Woods BA, Dulak AM, Tan L, Xu C, Gray NS, Bass AJ, Wong KK, Meyerson M and Hammerman PS. Acquired resistance to dasatinib in lung cancer cell lines conferred by DDR2 gatekeeper mutation and NF1 loss. *Mol Cancer Ther* 2014; 13: 475-482.
- [4] Bowtell DD, Bohm S, Ahmed AA, Aspuria PJ, Bast RC Jr, Beral V, Berek JS, Birrer MJ, Blagden S, Bookman MA, Brenton JD, Chiappinelli KB, Martins FC, Coukos G, Drapkin R, Edmondson R, Fotopoulou C, Gabra H, Galon J, Gourley C, Heong V, Huntsman DG, Iwanicki M, Karlan BY, Kaye A, Lengyel E, Levine DA, Lu KH, McNeish IA, Menon U, Narod SA, Nelson BH, Nephew KP, Pharoah P, Powell DJ Jr, Ramos P, Romero IL, Scott CL, Sood AK, Stronach EA and Balkwill FR. Rethinking ovarian cancer II: reducing mortality from high-grade serous ovarian cancer. *Nat Rev Cancer* 2015; 15: 668-679.
- [5] Brannan CI, Perkins AS, Vogel KS, Ratner N, Nordlund ML, Reid SW, Buchberg AM, Jenkins NA, Parada LF and Copeland NG. Targeted disruption of the neurofibromatosis type-1 gene leads to developmental abnormalities in heart and various neural crest-derived tissues. *Genes Dev* 1994; 8: 1019-1029.
- [6] Brosius S. A history of von Recklinghausen's NF1. *J Hist Neurosci* 2010; 19: 333-348.
- [7] Brundage ME, Tandon P, Eaves DW, Williams JP, Miller SJ, Hennigan RH, Jegga A, Cripe TP and Ratner N. MAF mediates crosstalk between Ras-MAPK and mTOR signaling in NF1. *Oncogene* 2014; 33: 5626-5636.
- [8] Burger RA, Brady MF, Bookman MA, Fleming GF, Monk BJ, Huang H, Mannel RS, Homesley HD, Fowler J, Greer BE, Boente M, Birrer MJ, Liang SX; Gynecologic Oncology Group. Incorporation of bevacizumab in the primary treatment of ovarian cancer. *N Engl J Med* 2011; 365: 2473-2483.
- [9] Cacev T, Radosevic S, Spaventi R, Pavelic K and Kapitanovic S. NF1 gene loss of heterozygosity and expression analysis in sporadic colon cancer. *Gut* 2005; 54: 1129-1135.
- [10] Cawthon RM, Weiss R, Xu GF, Viskochil D, Culver M, Stevens J, Robertson M, Dunn D, Gesteland R, O'Connell P, et al. A major segment of the neurofibromatosis type 1 gene: cDNA sequence, genomic structure, and point mutations. *Cell* 1990; 62: 193-201.
- [11] Chen YH, Gianino SM and Gutmann DH. Neurofibromatosis-1 regulation of neural stem cell proliferation and multilineage differentiation operates through distinct RAS effector pathways. *Genes Dev* 2015; 29: 1677-1682.
- [12] Daston MM and Ratner N. Neurofibromin, a predominantly neuronal GTPase activating protein in the adult, is ubiquitously expressed during development. *Dev Dyn* 1992; 195: 216-226.
- [13] Daston MM, Scrabble H, Nordlund M, Sturbaum AK, Nissen LM and Ratner N. The protein product of the neurofibromatosis type 1 gene is ex-

NF1 expression in epithelial ovarian cancer

- pressed at highest abundance in neurons, Schwann cells, and oligodendrocytes. *Neuron* 1992; 8: 415-428.
- [14] de Bruin EC, Cowell C, Warne PH, Jiang M, Saunders RE, Melnick MA, Gettinger S, Walther Z, Wurtz A, Heynen GJ, Heideman DA, Gomez-Roman J, Garcia-Castano A, Gong Y, Ladanyi M, Varmus H, Bernards R, Smit EF, Politi K and Downward J. Reduced NF1 expression confers resistance to EGFR inhibition in lung cancer. *Cancer Discov* 2014; 4: 606-619.
- [15] du Bois A, Kristensen G, Ray-Coquard I, Reuss A, Pignata S, Colombo N, Denison U, Vergote I, Del Campo JM, Ottevanger P, Heubner M, Minarik T, Sevin E, de Gregorio N, Bidzinski M, Pfisterer J, Malander S, Hilpert F, Mirza MR, Scambia G, Meier W, Nicoletto MO, Bjorge L, Lortholary A, Sailer MO, Merger M, Harter P; AGO Study Group led Gynecologic Cancer Intergroup/European Network of Gynaecologic Oncology Trials Groups Intergroup Consortium. Standard first-line chemotherapy with or without nintedanib for advanced ovarian cancer (AGO-OVAR 12): a randomised, double-blind, placebo-controlled phase 3 trial. *Lancet Oncol* 2016; 17: 78-89.
- [16] Ferner RE. Neurofibromatosis 1. *Eur J Hum Genet* 2007; 15: 131-138.
- [17] Ferner RE. Neurofibromatosis 1 and neurofibromatosis 2: a twenty first century perspective. *Lancet Neurol* 2007; 6: 340-351.
- [18] Garcia-Orti L, Cristobal I, Cirauqui C, Guruceaga E, Marcotegui N, Calasanz MJ, Castello-Cros R and Otero MD. Integration of SNP and mRNA arrays with microRNA profiling reveals that MiR-370 is upregulated and targets NF1 in acute myeloid leukemia. *PLoS One* 2012; 7: e47717.
- [19] Gomez L, Rubio MP, Martin MT, Vazquez JJ, Idoate M, Pastorfide G, Pestana A, Seizinger BR, Barnhill RL and Castresana JS. Chromosome 17 allelic loss and NF1-GRD mutations do not play a significant role as molecular mechanisms leading to melanoma tumorigenesis. *J Invest Dermatol* 1996; 106: 432-436.
- [20] Gorgel A, Cetinkaya DD, Salgur F, Demirpence M, Yilmaz H, Karaman EH, Tutuncuoglu P, Oruk G, Bahceci M, Sari AA, Altinboga AA and Paker I. Coexistence of gastrointestinal stromal tumors (GISTs) and pheochromocytoma in three cases of neurofibromatosis type 1 (NF1) with a review of the literature. *Intern Med* 2014; 53: 1783-1789.
- [21] Guran S and Safali M. A case of neurofibromatosis and breast cancer: loss of heterozygosity of NF1 in breast cancer. *Cancer Genet Cytogenet* 2005; 156: 86-88.
- [22] Hirbe AC, Dahiya S, Friedmann-Morvinski D, Verma IM, Clapp DW and Gutmann DH. Spatially- and temporally-controlled postnatal p53 knockdown cooperates with embryonic Schwann cell precursor Nf1 gene loss to promote malignant peripheral nerve sheath tumor formation. *Oncotarget* 2016; 7: 7403-7414.
- [23] Karam A, Ledermann JA, Kim JW, Sehoul J, Lu K, Gourley C, Katsumata N, Burger RA, Nam BH, Bacon M, Ng C, Pfisterer J, Bekkers RL, Casado Herraez A, Redondo A, Fujiwara H, Gleeson N, Rosengarten O, Scambia G, Zhu J, Okamoto A, Stuart G, Ochiai K; participants of the 5th Ovarian Cancer Consensus Conference. Fifth Ovarian Cancer Consensus Conference of the Gynecologic Cancer InterGroup: first-line interventions. *Ann Oncol* 2017; 28: 711-717.
- [24] Ki DH, He S, Rodig S and Look AT. Overexpression of PDGFRA cooperates with loss of NF1 and p53 to accelerate the molecular pathogenesis of malignant peripheral nerve sheath tumors. *Oncogene* 2017; 36: 1058-1068.
- [25] Latteyer S, Tiedje V, Konig K, Ting S, Heukamp LC, Meder L, Schmid KW, Fuhrer D and Moeller LC. Targeted next-generation sequencing for TP53, RAS, BRAF, ALK and NF1 mutations in anaplastic thyroid cancer. *Endocrine* 2016; 54: 733-741.
- [26] Lee J, Wang J, Torbenson M, Lu Y, Liu QZ and Li S. Loss of SDHB and NF1 genes in a malignant phyllodes tumor of the breast as detected by oligo-array comparative genomic hybridization. *Cancer Genet Cytogenet* 2010; 196: 179-183.
- [27] Li C, Wu X, Zhang W, Li J, Liu H, Hao M, Wang J, Zhang H, Yang G, Hao M, Sheng S, Sun Y, Long J, Hu X, Zhang H, Hu C, Li L and Zheng J. AEG-1 promotes metastasis through downstream AKR1C2 and NF1 in liver cancer. *Oncol Res* 2014; 22: 203-211.
- [28] Luo G, Kim J and Song K. The C-terminal domains of human neurofibromin and its budding yeast homologs Ira1 and Ira2 regulate the metaphase to anaphase transition. *Cell Cycle* 2014; 13: 2780-2789.
- [29] Maertens O, Prenen H, Debiec-Rychter M, Wozniak A, Sciort R, Pauwels P, De Wever I, Vermeesch JR, de Raedt T, De Paepe A, Speleman F, van Oosterom A, Messiaen L and Legius E. Molecular pathogenesis of multiple gastrointestinal stromal tumors in NF1 patients. *Hum Mol Genet* 2006; 15: 1015-1023.
- [30] Malone CF, Fromm JA, Maertens O, DeRaedt T, Ingraham R and Cichowski K. Defining key signaling nodes and therapeutic biomarkers in NF1-mutant cancers. *Cancer Discov* 2014; 4: 1062-1073.
- [31] Mantripragada KK, Diaz de Stahl T, Patridge C, Menzel U, Andersson R, Chuzhanova N, Kluwe L, Guha A, Mautner V, Dumanski JP and Upadhyaya M. Genome-wide high-resolution analysis of DNA copy number alterations in NF1-as-

NF1 expression in epithelial ovarian cancer

- sociated malignant peripheral nerve sheath tumors using 32K BAC array. *Genes Chromosomes Cancer* 2009; 48: 897-907.
- [32] Ogata H, Sato H, Takatsuka J and De Luca LM. Human breast cancer MDA-MB-231 cells fail to express the neurofibromin protein, lack its type I mRNA isoform and show accumulation of P-MAPK and activated Ras. *Cancer Lett* 2001; 172: 159-164.
- [33] Park HJ, Lee SJ, Sohn YB, Jin HS, Han JH, Kim YB, Yim H and Jeong SY. NF1 deficiency causes Bcl-xL upregulation in Schwann cells derived from neurofibromatosis type 1-associated malignant peripheral nerve sheath tumors. *Int J Oncol* 2013; 42: 657-666.
- [34] Peltonen S, Kallionpaa RA and Peltonen J. Neurofibromatosis type 1 (NF1) gene: beyond cafe au lait spots and dermal neurofibromas. *Exp Dermatol* 2017; 26: 645-648.
- [35] Ponti G, Martorana D, Pellacani G, Ruini C, Loschi P, Baccarani A, De Santis G, Pollio A, Neri TM, Mandel VD, Maiorana A, Maccio L, Maccaferri M and Tomasi A. NF1 truncating mutations associated to aggressive clinical phenotype with elephantiasis neuromatosa and solid malignancies. *Anticancer Res* 2014; 34: 3021-3030.
- [36] Ray-Coquard I and Lorusso D. Immunotherapy and Epithelial Ovarian Cancer: a double-edged sword? *Ann Oncol* 2017; 28: 909-910.
- [37] Redig AJ, Capelletti M, Dahlberg SE, Sholl LM, Mach S, Fontes C, Shi Y, Chalasani P and Janne PA. Clinical and molecular characteristics of NF1-Mutant lung cancer. *Clin Cancer Res* 2016; 22: 3148-3156.
- [38] Reilly KM, Tuskan RG, Christy E, Loisel DA, Ledger J, Bronson RT, Smith CD, Tsang S, Munroe DJ and Jacks T. Susceptibility to astrocytoma in mice mutant for Nf1 and Trp53 is linked to chromosome 11 and subject to epigenetic effects. *Proc Natl Acad Sci U S A* 2004; 101: 13008-13013.
- [39] Rosenbaum T and Wimmer K. Neurofibromatosis type 1 (NF1) and associated tumors. *Klin Padiatr* 2014; 226: 309-315.
- [40] Ross JS, Ali SM, Wang K, Palmer G, Yelensky R, Lipson D, Miller VA, Zajchowski D, Shawver LK and Stephens PJ. Comprehensive genomic profiling of epithelial ovarian cancer by next generation sequencing-based diagnostic assay reveals new routes to targeted therapies. *Gynecol Oncol* 2013; 130: 554-559.
- [41] Sangha N, Wu R, Kuick R, Powers S, Mu D, Fiannder D, Yuen K, Katabuchi H, Tashiro H, Fearon ER and Cho KR. Neurofibromin 1 (NF1) defects are common in human ovarian serous carcinomas and co-occur with TP53 mutations. *Neoplasia* 2008; 10: 1362-1372, following 1372.
- [42] Siegel R, Naishadham D and Jemal A. Cancer statistics for Hispanics/Latinos, 2012. *CA Cancer J Clin* 2012; 62: 283-298.
- [43] Singh H, Liu Y, Xiao X, Lin L, Kim J, Van Hummelen P, Wu CL, Bass AJ and Saylor PJ. Whole exome sequencing of urachal adenocarcinoma reveals recurrent NF1 mutations. *Oncotarget* 2016; 7: 29211-29215.
- [44] Stansfield BK, Bessler WK, Mali R, Mund JA, Downing BD, Kapur R and Ingram DA Jr. Ras-Mek-Erk signaling regulates Nf1 heterozygous neointima formation. *Am J Pathol* 2014; 184: 79-85.
- [45] Stark MS, Bonazzi VF, Boyle GM, Palmer JM, Symmons J, Lanagan CM, Schmidt CW, Herington AC, Ballotti R, Pollock PM and Hayward NK. miR-514a regulates the tumour suppressor NF1 and modulates BRAFi sensitivity in melanoma. *Oncotarget* 2015; 6: 17753-17763.
- [46] Suh JH, Johnson A, Albacker L, Wang K, Chmielecki J, Frampton G, Gay L, Elvin JA, Vergilio JA, Ali S, Miller VA, Stephens PJ and Ross JS. Comprehensive genomic profiling facilitates implementation of the national comprehensive cancer network guidelines for lung cancer biomarker testing and identifies patients who may benefit from enrollment in mechanism-driven clinical trials. *Oncologist* 2016; 21: 684-691.
- [47] Upadhyaya M, Spurlock G, Majounie E, Griffiths S, Forrester N, Baser M, Huson SM, Gareth Evans D and Ferner R. The heterogeneous nature of germline mutations in NF1 patients with malignant peripheral nerve sheath tumours (MPNSTs). *Hum Mutat* 2006; 27: 716.
- [48] Vogel KS, Brannan CI, Jenkins NA, Copeland NG and Parada LF. Loss of neurofibromin results in neurotrophin-independent survival of embryonic sensory and sympathetic neurons. *Cell* 1995; 82: 733-742.
- [49] Wang S, Ma G, Zhu H, Lv C, Chu H, Tong N, Wu D, Qiang F, Gong W, Zhao Q, Tao G, Zhou J, Zhang Z and Wang M. miR-107 regulates tumor progression by targeting NF1 in gastric cancer. *Sci Rep* 2016; 6: 36531.
- [50] Williams JP, Wu J, Johansson G, Rizvi TA, Miller SC, Geiger H, Malik P, Li W, Mukoyama YS, Cancelas JA and Ratner N. Nf1 mutation expands an EGFR-dependent peripheral nerve progenitor that confers neurofibroma tumorigenic potential. *Cell Stem Cell* 2008; 3: 658-669.
- [51] Wilson MK, Pujade-Lauraine E, Aoki D, Mirza MR, Lorusso D, Oza AM, du Bois A, Vergote I, Reuss A, Bacon M, Friedlander M, Gallardo-Rincon D, Joly F, Chang SJ, Ferrero AM, Edmondson RJ, Wimberger P, Maenpaa J, Gaffney D, Zang R, Okamoto A, Stuart G, Ochiai K; participants of the Fifth Ovarian Cancer Consensus C. Fifth Ovarian Cancer Consensus

NF1 expression in epithelial ovarian cancer

- Conference of the Gynecologic Cancer Inter-Group: recurrent disease. *Ann Oncol* 2017; 28: 727-732.
- [52] Woodfield SE, Zhang L, Scorsone KA, Liu Y and Zage PE. Binimetinib inhibits MEK and is effective against neuroblastoma tumor cells with low NF1 expression. *BMC Cancer* 2016; 16: 172.
- [53] Xu GF, Lin B, Tanaka K, Dunn D, Wood D, Gesteland R, White R, Weiss R and Tamanoi F. The catalytic domain of the neurofibromatosis type 1 gene product stimulates ras GTPase and complements ira mutants of *S. cerevisiae*. *Cell* 1990; 63: 835-841.
- [54] Xu GF, O'Connell P, Viskochil D, Cawthon R, Robertson M, Culver M, Dunn D, Stevens J, Gesteland R, White R, et al. The neurofibromatosis type 1 gene encodes a protein related to GAP. *Cell* 1990; 62: 599-608.
- [55] Yamamoto Y, Kodama K, Yokoyama S, Takeda M and Michishita S. A pleural solitary fibrous tumor, multiple gastrointestinal stromal tumors, moyamoya disease, and hyperparathyroidism in a patient associated with NF1. *Case Rep Surg* 2015; 2015: 375416.
- [56] Yap YS, McPherson JR, Ong CK, Rozen SG, Teh BT, Lee AS and Callen DF. The NF1 gene revisited - from bench to bedside. *Oncotarget* 2014; 5: 5873-5892.
- [57] Zemp FJ, McKenzie BA, Lun X, Maxwell L, Reilly KM, McFadden G, Yong VW and Forsyth PA. Resistance to oncolytic myxoma virus therapy in *nf1(-)/trp53(-)* syngeneic mouse glioma models is independent of anti-viral type-I interferon. *PLoS One* 2013; 8: e65801.
- [58] Zhu Y, Guignard F, Zhao D, Liu L, Burns DK, Mason RP, Messing A and Parada LF. Early inactivation of p53 tumor suppressor gene cooperating with NF1 loss induces malignant astrocytoma. *Cancer Cell* 2005; 8: 119-130.