

Case Report

Mesenteric Castleman's disease: report of a case and literature review

Pao-Shu Wu^{1,2}

¹Department of Pathology, MacKay Memorial Hospital, ²Mackay Junior College of Medicine, Nursing, and Management, Taipei, Taiwan

Received June 4, 2020; Accepted July 20, 2020; Epub September 1, 2020; Published September 15, 2020

Abstract: Castleman's disease is a rare benign lymphoproliferative disorder which most occurred in mediastinum. There are three subtypes of Castleman's disease. The hyaline-vascular variant is often localized, asymptomatic, and with benign outcome. Whereas the plasma cell and multicentric variants are systemic diseases frequently associated with HIV infection or other hematopoietic malignancies. Mesenteric Castleman's disease is extremely rare. Less than 30 cases have been reported. Here, we report a case of mesenteric Castleman's disease with initial gastrointestinal symptoms.

Keywords: Castleman's disease, mesentery, lymphoproliferative disorder

Introduction

Castleman's disease, also known as angiomatous lymphoid hyperplasia or giant lymph node hyperplasia, is a rare benign lymphoproliferative disorder first described by Benjamin Castleman in 1954 [1]. The most common place of occurrence is the anterior mediastinum, but virtually all body places have been reported. Castleman's disease in mesentery is extremely rare. Less than 30 cases were reported up to date [2]. Herein we report a case of mesenteric Castleman's disease initially presented as gastrointestinal symptoms.

Case report

A 61-year-old man presented to our hospital's gastrointestinal (GI) unit with intermittent tarry stool for one year. His body weight lost 8 kilograms in one year. The upper GI pan-endoscopic examination revealed no significant findings. The colonoscopic examination identified two tubular adenomas with low grade dysplasia. The red blood cell scan did not uncover an active bleeding site. An upper GI and small bowel series study revealed no filling defect or obstructive lesion in the intestine, but the jejunum showed segmental mucosal thickening

with fixed position in the left upper abdomen (**Figure 1A**). Therefore, an abdominal computed tomography (CT) scan was performed, and it showed distended jejunum loops with thickened mucosa. In addition, multiple enlarged lymph nodes in the mesentery were noted (**Figure 1B**, arrows). The patient was referred to the general surgery unit and underwent exploratory laparotomy. A segment of jejunum was resected. The surrounding enlarged mesenteric lymph nodes were also sampled.

Upon histopathological examination, the jejunum showed mild mucosa ischemic change with edematous submucosa and focal fibrosis. However, sections of the mesenteric lymph nodes prominent follicular hyperplasia (**Figure 2A**) and each follicle was surrounded by a broad mantle zone composed of concentric rings of small lymphocytes resulting in an "onion skin" appearance (**Figure 2B**). In addition, hyaline deposits were present within the germinal center in which the follicle was radially penetrated by a sclerotic blood vessel resembling a "lollipop" (**Figure 2C**, arrow). The lymphoid cells showed a mixed population of interfollicular CD3(+) T cells and follicular CD20(+) B cells (**Figure 3A**). CD138(+) Plasma cells were seen mainly in the interfollicular area (**Figure 3B**).

A rare case of mesenteric Castleman's disease

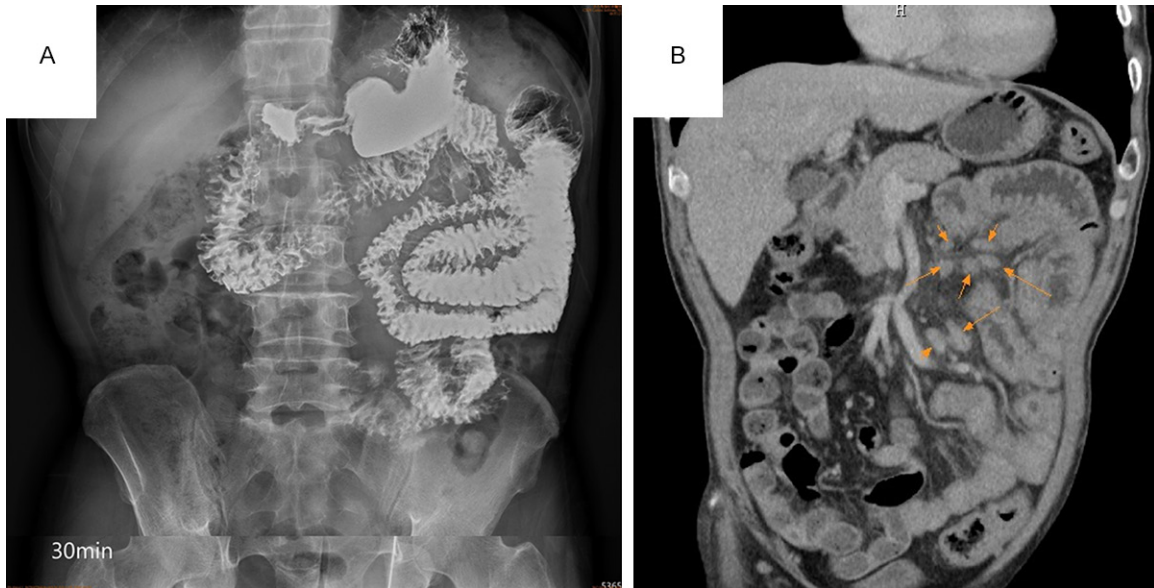


Figure 1. A. The small bowel barium series X-ray image showed segmental mucosal thickening of jejunum with a fixed position over the left upper abdomen. No obstructive or filling defect is seen. B. Abdominal CT image revealed multiple enlarged mesenteric lymph nodes (orange arrows).

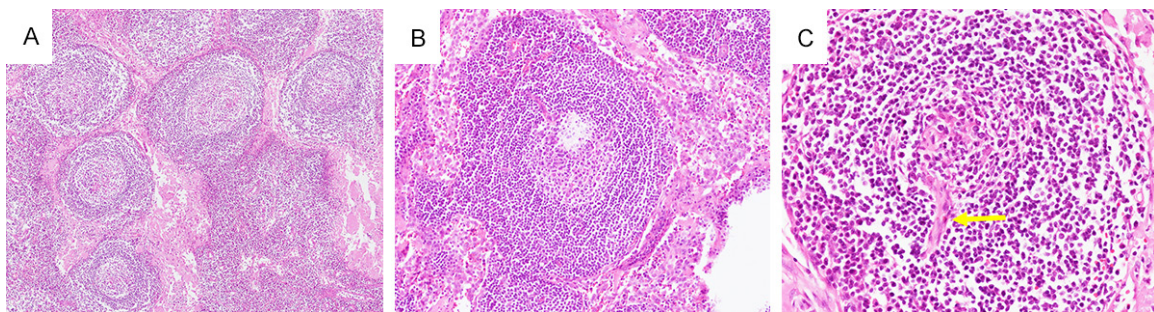


Figure 2. A. Low magnification of the mesenteric lymph node showed hyperplastic follicles with broad, prominent mantle zones (hematoxylin and eosin (H&E) stain, 40 \times). B. H&E stain of a follicle showed lamination of the mantle cell layers forming the characteristic “onion skin” appearance (100 \times). C. H&E stain of a follicle with a prominent, hyalinized penetrating blood vessel gives the appearance of a lollipop (yellow arrow) (200 \times).

Immunostains for human herpes virus 8 (HHV8) and Cyclin D1 were negative (not shown). The final pathological diagnosis was mesenteric Castleman's disease, hyaline-vascular type. Further pertinent survey did not reveal other foci of lymphoproliferative disorder or neoplasm and there was no recurrence after 4 years of follow-up surveillance.

Discussion

Castleman's disease (CD) is a benign lymphoproliferative disorder which can be subdivided into hyaline-vascular (or angiofollicular) type, plasma cell type, and multicentric type. The common sites of involvement are mediastinal,

cervical, axillary, and pulmonary lymphoid tissue. The hyaline-vascular type, accounting for 90% of CD, is mostly localized lesion with asymptomatic and benign outcome [3]. It is characterized with follicular hyperplasia, regressively transformed germinal centers, vascular proliferation, and have radially penetrating hyalinized capillaries resulting in “lollipop” follicles (**Figure 2C**). The lymphocytes in the surrounding mantle zones are expanded and arranged in multiple concentric layers imparting an “onion skin” appearance (**Figure 2B**). The plasma cell type CD is characteristic of interfollicular expansion of plasma cells with a mixture of mature kappa- and lambda-light chain expressing plasma cells whereas the vas-

A rare case of mesenteric Castleman's disease

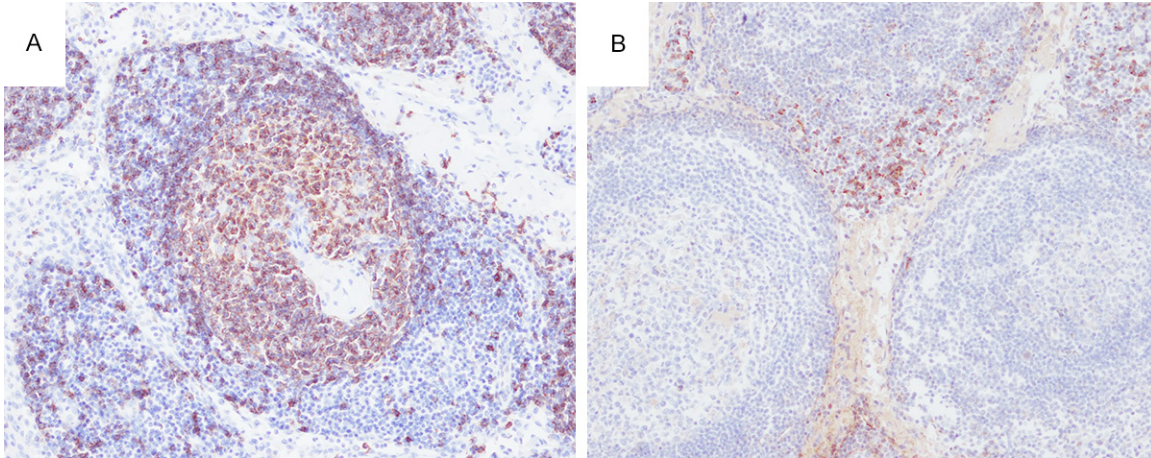


Figure 3. (A) The follicle is composed of mature CD20(+) B-cells with scattered CD138(+) plasma cells in the interfollicular area (B) (100×).

ular proliferation is not seen. The histologic features of multicentric CD are like those seen in the plasma cell type CD, including prominent interfollicular plasmacytosis and many abnormal hyperplastic or atrophic germinal centers with open and dilated sinuses. In contrast to hyaline-vascular CD, both plasma cell and multicentric CD are often associated with clinical symptoms and signs such as fever, anemia, and hypergammaglobulinemia and often disseminated.

The exact pathogenesis of CD is still unknown. Evidences have shown that unregulated B-cell proliferation and excess interleukin-6 secretion may be associated with CD [4]. Recent studies on clonal cytogenetic abnormalities support that the hyaline-vascular CD may be a dendritic cell neoplasm [5, 6]. Notably, plasma cell CD is often associated with human immunodeficiency (HIV) infection or HHV8 infection and other malignancies such as several malignancies Kaposi's sarcoma, Hodgkin and non-Hodgkin lymphomas, several autoimmune diseases, and POEMS syndrome (polyneuropathy, organomegaly, endocrinopathy, M-protein, and skin changes) [7-9]. The causative relationship between CD and these diseases remain elusive.

Although the histopathological features of hyaline-vascular CD are distinctive, these morphological changes of lymph nodes are not pathognomonic. Similar histological changes are seen in lymph nodes adjacent to either hematopoietic or non-hematopoietic malignancies. Other

conditions such as syphilis lymphadenitis, lymphoplasmacytic lymphoma, and marginal zone lymphoma, should also be distinguished from plasma cell CD. The confirmation of CD requires careful histopathological examination and exclusion of other malignancies or non-malignant conditions through thorough systemic survey and clinical history review. For hyaline-vascular CD, which is usually a benign and self-limited disease, complete surgical resection is the primary choice of treatment, whereas the therapeutic approaches for systemic CD (multicentric and plasma cell type) remain controversial including surgery, chemotherapy, and steroid therapy [10]. Albeit rare, CD in mesentery requires the awareness of pathologists and clinicians to avoid misdiagnosis.

Disclosure of conflict of interest

None.

Address correspondence to: Dr. Pao-Shu Wu, Department of Pathology, MacKay Memorial Hospital, No. 45, Minsheng Road, Tamsui District, New Taipei City 251, Taiwan. Tel: +886-2-28094661; Fax: +886-2-28093385; E-mail: pw2136@gmail.com

References

- [1] Castleman B and Towne VW. Case records of the Massachusetts general hospital. Case 40011. *N Engl J Med* 1954; 250: 26-30.
- [2] Kimura T, Inoue T, Katayama K, Hirose K, Imamura Y and Yamaguchi A. Mesenteric castleman's disease: report of a case. *Surg Today* 2002; 32: 651-654.

A rare case of mesenteric Castleman's disease

- [3] Al-Natour A, Sawalhi S, Al-Muhtady D and Hijazi E. Mesenteric castleman's disease: case report and literature review. *Asia J Surg* 2010; 33: 150-153.
- [4] Yabuhara A, Yanagisawa M, Murata T, Kawai H, Komiyama A, Akabane T, Itoh M, Ishii E, Fujimoto J and Hata J. Giant lymph node hyperplasia (Castleman's disease) with spontaneous production of high levels of B-cell differentiation factor activity. *Cancer* 1989; 63: 260-265.
- [5] Cokelaere K, Debiec-Rychter M, De Wolf-Peeters C, Hagemeyer A and Sciot R. Hyaline vascular Castleman's disease with HMGIC rearrangement in follicular dendritic cells: molecular evidence of mesenchymal tumorigenesis. *Am J Surg Pathol* 2002; 26: 662-669.
- [6] Chan JK, Tsang WY and Ng CS. Follicular dendritic cell tumor and vascular neoplasm complicating hyaline-vascular Castleman's disease. *Am J Surg Pathol* 1994; 18: 517-525.
- [7] Aboulafia DM, Picozzi VJ and Patterson S. Castleman's disease, Kaposi's sarcoma, and immunoblastic lymphoma in a patient with AIDS. *AIDS Reader* 1998; 8: 107-113.
- [8] Harris NL. Hypervascular follicular hyperplasia and Kaposi's sarcoma in patients at risk of AIDS. *N Engl J Med* 1984; 310: 462-462.
- [9] Lachant NA, Sun NC, Leong LA, Oseas RS and Prince HE. Multicentric angiofollicular lymph node hyperplasia (Castleman's disease) followed by Kaposi's sarcoma in two homosexual males with AIDS. *Am J Clin Pathol* 1985; 83: 27-33.
- [10] Keller AR, Hochholzer L and Castleman B. Hyaline-vascular and plasma-cell types of giant lymph node hyperplasia of the mediastinum and other locations. *Cancer* 1972; 29: 670-683.