

## Original Article

# Expression of dishevelled gene in Hirschsprung's disease

Dong Chen<sup>1</sup>, Jie Mi<sup>1</sup>, Mei Wu<sup>1</sup>, Weilin Wang<sup>1</sup>, Hong Gao<sup>2</sup>

<sup>1</sup>Department of Pediatric Surgery, Shengjing Hospital of China Medical University, Liaoning, China; <sup>2</sup>Key Laboratory of Pediatric Congenital Malformations, Ministry of Public Health, Shengjing Hospital of China Medical University, Shenyang, Liaoning, China

Received July 15, 2013; Accepted July 25, 2013; Epub August 15, 2013; Published September 1, 2013

**Abstract:** Hirschsprung's disease (HSCR) is a congenital disorder of the enteric nervous system and is characterized by an absence of enteric ganglion cells in terminal regions of the gut during development. Dishevelled (DVL) protein is a cytoplasmic protein which plays pivotal roles in the embryonic development. In this study, we explore the cause of HSCR by studying the expression of DVL-1 and DVL-3 genes and their proteins in the aganglionic segment and the ganglionic segment of colon in HSCR patients. Materials and Methods: Specimen of aganglionic segment and ganglionic segment of colon in 50 cases of HSCR patients. Expression levels of mRNA and proteins of DVL-1 and DVL-3 were confirmed by quantitative real-time PCR (qRT-PCR), western blot and immunohistochemistry staining between the aganglionic segment and the ganglionic segment of colon in HSCR patients. Results: The mRNA expression of DVL-1 and DVL-3 were 2.06 fold and 3.12 fold in the aganglionic segment colon tissues compared to the ganglionic segment, respectively. Similarly, the proteins expression of DVL-1 and DVL-3 were higher ( $39.71 \pm 4.53$  vs and  $53.90 \pm 6.79$  vs) in the aganglionic segment colon tissues than in the ganglionic segment ( $15.01 \pm 2.66$  and  $20.13 \pm 3.63$ ) by western blot. Besides, immunohistochemical staining showed that DVL-1 and DVL-3 have a significant increase in mucous and submucous layers from aganglionic colon segments compared with ganglionic segments. Conclusion: The study showed an association of DVL-1 and DVL-3 with HSCR, it may play an important role in the pathogenesis of HSCR.

**Keywords:** Hirschsprung's disease, dishevelled-1 and dishevelled-3, gene and protein, expression

## Introduction

Hirschsprung's disease (HSCR), which is also called aganglionosis, is a congenital disorder of the enteric nervous system (ENS) and is characterized by the absence of intestinal ganglion cells in myenteric and submucosal plexuses [1]. Its incidence is approximately 1/5,000 human live births, and has a male preponderance of 4:1 [2]. Aganglionosis is owing to the disorder of the ENS in which ganglion cells fail to innervate the lower gastrointestinal tract during embryonic development. At present, the cause of HSCR still remains unclear, but there is a common understanding that HSCR is a complex disease influenced by multiple genetic and environmental factors. Up to now, mutations in ret proto-oncogene (RET) [3, 4], endothelin receptor B (EDNRB) [5], endothelin 3 (EDN3) [5], glial

derived neurotrophic factor (GDNF) [4], and sex determining region Y-box 10 (SOX10) [6], which play important roles in the formation of ENS, have been identified in HSCR patients.

Wnt signaling pathway plays a critical role in a vast array of biological process, including cell proliferation, tumorigenesis and embryonic development [7, 8]. The present study suggests that HSCR disease is closely related with Wnt signaling pathway. It has been demonstrated that the mutation or abnormal expression of the WNT8b may result in the occurrence of HSCR [9]. The dishevelled (DVL) protein is a cytoplasmic protein which plays pivotal roles in the embryonic development, cell differentiation and tumor formation [10-12]. And it is a critical mediating site in the Wnt signaling pathway [13]. However, whether DVL protein has rela-

relationship with HSCR disease has not been identified. At present, three homologous DVL genes have been identified in human beings, respectively DVL-1, DVL-2 and DVL-3. DVL-2 is mainly related to cell proliferation and tumorigenesis [10], while DVL-1 and DVL-3 are more tend to neural formation and embryonic development [14, 15]. So in this study, we aim to explore the cause of HSCR by studying the expression of DVL-1 and DVL-3 in the colon segment tissues of HSCR patients through qRT-PCR, western blot and immunohistochemical staining.

### Materials and methods

#### *Patients and specimens*

This study was approved by Ethics Committee of China Medical University (Ethical Number: 2013 PS07K). Colon tissues were obtained from 50 pairs patients (41 males and 9 females) with pathologically confirmed HSCR pre- or post-operatively at Shengjing Hospital of China Medical University. Age ranged from 0.5 to 4.5 years old with an average of 1.5-years. Aganglionic colon segment tissues and ganglionic colon segment tissues were collected respectively and identified by pathological H&E staining. Each tissue specimen was divided into two pieces, one piece was frozen at  $-80^{\circ}\text{C}$  for molecular analysis, the other piece was fixed in 10% neutral-formalin and embedded with paraffin.

#### *Reagents and instruments*

Polyclonal anti-DVL-1 (Sigma-Aldrich® Co.) and anti-DVL-3 (BioVision Incorporated). Biotin streptavidin detection system for immunohistochemical staining, and DAB-0031/1031 kit were purchased from Fuzhou Maixin Biotechnology Development Co. The PrimeScript RT reagent kit was purchased from Takara Biotechnology (Dalian) Co. And the electrophoresis apparatus was Bio-Rad. The mixed SYBR green kit of Takara Biotechnology was made for qRT-PCR with a Light Cycle480 (Roche, Basel, Switzerland) instrument.

#### *Design and synthesis of primers*

Human  $\beta$ -actin was taken as an internal control with the production of 317 base pair (bp). There were three side chains. A pair of primers was constructed by the cDNA Chi sequence of DVL-1. Its production was 108 bp. Another pair of

primers was constructed by the cDNA Chi sequence of DVL-3, Whose production was 102 bp. These three pairs of primers were synthesized and purified by Shanghai Biological Engineering Company. The three pairs of primers were as following: Human  $\beta$ -actin, sense: 5' AGA GCT ACG AGC TGC CTG AC 3', antisense: 5' AGC ACT GTG TTG GCG TAC AG 3'; Human DVL-1, sense: 5' GCT GAC GGT GAA GAG TGA C 3', antisense: 5' GCA TTG GCG ATG GTG AT 3'; Human DVL-3, sense: 5' CGC AAG TAT GCC AGC AAC 3', antisense: 5' GCA GAG GTC ACC GAA GAT 3'.

#### *RNA extraction, reverse transcription and quantitative real-time PCR (qRT-PCR)*

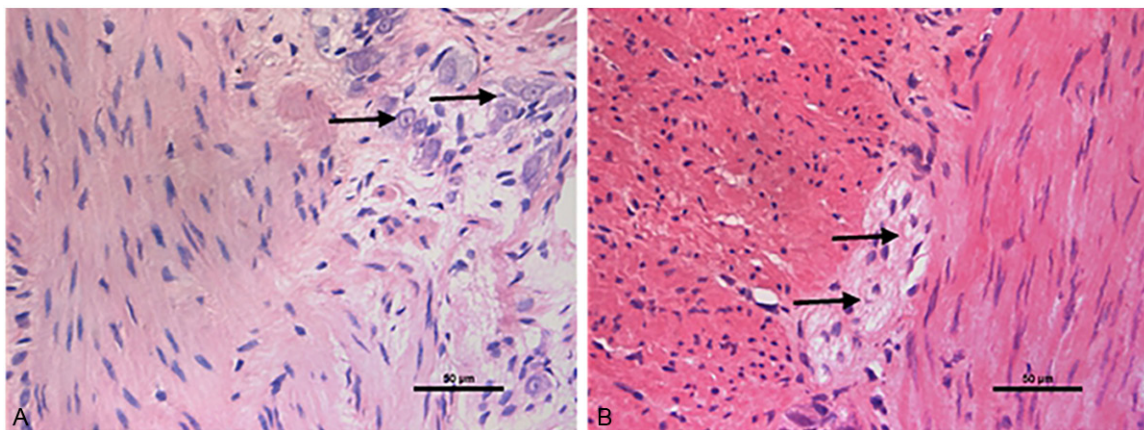
Approximate 100 mg tissues from the aganglionic and ganglionic intestines were used for total RNA extraction using RNA extraction reagent TRIZOL (Invitrogen Life Technologies), according to manufacturer's instructions. The harvested RNA was diluted to a concentration of  $1\ \mu\text{g}/\mu\text{l}$ , aliquoted and stored at  $-80^{\circ}\text{C}$  temperature. For cDNA synthesis, two reagent kits were used (One Step PrimeScript® mRNA cDNA Synthesis Kit, PrimeScript® RT reagent Kit, Takara Biotechnology Co.).

The qRT-PCR was performed with a 12.5  $\mu\text{l}$  reaction system in triplicate for each specimen in the presence of SYBR green PCR Master mix (Takara Biotechnology Co.) in a Lightcycler (Roche Molecular Biochemicals, Co.). The housekeeping gene  $\beta$ -actin (Takara, DR3783) was used as an endogenous control. The reaction program was: 5 min pre-denaturation at  $95^{\circ}\text{C}$  and 40 cycles of 5 s of denaturation at  $95^{\circ}\text{C}$ , 30 s of annealing at  $55^{\circ}\text{C}$  (for DVL-1) or  $53^{\circ}\text{C}$  (for DVL-3). After the termination of PCR, the production was analyzed by the Lightcycler system automatically. The amplification process was followed by a melting curve analysis and CT value was recorded. The average CT value was the extreme CT value of the sample. For these genes, one cycle change in CT corresponded to a  $2.1 \pm 0.2$  (SEM) change in RNA dilution. The expression difference of the gene was calculated by the  $2^{-\Delta\Delta\text{Ct}}$  method [16].

#### *Hematoxylin and eosin staining and immunohistochemical staining*

Diagnosis of HSCR was based on hematoxylin and eosin (H&E) staining of ganglion cells. It is

## Expression of DVL in HSCR



**Figure 1.** Photomicrographs of aganglionic and ganglionic intestine by H&E. A: Ganglionic colon segment tissue (the arrow shows the ganglionic cells). B: Aganglionic colon segment tissue (the arrow shows fibrous tissue of hyperplasia where the ganglionic cell disappears). A and B:  $\times 400$  (the bar = 50  $\mu\text{m}$ ).

confirmed by the review of surgical pathological reports from resections following each biopsy diagnosis of HSCR whether the diagnosis was correct or not. Aganglionic segment and ganglionic segment were obtained according to H&E staining (**Figure 1**). And the segments were fixed in 10% neutral-formalin and embedded in paraffin.

Immunohistochemistry (IHC) was performed on 5  $\mu\text{m}$  sections obtained from formalin-fixed, paraffin embedded blocks using Biotin streptavidin complex method. Tissue sections were deparaffinized in xylene (3 times, 20 minutes each) and gradually rehydrated with ethanol (100%, 90%, 80%, 70%) and distilled water (2 minutes). Washing was then performed by PBS for 5 minutes. After blocking endogenous peroxidase by the treatment of hydrogen peroxide (3%  $\text{H}_2\text{O}_2$ , for 15 minutes), the sections were incubated at 100°C for 10 minutes in 0.01 mol/L citrate buffer (pH = 6) as an antigen retrieval step. After washing with PBS (5 minutes) the sections were incubated with 10% normal goat serum for 30 minutes. The sections were subsequently incubated with primary anti-DVL-1 (1:3000 dilution, Polyclonal rabbit anti-DVL-1, Sigma-Aldrich® Co. Catalog Number D3570) and DVL-3 (1:3000 dilution, Polyclonal rabbit anti-DVL-3, BioVision Incorporated, Catalog Number 3684R-100) overnight at 4°C. The sections were then washed in PBS and incubated with anti-rabbit IgG-peroxidase antibody for 20 minutes at 37°C, washed by PBS. The final reaction product was stained with diaminobenzidine (DAB). After 10 minutes

washing with PBS, nuclei were counterstained with Hematoxylin. The negative control was performed by equivalent PBS instead of rabbit anti-DVL-1 or DVL-3. Brown and yellow deposition represented a positive reaction. Density and distribution were observed under a light microscope. The density of the positively stained area was calculated at  $\times 400$  magnification as the sum of the areas occupied by the positively stained area of the tissues. Images were taken and the area of staining in each image was calculated by a NISE Elements Basic Research (version 2.30, Kawasaki, Kanagawa, Japan) analysis system. The immunohistochemical stained slides were independently reviewed by two pathological researchers.

### Western blot

Approximate 50 mg colon tissue specimen was minced to small pieces using surgical scissors and sonicated in protein lysis buffer, followed by centrifugation (13,000 rpm) for 15 minutes at 4°C. The protein concentration was measured by the Bradford method, and specimens were adjusted to the same protein concentration, aliquoted and stored at -80°C. Samples containing equal amounts of protein (50  $\mu\text{g}$ ) were separated by sodium-dodecyl sulfate polyacrylamide gel electrophoresis (SDS-PAGE) on a 10% gel, and then electro-transferred onto polyvinylidene fluoride (PVDF) membranes (Millipore, Billerica, MA, USA). Blots were blocked with 5% skim milk for 1h at 37°C, followed by incubation with the following primary polyclonal antibodies: anti-DVL1 (1:1000,

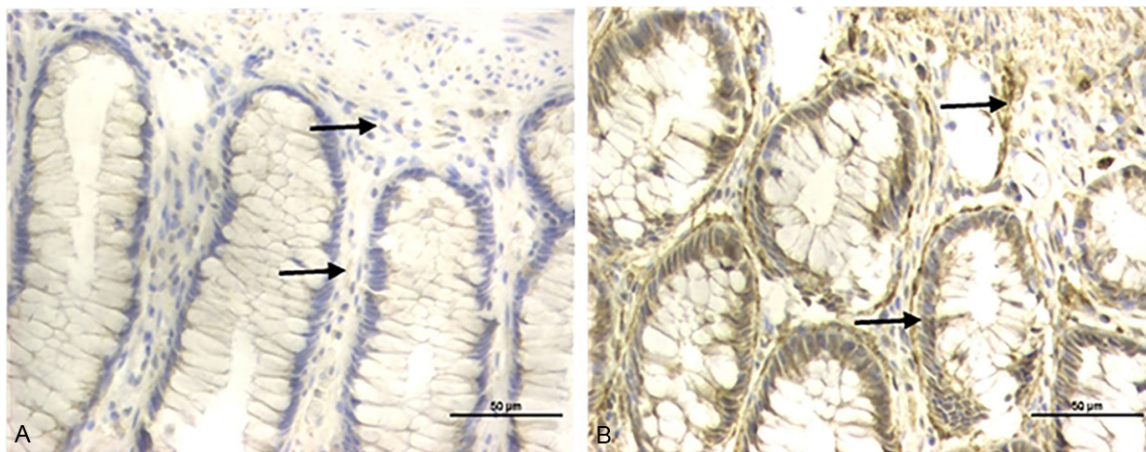
## Expression of DVL in HSCR

**Table 1.** The relative quantity of DVL-1 mRNA in two segments

segment	DVL-1	$\beta$ -actin	$\Delta$ Ct	$\Delta\Delta$ Ct	times of gene (compared to normal segment)
	average Ct value	average Ct value			
normal	24.95 $\pm$ 1.48	23.94 $\pm$ 1.95	1.01	0	1
aganglionic	24.03 $\pm$ 1.38	24.06 $\pm$ 1.80	-0.03	-1.04	2.06

**Table 2.** The relative quantity of DVL-3 mRNA in two segments

segment	DVL-3	$\beta$ -actin	$\Delta$ Ct	$\Delta\Delta$ Ct	times of gene (compared to normal segment)
	average Ct value	average Ct value			
normal	24.13 $\pm$ 1.55	23.94 $\pm$ 1.95	0.19	0	1
aganglionic	22.61 $\pm$ 1.61	24.06 $\pm$ 1.80	-1.45	-1.64	3.12



**Figure 2.** Expression of DVL-1 detected by immunohistochemistry in aganglionic and ganglionic colon segment tissue. The brown yellow depositions in aganglionic segment were far more rich and widespread in submucosa, while those in the ganglionic segment were punctiform. A: Ganglionic colon segment tissue. B: Aganglionic colon segment tissue. A and B:  $\times$  400 (the bar = 50  $\mu$ m).

Sigma-Aldrich biotechnology Co.) and anti-DVL3 (1:1000, BioVision Incorporated.) overnight at 4°C. The following day, the blots were washed, and then incubated with horse anti-rabbit secondary antibody (1:2000 dilution; Maixin Biotechnology, Fuzhou, China) for 90 minutes at 37°C and detected by an enhanced chemiluminescence (ECL, Pierce Biotechnology, Rockford, IL, USA). The grayscale values of the DVL-1 and DVL-3 bands were normalized to the values of the corresponding  $\beta$ -actin band to determine the expression level of the protein. The experiments were repeated 3 times independently.

### Statistical analysis

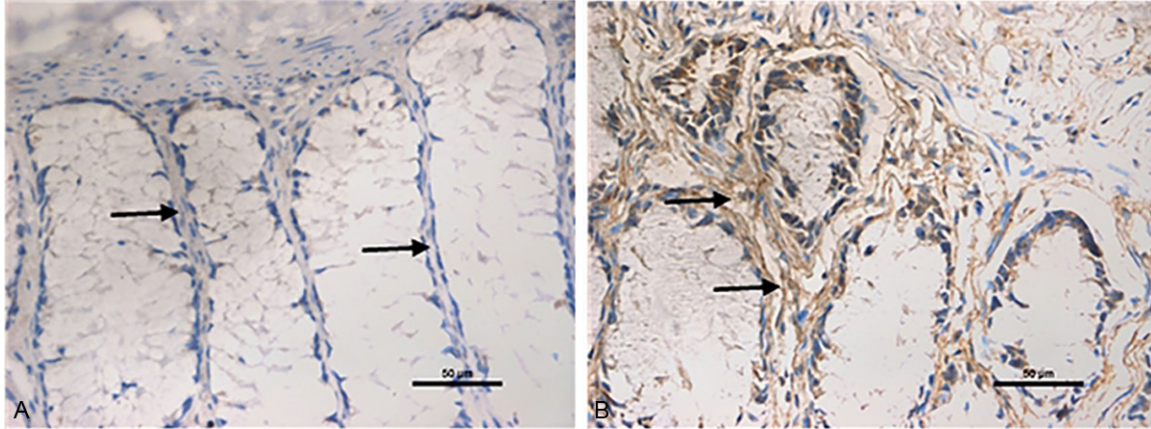
The Statistical Program for Social Sciences, version 13.0 (SPSS, Chicago, IL), was used for statistical analysis. A t test was used to com-

pare the expression level of DVL-1 and DVL-3 between aganglionic colon segments and ganglionic colon segments. All results were expressed as means  $\pm$  standard deviation (S.D.), where *P* values less than 0.05 were considered statistically significant.

## Results

### qRT-PCR analysis

The OD value of RNA calculated by A260/A280 was from 1.8 to 2.0. In the course of the qRT-PCR, the amplification curve was received by fluorescent threshold and cycle, a fair reproducibility of each sample and basically coincident efficacy amplification were demonstrable. It was showed that the mRNA levels of DVL-1 and DVL-3 were 2.06 fold and 3.12 fold higher in aganglionic colon segment tissues than those



**Figure 3.** Expression of DVL-3 detected by immunohistochemistry in aganglionic and ganglionic colon segment tissue. The brown yellow depositions in aganglionic segment were widespread and reticulodromous in submucosa, while those in the ganglionic segment were rather light. A: Ganglionic colon segment tissue. B: aganglionic colon segment tissue. A and B:  $\times 400$  (the bar =  $50 \mu\text{m}$ ).

**Table 3.** The distribution of DVL-1 and DVL-3 in two segments (percentage of staining area to whole area %, means  $\pm$  SD)

Content	Aganglionic segment	Normal segment
DVL-1	$0.2659 \pm 0.0065^*$	$0.0461 \pm 0.0067$
DVL-3	$0.2551 \pm 0.0103^*$	$0.0381 \pm 0.0082$

\*:  $P < 0.05$  vs normal segment.

in ganglionic colon segment tissues by the qRT-PCR ( $n = 50$ ,  $P < 0.03$ ;  $n = 50$ ,  $P < 0.03$ ), respectively (**Tables 1** and **2**).

#### Immunohistochemical staining results

The aganglionic and ganglionic colon segments were first defined by the absence of the focal colon ganglion cells through H&E staining (**Figure 1**). The positive reaction mainly located in the mucous layer and submucous layer of colon segment. The brown yellow depositions in the aganglionic colon segment tissues were far more rich and widespread in submucosa, and were reticulodromous in the circular muscular layer; while those in the ganglionic colon segment tissues were punctiform. DVL-1 and DVL-3 immunoreactivity showed the tendency of regional increase from ganglionic colon segment to aganglionic colon segment (**Figures 2** and **3**) with significant deviation (**Table 3**). Besides, immunohistochemical staining was also found that fibrous tissue of hyperplasia between the inner circular and outer longitudinal muscle layer in the aganglionic colon segment could be stained dark yellow by DVL-3,

while the plexus wasn't colored in the ganglionic colon segment (**Figure 4**).

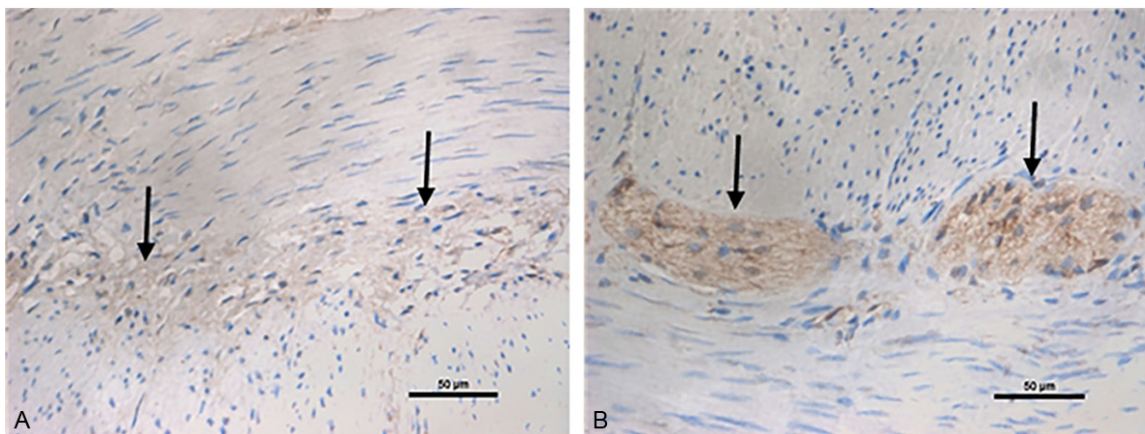
#### Western blot analysis

The expressions of DVL-1 and DVL-3 proteins were evaluated by western blotting with specific antibodies in the same group of 50 HSCR patients. Consistent with the results of qRT-PCR, significant increases of DVL-1 and DVL-3 were detected in aganglionic colon segments compared to the matched ganglionic colon segments (**Figure 5**). The protein levels of DVL-1 and DVL-3 were  $39.71 \pm 4.53$  and  $53.90 \pm 6.79$  in the aganglionic colon segment, respectively, whose values were much higher than those measured in the ganglionic colon segment ( $15.01 \pm 2.66$  and  $20.13 \pm 3.63$ , respectively,  $P < 0.05$ ).

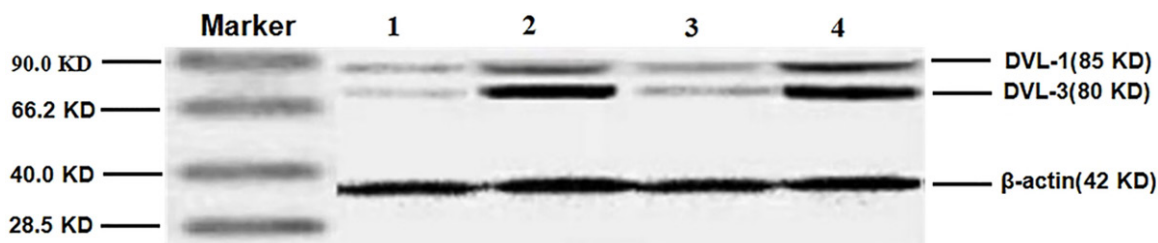
#### Discussion

HSCR disease is the most common congenital gut motility disorder, occurs in 1:5,000 live births and is characterized by an absence of enteric neurons in terminal regions of the gut [2], leading to tonic contraction of the affected segment, intestinal obstruction and massive distension of the proximal bowel (megacolon). As we all know that the onset of HSCR is closely related with the maldevelopment of the ENS and involves a series of complicated process including the distortion of ganglion cell development at different stages [17, 18]. By far, many genes are reported to be involved in the etiology of HSCR. The mechanism of motility

## Expression of DVL in HSCR



**Figure 4.** Fibrous tissue of hyperplasia in the aganglionic segment was stained dark yellow by DVL-3, while the plexus wasn't colored in the ganglionic segment. A: Ganglionic colon segment tissue. B: Aganglionic colon segment tissue. A and B:  $\times 400$  (the bar = 50  $\mu\text{m}$ ).



**Figure 5.** The expression of DVL-1 and DVL-3 proteins. Lines 1 and 3: the DVL-1 and DVL-3 proteins of the ganglionic segment. Lines 2 and 4: the DVL-1 and DVL-3 proteins of the aganglionic segment.

dysfunction in HSCR is still unclear although colonic motility dysfunction is a main manifestation. Despite certain achievements have been made in identifying some of the genetic basis of HSCR disease, the cause of HSCR remains unclear.

Furthermore, for HSCR patients, persistent postoperative disturbances in bowel motility even after the operation are one of the major problems, whose underlying pathomechanism remains unclear, too. In this study, we used qRT-PCR, immunohistochemical staining and western blot based molecular biology study to investigate the differential expressions in mRNA and protein levels between the aganglionic and ganglionic of colon tissues from HSCR patients in order to get more information about bowel motility disturbance. We analyzed the aganglionic and ganglionic colon segment tissues derived from 50 patients with sporadic HSCR and found that both the expressions of DVL-1 and DVL-3 in aganglionic colon segments

were higher than those in ganglionic colon segments (**Tables 1 and 2**), and the differences were statistically significant ( $P < 0.03$ ). The same protein expression results were further confirmed that significant increase of DVL-1 and DVL-3 were detected in aganglionic colon segments compared to the ganglionic colon segments.

The diagnosis of HSCR remains a challenge for both the clinician and the pathologist. The most important question is how best to make a differential diagnosis between HSCR and other similar diseases such as intestinal neuronal dysplasia B (IND B). For histologic diagnosis of HSCR, it is necessary to see the ganglion cells by serial sections in formalin-fixed tissue and use frozen section for acetylcholine esterase enzyme histochemistry [19]. However, difficulties often arise in situations, such as identifying ganglion cells with confidence, especially in neonates. Several methods were used in the past years to identify ganglion cells, but few of

them could become a suitable marker for the diagnosis of the HSCR. For HSCR patients, the normal plexus was replaced by the fibrous tissue of hyperplasia in the aganglionic segment where the ganglionic cells disappeared. In the study, we found that fibrous tissue of hyperplasia between the inner circular and outer longitudinal muscle layer in the aganglionic segment could be stained dark yellow by DVL-3, while the plexus wasn't colored in the ganglionic segment (**Figure 4**), which may provide some help for the diagnosis of HSCR.

For the possible reasons about the higher expression levels of DVL-1 and DVL-3 in the aganglionic tissues compared with the ganglionic tissues, we postulate that aberrant Wnt signalling may contribute to neurological disorders resulting to the higher expressions of DVL-1 and DVL-3. As a mediating factor, more DVL-1 and DVL-3 may stimulate synapse formation by increasing synaptic assembly to promote the normal development of the aganglionosis.

There are also some mechanisms about DVL that need further studying. The exact mechanism that how the over expressions of DVL-1 and DVL-3 genes affect the development of HSCR needs further research. All in all, In this article, our study shows that DVL-1 and DVL-3 are differentially expressed in mRNA and protein levels between the aganglionic colon segments and the ganglionic colon segments, suggesting that DVL-1 and DVL-3 may be a cause of the HSCR patients. The change of mRNA and protein on DVL-1 and DVL-3 in the aganglionic colon segments and the ganglionic colon segments might provide more resources for further investigation of the molecular basis in HSCR.

### Acknowledgements

This work was supported by grants from the National Natural Science Foundation of China (grant#: 30772277).

### Disclosure of conflict of interest

None.

**Address correspondence to:** Dr. Hong Gao, Key Laboratory of Pediatric Congenital Malformations, Ministry of Public Health, Shengjing Hospital of China Medical University, Shenyang, Liaoning, China. E-mail: gaoh@sj-hospital.org

### References

- [1] Pan ZW and Li JC. Advances in molecular genetics of Hirschsprung's disease. *Anat Rec* 2012; 295: 1628-1638.
- [2] Emison ES, McCallion AS, Kashuk CS, Bush RT, Grice E, Lin S, Portnoy ME, Cutler DJ, Green ED, Chakravarti A. A common sex-dependent mutation in a RET enhancer underlies Hirschsprung disease risk. *Nature* 2005; 434: 857-863.
- [3] Luo Y, Ceccherini I, Pasini B, Matera I, Bicocchi MP, Barone V, Bocciardi R, Kääriäinen H, Weber D and Devoto M. Close linkage with the RET protooncogene and boundaries of deletion mutations in autosomal dominant Hirschsprung disease. *Hum Mol Genet* 1993; 2: 1803-1808.
- [4] Angrist M, Bolk S, Halushka M, Lapchak PA and Chakravarti A. Germline mutations in glial cell line-derived neurotrophic factor (GDNF) and RET in a Hirschsprung disease patient. *Nat Genet* 1996; 14: 341-344.
- [5] Sánchez-Mejías A, Fernández RM, López-Alonso M, Antiñolo G, Borrego S. New roles of EDNRB and EDN3 in the pathogenesis of Hirschsprung disease. *Genet Med* 2010; 12: 39-43.
- [6] Pan ZW, Lou J, Luo C, Yu LJ and Li JC. Association analysis of the SOX10 polymorphism with Hirschsprung disease in the Han Chinese population. *J Pediatr Surg* 2011; 46: 1930-1934.
- [7] Martin BL, Kimelman D. Canonical Wnt signaling dynamically controls multiple stem cell fate decisions during vertebrate body formation. *Dev Cell* 2012; 22: 223-232.
- [8] Gurney A, Axelrod F, Bond CJ, Cain J, Chartier C, Donigan L, Fischer M, Chaudhari A, Ji M, Kapoun AM, Lam A, Lazetic S, Ma S, Mitra S, Park IK, Pickell K, Sato A, Satyal S, Stroud M, Tran H, Yen WC, Lewicki J, Hoey T. Wnt pathway inhibition via the targeting of Frizzled receptors results in decreased growth and tumorigenicity of human tumors. *Proc Natl Acad Sci U S A* 2012; 109: 11717-11722.
- [9] Gao H, Zhang ZB, Jiang ZJ, Wang DJ, Huang Y and Wang WL. Mutation and expression of WNT8b gene and SHH gene in Hirschsprung disease. *Zhonghua Wei Chang Wai Ke Za Zhi* 2010; 13: 758-761.
- [10] Almuedo-Castillo M, Saló E, Adell T. Dishevelled is essential for neural connectivity and planar cell polarity in planarians. *Proc Natl Acad Sci U S A* 2011; 108: 2813-2818.
- [11] Zhang X, Zhu J, Yang GY, Wang QJ, Qian L, Chen YM, Chen F, Tao Y, Hu HS, Wang T and Luo ZG. Dishevelled promotes axon differentiation by regulating atypical protein kinase C. *Nat Cell Biol* 2007; 9: 743-754.

## Expression of DVL in HSCR

- [12] Pulvirenti T, Van Der Heijden M, Droms LA, Huse JT, Tabar V, Hall A. Dishevelled 2 Signaling Promotes Self-Renewal and Tumorigenicity in Human Gliomas. *Cancer Res* 2011; 71: 7280-7290.
- [13] Cao C and Chen YG. Dishevelled: The hub of Wnt signaling. *Cell Signal* 2010; 22: 717-727.
- [14] Long J, LaPorte M, Paylor PR and Wynshaw-Boris A. Expanded characterization of the social interaction abnormalities in mice lacking Dvl1. *Genes Brain Behav* 2004; 3: 51-62.
- [15] Tsang M, Lijam N, Yang Y, Beier DR, Wynshaw-Boris A and Sussman DJ. Isolation and characterization of mouse dishevelled-3. *Dev Dyn* 1996; 207: 253-262.
- [16] Livak KJ and Schmittgen TD. Analysis of relative gene expression data using real-time quantitative PCR and the  $2^{-\Delta\Delta Ct}$  method. *Methods* 2001; 25: 402-408.
- [17] Heanue TA, Pachnis V. Enteric nervous system development and Hirschsprung's disease: advances in genetic and stem cell studies. *Nat Rev Neurosci* 2007; 8: 466-479.
- [18] Martucciello G. Hirschsprung's disease, one of the most difficult diagnoses in pediatric surgery: a review of the problems from clinical practice to the bench. *Eur J Pediatr Surg* 2008; 18: 140-149.
- [19] Moore SW and Johnson G. Acetylcholinesterase in Hirschsprung's disease. *Pediatr Surg Int* 2005; 21: 255-263.