

## Original Article

# Effect of pulsed and continuous therapeutic ultrasound on healthy skeletal muscle in rats

Bélgica Vásquez<sup>1</sup>, Javiera Navarrete<sup>2</sup>, Emilio Farfán<sup>3</sup>, Mario Cantín<sup>4,5</sup>

<sup>1</sup>Universidad de Tarapacá, Arica, Chile; <sup>2</sup>Master Program in Morphological Science, Faculty of Medicine, Universidad de La Frontera, Temuco, Chile; <sup>3</sup>Department of Anatomy, Medicine School, Pontificia Universidad Católica de Chile, Santiago, Chile; <sup>4</sup>CIMA Research Group, Faculty of Dentistry, Doctoral Program in Morphological Science, Universidad de La Frontera, Temuco, Chile; <sup>5</sup>Center of Research in Biomedical Sciences, Universidad Autónoma de Chile, Temuco, Chile

Received December 12, 2013; Accepted December 31, 2013; Epub January 15, 2014; Published February 1, 2014

**Abstract:** Ultrasound therapy is used to treat injuries in joints, nerves and tendons. Part of the radiation generated is absorbed by nearby undamaged tissues, such as muscles. The aim was to evaluate histomorphological changes in the healthy gastrocnemius muscle in rats irradiated with continuous ultrasound (CUS) and pulsed ultrasound (PUS). Healthy adult rats were used, separated into two groups: CUS and PUS. Both were irradiated in the gastrocnemius muscle for 10 days: the CUS group in continuous mode (3 MHz, 1.0 W/cm<sup>2</sup>, 1 min/session) and the PUS group in pulsed mode (3 MHz, 1.0 W/cm<sup>2</sup>, 100 Hz, 50% duty cycle, 1 min/session). The contralateral muscles were used as a control. Their histological characteristics were analyzed, and the area and perimeter of the muscle fibers were measured. The connective tissue showed no histological changes. The area of muscle fibers of the irradiated groups was significantly greater (CUS 1325.2±182.1 μm<sup>2</sup>, p=0.0278 and PUS 1019.4±125.3 μm<sup>2</sup>, p=0.0398) than the control, and the CUS area was greater than the PUS (p=0.0383). The perimeter of muscle fibers showed significant differences between the irradiated groups (CUS 148±11.12 μm, p=0.0178 and PUS 129.3±8.83 μm, p=0.0236) compared to the control, as well as differences between CUS and PUS (p=0.0319). The application of ultrasound on healthy muscle produces hypertrophy of the muscle fibers, greater when continuous mode is used. It is advisable to apply pulsed, focused ultrasound therapies with sound heads sufficient for the tissue or zone to be treated, thereby reducing the risk of altering the adjacent healthy tissue.

**Keywords:** Therapeutic ultrasound, health muscle, muscle tissue, continuous ultrasound, pulsed ultrasound

## Introduction

Ultrasound therapy is used to treat pain and promote the repair of various tissues, mainly in the skeletal muscle system, because it is minimally invasive, safe and low cost [1, 2].

In damaged muscle, it accelerates the repair process [3-5] due to the decrease in the response and number of inflammatory cells [6-8]. In addition, it increases the proliferation and differentiation of muscle cell lines [3, 5], along with the formation of the connective tissue, improving mechanical resistance in the early stages [5]. In the muscle treated with ultrasound, an aligned and more regular disposition of the collagen fibers and myotubes is observed, allowing for increased functionality [5].

At the molecular level, the thermal effects of ultrasound stimulate the production of the heat shock protein HSP70 in the muscle, and promote the formation, maturation and degradation of proteins, as well as the transport and assembly of new proteins. In addition, they produce an increase in FGF-β, which together with the protein HSP70 inhibit the progression of muscle atrophy [9].

In animals, ultrasound therapy improves tensile strength, maximum load [4, 7], elasticity index and rate of muscle growth [7], and in humans, it has been shown to increase extensibility of healthy muscle when applying static stretching combined with ultrasound [10].

Ultrasound can also be used to treat other injured tissues. In carpal tunnel syndrome, it

## Effect of pulsed and continuous ultrasound on healthy skeletal muscle

alleviates pain, increases the grip strength of the fingers and hand, and improves some electrophysiological parameters [11, 12]. On injured nerves, it accelerates regeneration and increases the amount of small-diameter myelinated fibers [13]. In the foot, it facilitates recovery of function, remyelination and regeneration of the damaged axon [14]. It is not known, however, whether the healthy tissue that surrounds these injuries is altered as a result of the ultrasound treatment.

Parra et al. [15] showed that when irradiating healthy muscle in rats with a low-power laser, there is an increase in the diameter of the muscle fibers. According to the authors, this morphological change could be related to the participation of the satellite cells, due to the proliferation, differentiation and subsequent fusion of the cells, which contribute with their nuclei and cytoplasmic mass to the increase in size of the muscle fiber.

The aim of this study was to analyze and compare the effects of pulsed and continuous therapeutic ultrasound on the muscle fibers of the healthy gastrocnemius muscle in rats.

### Materials and methods

Ten healthy adult male Sprague Dawley (*Rattus norvegicus*) were used, weighing between 250-300 g, obtained from the Center of Experimental Surgery at the Universidad de La Frontera, Temuco, Chile. They were separated into two groups of five, kept in their respective cages, with a light/dark regime of 12/12 hours, at a room temperature of  $22\pm 21^{\circ}\text{C}$  and fed with commercial pellet and water *ad libitum* throughout the experiment. The investigation was conducted according to the directives of the Guide for the Care and Use of Laboratory Animals published by the U.S. National Institutes of Health (NIH Publication no. 85-23, <http://grants.nih.gov/grants/olaw/olaw.htm>) [16].

An ultrasound unit (Intelect, Chatanooga Group) with a 5 cm sound head and Sonogel (Chatanooga Group) were used for irradiation. Continuous (CUS) and pulsed (PUS) mode were used. The animals were assigned randomly to form the groups as follows:

**CUS Group:** The right posterior member of each animal was shaved and the zone corresponding to the gastrocnemius muscle was irradiated with ultrasound in continuous mode, using a

frequency of 3 Mhz and a 5 cm sound head for 1 minute with an intensity of  $1\text{ W/cm}^2$ . The sessions were conducted once a day for 10 consecutive days.

**PUS Group:** The same preparation was used as for the previous group, and the zone corresponding to the gastrocnemius muscle was irradiated with ultrasound in pulsed mode, using a frequency of 3 Mhz and a 5 cm sound head for 1 minute with an intensity of  $1\text{ W/cm}^2$  with a pulsed emission of 1:2 (50% Duty cycle). The sessions were conducted once a day for 10 consecutive days.

**Control group:** The control group was the left posterior member of each animal that was not irradiated.

After the therapy, the animals were sacrificed with an overdose of an IP injection of Ketamine-Xylazine. The gastrocnemius muscles of both members were dissected, without separating the muscles of their insertion and origin, fixing them in 10% buffered formalin for 24 h. Cross sections 1 cm in length were taken from the irradiated zone and processed histologically for their inclusion in Paraplast®. Five micrometers thick cuts were obtained and stained with H & E for histological analysis. For the morphometric study, photographs were taken of the cross sections of the muscles in a Carl Zeiss Axioskop 40 microscope with a Canon® Power Shot G6 7.1 MP digital camera and ZoomBrowser EX software. The images were analyzed with AxioVision 4.6.3 software to determine the average of the area and perimeter of 100 muscle fibers in each group.

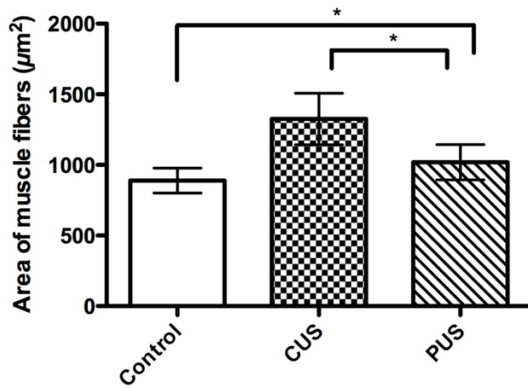
### Statistical analysis

The statistical analysis was done using the ANOVA test and the Bonferroni Post Hoc test through the GraphPad Prism 5.0 software. A 5% ( $p < 0.05$ ) level of significance was considered.

### Results

Histologically in all groups complete muscle fibers were observed, with an eosinophilic coloration, with demarcated cell membranes and several nuclei in an eccentric position. No central nuclei were found in the muscle fibers (young muscle fibers). Nor were there any zones of fibrosis, inflammation or necrosis, or differences in relation to connective tissue density.

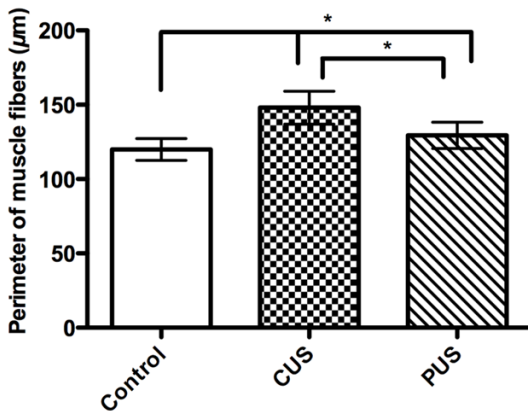
## Effect of pulsed and continuous ultrasound on healthy skeletal muscle



**Figure 1.** Average area of muscle fibers of the healthy gastrocnemius muscle in rats treated with continuous (CUS) and pulsed (PUS) therapeutic ultrasound compared to a control group (ANOVA and Bonferroni,  $*=p<0.05$ ).

**Table 1.** Descriptive statistics of the area of muscle fibers of the healthy gastrocnemius muscle of the control group, the group treated with continuous (CUS) and the group treated with pulsed (PUS) therapeutic ultrasound

Area	Control ( $\mu\text{m}^2$ )	CUS ( $\mu\text{m}^2$ )	PUS ( $\mu\text{m}^2$ )
Average	889.5	1325.3	1019.4
Standard Error	88.68	182.1	125.3
Minimum	656.2	971.2	751.2
Maximum	1127	1778	1262.8



**Figure 2.** Average perimeter of muscle fibers of the healthy gastrocnemius muscle in rats treated with continuous (CUS) and pulsed (PUS) therapeutic ultrasound compared to a control group (ANOVA and Bonferroni,  $*=p<0.05$ ).

In the morphometric analysis, through the ANOVA test it was observed that in the average area of muscle fibers there were differences between the groups. The Bonferroni post hoc

test showed that the average area of the CUS group ( $1325.2\pm182.1 \mu\text{m}^2$ ) and PUS group ( $1019.4\pm125.3 \mu\text{m}^2$ ) were significantly greater ( $p=0.0278$  and  $p=0.0398$ , respectively) than the control group ( $889.5\pm88.68 \mu\text{m}^2$ ). When comparing the average area between the treated groups, CUS was significantly greater ( $p=0.0383$ ) (Figure 1). In addition, the minimum area, maximum area and standard error (SE) were greater in the irradiated groups, with CUS showing the highest values (Table 1).

With respect to the average perimeter of muscle fibers, the analysis of variance showed significant differences between the groups. With the Bonferroni post hoc test, it was observed that the average perimeter of the CUS group ( $148\pm11.12 \mu\text{m}$ ) and PUS group ( $129.3\pm8.83 \mu\text{m}$ ) were significantly greater ( $p=0.0178$  and  $p=0.0236$ , respectively) than the control group ( $119.9\pm7.321 \mu\text{m}$ ) (Figure 2). The minimum value, maximum value and SE were also higher in the irradiated groups, and CUS presented the highest values (Table 2).

In both treated groups, anisocytosis of muscle fibers was observed, with standard error values of the area and perimeter greater than those observed in the control group.

### Discussion

Several investigations have shown that continuous and pulsed low-intensity ultrasound therapy on damaged tissues accelerates the regenerative processes, reduces inflammation and pain, enabling recovery of function [3-8, 12, 13].

In the healthy skeletal muscle tissue of the gastrocnemius muscle, low-intensity ultrasound therapy did not produce any damage or histological alterations to the muscle fibers and connective tissue, nor were any foci of inflammation, fibrosis or necrosis observed. This differs with what was reported by Cowden & Abell [17], who describe that in the muscle irradiated with ultrasound, zones of necrosis, changes in the fibers and loss of the sarcolemma nuclei occurred, and that there were also foci of inflammatory cells and hemorrhage distributed throughout the muscle. These discrepancies could be explained by the type and technological limitations of the equipment, as well as the therapeutic doses and exposure times.

**Table 2.** Descriptive statistics of the perimeter of muscle fibers of the healthy gastrocnemius muscle of the control group, the group treated with continuous (CUS) and the group treated with pulsed (PUS) therapeutic ultrasound

Perimeter	Control ( $\mu\text{m}$ )	CUS ( $\mu\text{m}$ )	PUS ( $\mu\text{m}$ )
Average	119.9	148	129.3
Standard Error	7.321	11.12	8.83
Minimum	101.3	126.1	108.9
Maximum	137.2	180.2	150.5

Additionally, there is little clarity in their work methodology, it does not identify the muscle on which the treatment was applied and the number of analyzed samples is not indicated, preventing an adequate comparison.

In terms of the area and perimeter of the muscle fibers of the healthy gastrocnemius muscle, we observed a significant increase in the CUS and PUS groups compared to the control group, similar to what was described regarding the injured gastrocnemius muscle treated with ultrasound, where an increase in the proliferation and differentiation of the satellite cells was observed [3, 5, 7]. For Rosenblatt et al. [18] and Kawano et al. [19], the activity of the satellite cells is essential for the hypertrophy of muscle fibers in the skeletal muscle, since these cells are incorporated into the muscle fiber, converting their nuclei into myonuclei. This mechanism of satellite cell proliferation and differentiation towards a muscle cell phenotype and their subsequent fusion with the muscle fiber may explain the increase in diameter observed in healthy muscle subjected to ultrasound. Another mechanism that might be involved in the increase in muscle fiber area and perimeter in healthy muscle is the increase in the heat shock protein HSP70, which promotes protein synthesis and repair, as well as the increase in FGF- $\beta$ , which functions as an activator and mediator of the skeletal muscle tissue, both of which are stimulated by ultrasound [9].

An important factor to consider in the results obtained is the mode of ultrasound used, because the CUS group presented significantly higher values than the PUS group. The differences of the effects produced between the different ultrasound modes have also been

observed in other studies. Oliveira et al. [20], using low-intensity ultrasound, observed a significant increase in the relative weight of the heart, liver, kidney and lung in the fetuses of pregnant rats subjected to CUS compared to PUS, and attributed the greater organ growth to a reduction in the apoptosis process in the inner cell mass, enhancing cell growth in some organs. Hundt et al. [21] observed that in rat muscle treated with high-intensity ultrasound, there were devascularized areas and foci of necrosis characterized as presenting condensation and pyknosis of the nuclear chromatin, as well as contraction and hypereosinophilia of the muscle fiber cytoplasm, with these changes being more severe with CUS than PUS. Thus, the observed biological effects could be related to the mechanism of action of the continuous and pulsed mode. CUS causes a temperature increase in tissues and PUS produces cavitation and mechanical effects [22]. In our study, temperature as a mechanism of action had a greater effect on hypertrophy in the muscle fibers.

In addition, in the muscle fibers in the CUS and PUS groups, slight anisocytosis was observed, with non-uniform tissue architecture compared to the control. The area and perimeter measurements showed a greater range between the minimum and maximum values and SE, with the CUS group presenting the highest values. This could be due to the most superficial tissues absorbing a greater amount of ultrasonic energy than the deep tissues, resulting in a non-homogenous response from the tissue.

### Conclusion

In the healthy muscle treated with ultrasound, hypertrophy occurred in the muscle fibers treated in continuous and pulsed mode. PUS with a frequency of 3 Mhz and 1 W/cm<sup>2</sup> with a pulsed emission of 1:2 (50%) produced less muscle alteration than CUS. It is recommended that PUS be used, focused on the treatment zone, applied with controlled intensity and frequency, and with a sound head with the smallest diameter possible in order to reduce changes in the healthy muscle tissues or layers located around or on the injured structure. Therefore, it must be considered that low-intensity ultrasound treatment, in injuries of the nerve tissue, joints, tendons, among others, alters the healthy muscle and possibly other adjacent tissues.

## Disclosure of conflict of interest

None.

**Address correspondence to:** Dr. Mario Cantín, CIMA Research Group, Faculty of Dentistry, Doctoral Program in Morphological Science, Universidad de La Frontera, Avenue Manuel Montt 112, Temuco, Chile. Tel: 056-045-2325574; E-mail: mario.cantin@ufrontera.cl

## References

- [1] Lirani-Galvão AP, Jorgetti V, da Silva OL. Comparative study of how low-level laser therapy and low-intensity pulsed ultrasound affect bone repair in rats. *Photomed Laser Surg* 2006; 24: 735-40.
- [2] Fréz AR, Ariza D, Ferreira JRL, Alves EPB, Breda GR, Centenaro LA, Ueda TK, Bertolini GRF. Effect of continuous therapeutic ultrasound in rabbit growth plates. *Rev Bras Med Esporte* 2006; 12: 150-2.
- [3] Karnes JL, Burton HW. Continuous Therapeutic Ultrasound Accelerates Repair of Contraction-Induced Skeletal Muscle Damage in Rats. *Arch Phys Med Rehabil* 2002; 83: 1-4.
- [4] Matheus JPC, Oliveira FB, Gomide LB, Milani JGP, Volpon JB, Shimano AC. Effects of therapeutic ultrasound on the mechanical properties of skeletal muscles after contusion. *Rev Bras Fisioter* 2008; 12: 241-7.
- [5] Piedade MC, Galhardo MS, Battlehner CN, Ferreira MA, Caldini EG, de Toledo OM. 2008. Effect of ultrasound therapy on the repair of Gastrocnemius muscle injury in rats. *Ultrasonics* 2008; 48: 403-11.
- [6] Rennó AC, Toma RL, Feitosa SM, Fernandes K, Bossini PS, de Oliveira P, Parizotto N, Ribeiro DA. Comparative Effects of Low-Intensity Pulsed Ultrasound and Low-Level Laser Therapy on Injured Skeletal Muscle. *Photomed Laser Surg* 2011; 29: 5-10.
- [7] Shu B, Yang Z, Li X, Zhang LQ. Effect of different intensity pulsed ultrasound on the restoration of rat skeletal muscle contusion. *Cell Biochem Biophys* 2012; 62: 329-36.
- [8] Saturnino-Oliveira J, Tomaz MA, Fonseca TF, Gaban GA, Monteiro-Machado M, Strauch MA, Cons BL, Caili-Elias S, Martinez AM, Melo PA. Pulsed ultrasound therapy accelerates the recovery of skeletal muscle damage induced by Bothrops jararacussu venom. *Braz J Med Biol Res* 2012; 45: 488-96.
- [9] Sakamoto J, Nakano J, Kataoka H, Origuchi T, Yoshimura T, Okita M. Continuous therapeutic ultrasound inhibits progression of disuse atrophy in rat gastrocnemius muscles. *J Phys Ther Sci* 2012; 24: 443-7.
- [10] Wessling KC, DeVane DA, Hylton CR. Effects of static stretch versus static stretch and ultrasound combined on triceps surae muscle extensibility in healthy women. *Phys Ther* 1987; 67: 674-9.
- [11] Ebenbichler GR, Resch KL, Nicolakis P, Wiesinger GF, Uhl F, Ghanem AH, Fialka V. Ultrasound treatment for treating the carpal tunnel syndrome: randomised "sham" controlled trial. *BMJ* 1998; 316: 731-5.
- [12] Bakhtiary AH, Rashidy-Pour A. Ultrasound and laser therapy in the treatment of carpal tunnel syndrome. *Aust J Physiother* 2004; 50: 147-51.
- [13] Raso VV, Barbieri CH, Mazzer N, Fasan VS. Can therapeutic ultrasound influence the regeneration of peripheral nerves? *J Neurosci Methods* 2005; 142: 185-92.
- [14] Mourad PD, Lazar DA, Curra FP, Mohr BC, Andrus KC, Avellino AM, McNutt LD, Crum LA, Kliot M. Ultrasound accelerates functional recovery after peripheral nerve damage. *Neurosurgery* 2001; 48: 1136-1.
- [15] Parra LR, Matamala VF, Silva MH. Morphological effect of AsGa laser irradiation on rat skeletal muscle. *Int J Morphol* 2007; 25: 43-50.
- [16] Acuña L, Suazo GI, Zavando D, Elgueta S, Velásquez L, Vilos C, Cantín M. Morphometric and histopathologic changes in skeletal muscle induced for injectable PLGA microparticles. *Int J Morphol* 2011; 29: 403-8.
- [17] Cowden JW, Abell MR. Some effects of ultrasonic radiation on normal tissues. *Exp Mol Pathol* 1963; 2: 367-83.
- [18] Rosenblatt JD, Yong D, Parry DJ. Satellite cell activity is required for hypertrophy of overloaded adult rat muscle. *Muscle Nerve* 1994; 17: 608-13.
- [19] Kawano F, Takeno Y, Nakai N, Higo Y, Terada M, Ohira T, Nonaka I, Ohira Y. Essential role of satellite cells in the growth of rat soleus muscle fibers. *Am J Physiol Cell Physiol* 2008; 295: C458-67.
- [20] Oliveira RP, Elias MAF, Bellei PM, Silveira SMC, Peters VM, Guerra MO. Efeito do ultra-som terapêutico em ratas prenhes. *Rev Bras Ginecol Obstet* 2008; 30: 335-40.
- [21] Hundt W, Yuh EL, Steinbach S, Bednarski MD, Guccione S. Comparison of continuous vs. pulsed focused ultrasound in treated muscle tissue as evaluated by magnetic resonance imaging, histological analysis, and microarray analysis. *Eur Radiol* 2008; 18: 993-1004.
- [22] ter Haar G. Therapeutic applications of ultrasound. *Prog Biophys Mol Biol* 2007; 93: 111-29.